J Ankara Univ Fac Med 2026;79(3):355-362
DOI: 10.65092/autfm.2024363
Research Article / Araştırma Makalesi

Upper Extremity Glomus Tumors: A Two-Decade Clinicopathologic Analysis of 56 Patients

Üst Ekstremite Glomus Tümörleri: 56 Hastanın Yirmi Yıllık Klinik ve Patolojik Analizi

Servet Elçin Alpat[1*], Fatih Öztemur[1], Bilge Ayça Kırmızı[2], Seher Yüksel[2], Savaş Serel[1]

[1]Ankara University Faculty of Medicine, Department of Plastic, Reconstructive and Aesthetic Surgery, Ankara, Türkiye
[2]Ankara University Faculty of Medicine, Department of Medical Pathology, Ankara, Türkiye

ABSTRACT

Objectives: To define the clinicopathologic spectrum of histologically confirmed glomus tumors of the upper extremity over a 20-year archival period, and to compare digital and extradigital lesions.

Materials and Methods: The pathology archive of a single tertiary university hospital was searched for the term "glomus" for the period 2005–2025. Adults aged 18 years or older with a histopathologic diagnosis of solid glomus tumor at a documented upper-extremity site were included. Glomuvenous malformation, head and neck paragangliomas, lower-extremity, truncal, and visceral lesions, and re-excision material were excluded. Records whose anatomic site was not stated in the pathology report were verified against hospital discharge summaries, which were also reviewed for clinical, radiologic, and operative variables. Digital and extradigital groups were compared using Fisher's exact test and the Mann–Whitney U test.

Results: Fifty-six patients were included. The derived mean age at diagnosis was 45.9 ± 12.7 years and 43 patients (76.8%) were women. Forty-five tumors (80.4%) were digital and 11 (19.6%) were extradigital. Women accounted for 38 of 45 digital tumors(84.4%), compared with 5 of 11 extradigital tumors (45.5%) (p = 0.013; odds ratio 6.51). Women were diagnosed at a younger age than men (median 42 versus 59 years; p = 0.002). Where symptom duration was recorded (n = 15), the median was 66 months. Five patients had been given an alternative preoperative diagnosis. None of the included tumors were malignant.

Conclusion: Upper-extremity glomus tumors were predominantly digital and occurred mainly in females, but extradigital disease showed a balanced sex distribution and was frequently misdiagnosed. Diagnostic delay continued to be measured in years.

Keywords: Glomus tumor; hand; upper extremity; subungual; delayed diagnosis

ÖZET

Amaç: Yirmi yıllık arşiv döneminde histopatolojik olarak doğrulanmış üst ekstremite yerleşimli glomus tümörlerinin klinikopatolojik özelliklerini tanımlamak ve dijital ile ekstradijital lezyonları karşılaştırmak.

Gereç ve Yöntem: Tek merkezli üçüncü basamak bir üniversite hastanesinin patoloji arşivi 2005–2025 dönemi için "glomus" terimiyle tarandı. On sekiz yaş ve üzerinde, histopatolojik olarak solid glomus tümörü tanısı almış ve üst ekstremite yerleşimi belgelenmiş hastalar dahil edildi. Glomuvenöz malformasyon, baş-boyun paragangliomları, alt ekstremite, gövde ve viseral yerleşimli lezyonlar ile reeksizyon materyalleri dışlandı. Patoloji raporunda anatomik yerleşimi belirtilmeyen kayıtlar hastane epikrizleri ile değerlendirildi; epikrizler ayrıca klinik, radyolojik ve cerrahi değişkenler açısından tarandı. Dijital ve ekstradijital gruplar Fisher Exact test ve Mann-Whitney U testi ile karşılaştırıldı.

Bulgular: Elli altı hasta dahil edildi. Hesaplanan ortalama tanı yaşı 45,9 ± 12,7 yıl olup 43 hasta (%76,8) kadındı. Tümörlerin 45'i (%80,4) dijital, 11'i (%19,6) ekstradijitaldi. Dijital tümörlerin 38/45'i (%84,4), ekstradijital tümörlerin 5/11'i (%45,5) kadınlarda görüldü (p = 0,013; olasılık oranı 6,51). Kadınlar erkeklerden daha genç yaşta tanı aldı (medyan 42'ye karşı 59 yıl; p = 0,002). Semptom süresinin kayıtlı olduğu hastalarda (n=15) medyan süre 66 aydı. Beş hastaya ameliyat öncesinde farklı bir tanı konulmuştu. Dahil edilen hiçbir tümör malign değildi.

Sonuç: Üst ekstremite glomus tümörleri ağırlıklı olarak dijital ve kadın hastalarda görüldü; ancak ekstradijital hastalıkta cinsiyet dağılımı dengeliydi ve yanlış tanı sıktı. Tanısal gecikme yıllarla ölçülmeye devam etmektedir.

Anahtar Kelimeler: Glomus tümörü; el; üst ekstremite; tırnak yatağı; gecikmiş tanı

Corresponding author: Servet Elçin Alpat
Ankara University Faculty of Medicine, Department of Plastic, Reconstructive and Aesthetic Surgery, 06100 Sıhhiye, Ankara, Türkiye
E-mail: sealpat@ankara.edu.tr **ORCID ID:** 0000-0002-3563-3639
Received: 24.08.2026 **Accepted:** 27.08.2026 **Publication Date:** 30.09.2026
Cite this article as: Alpat, S. E., Öztemur, F., Kırmızı, B. A., Yüksel, S., Serel, S. Upper Extremity Glomus Tumors: A Two-Decade Clinicopathologic Analysis of 56 Patients. *J Ankara Univ Fac Med*. 2026;79(3):355-362.

Copyright© 2025 The Author. Published by Ankara University Press on behalf of Ankara University Faculty of Medicine .
This is an open access article under the Creative Commons AttributionNonCommercial 4.0 International (CC BY-NC 4.0) License.

INTRODUCTION

Glomus tumors are uncommon perivascular neoplasms composed of modified smooth-muscle cells that recapitulate the neuromyoarterial glomus body, a specialized arteriovenous shunt involved in thermoregulation (1,2). They typically present as a small, exquisitely painful lesion of the distal digit, classically located beneath the nail plate, and are characterized by the triad of paroxysmal pain, focal-point tenderness, and cold hypersensitivity. In practice the triad is frequently incomplete, the lesion is often impalpable, and diagnosis may be delayed for years, particularly when the tumor lies outside the nail unit or the digits(3-6).Recent reports record diagnostic delays as extreme as 40 years, indicating that this remains a live problem in the 2020s(7).

Published experience clusters heavily in the hand and consistently describes female predominance, frequent subungual localization and excellent symptom relief after complete excision (1,6,8). Magnetic resonance imaging and high-resolution ultrasonography help when clinical findings are equivocal and surgical exposure is chosen by topography, with transungual, lateral and subperiosteal approaches balancing visualization against preservation of the nail matrix(8-13).

Extradigital glomus tumors form a distinct and clinically important subgroup. Schiefer et al.(4) showed that these lesions arise at many sites and are frequently misdiagnosed despite persistent pain and focal tenderness. In the upper limb, they may involve the palm, wrist, forearm, elbow, or arm. Hufschmidt et al. (3), in a dedicated upper-limb series, reported that 77.4% of tumors were digital, with a mean age of 54.6 years. Whether digital and extradigital lesions differ demographically, and not only in site, has attracted little dedicated study, although this is beginning to change: Marcoval et al. documented a near-equal overall sex distribution across 143 patients with the female excess confined to digital disease ($p<0.001$), and Lee et al. reported an equal sex distribution in 31 cases, which they attributed to the inclusion of extradigital tumors (14,15).

A further, often-neglected issue is diagnostic heterogeneity. Contemporary classifications separate the solid glomus tumor from glomuvenous malformation and glomangiomyoma, and separate all of these from malignant glomus tumor (2,16). Glomuvenous malformations are frequently multiple, often inherited, and characteristically less painful than solitary solid tumors; pooling them with solid tumors obscures the precise phenotype that a hand-surgical series seeks to describe. Most published series do not make this distinction explicit.

This study was designed using a protocol limited to adult upper-extremity glomus tumors diagnosed between 2005 and 2025. The primary objective was to describe the demographic, clinical, operative, and pathologic characteristics of histologically confirmed solid glomus tumors of the upper limb; the secondary objective was to compare digital and extradigital lesions, with particular attention to age, sex, and diagnostic delay.

MATERIALS AND METHODS

Study design, case identification, and eligibility

This retrospective, single-center observational study was conducted in the Departments of Plastic, Reconstructive and Aesthetic Surgery and Medical Pathology at a tertiary academic medical center. The departmental pathology information system was searched for “glomus” in final diagnoses issued between 2005 and 2025, yielding 101 report lines corresponding to 87 unique accession-patient combinations.

Patients were eligible if they were aged 18 years or older at diagnosis, had a histopathologic diagnosis of a solid glomus tumor, and had a documented upper-extremity site. Prespecified exclusion criteria included lower-extremity, truncal, or visceral lesions; head and neck paragangliomas, which may be retrieved by such a search because the terms glomus caroticum and glomus jugulare remain in use; glomuvenous malformation; re-excision or recurrent lesions, to ensure that each patient contributed a single incident tumor; and records in which an upper-extremity site

could not be established even after chart review. Reporting followed the STROBE recommendations.

Two-stage anatomic verification

Records were first screened against the final pathologic diagnosis. Where the text did not state an upper-extremity site, or stated only "nail bed" without specifying whether hand or foot, the hospital discharge summary was retrieved and reviewed. Summaries were also retrieved for each patient enrolled in the cohort to extract the clinical and operative variables specified by the protocol. This second stage reclassified two lesions that had been coded only as "hand" or "left hand" to specific digits, corrected the recorded digit or side in two further patients, identified four additional eligible patients whose pathology text had been uninformative, and confirmed the exclusion of thirteen further records, nine of which proved to be carotid body or jugulotympanic paragangliomas. Where the pathology report and the operative record disagreed, the treating surgeon resolved the discrepancy by reference to the source chart.

Variables

A structured data collection form captured demographic, clinical, radiologic, operative and pathologic variables. Anatomic sites were standardized as digits, palms, hands, wrists, forearms, or arms. Tumors explicitly involving a finger, thumb or distal phalanx were classified as digital and all other confirmed upper-limb sites as extradigital, a binary that mirrors the grouping used in recent comparative series (15). Lesions described as involving the nail, nail bed or subungual region were classified as nail-related, following the topographic framework of Civan et al., which links nail-bed position to choice of approach (13). Because pathology reports did not reliably record nail-bed substructure, finer zoning was not attempted; this category should be read as a nail-unit designation rather than a zonal map. Margin status was derived only from explicit margin wording and was otherwise coded as not reported.

Statistical analysis

Continuous variables are summarized as mean ± standard deviation and median (range), categorical variables as counts and percentages. Because of small cell counts and non-normal distributions, digital and extradigital groups were compared with Fisher's exact test and the two-sided Mann-Whitney U test; the sex-site effect size was expressed as an odds ratio. A two-sided p-value below 0.05 was considered significant. Undocumented variables were treated as missing and not imputed or counted as absent.

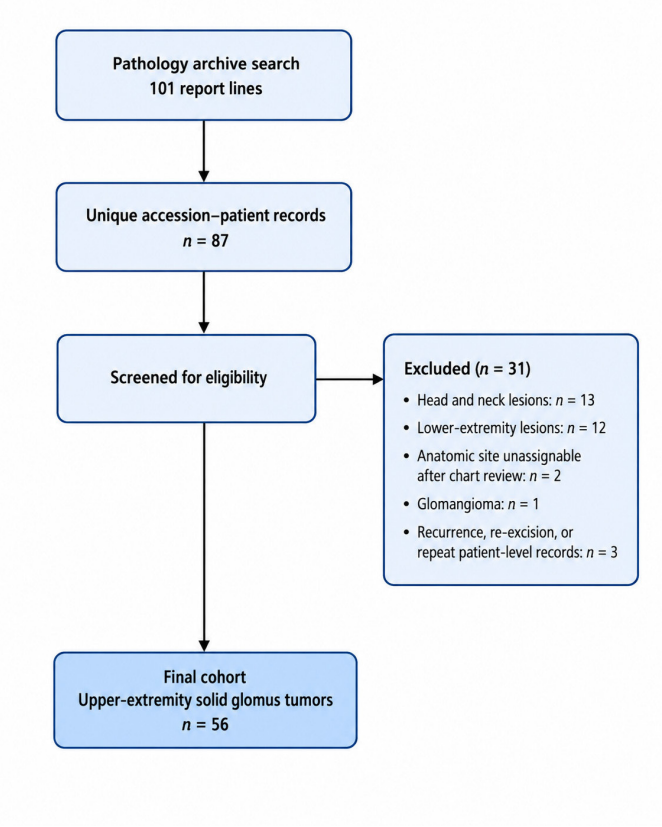

Figure 1. Study flow diagram. An archival search yielded 101 report lines representing 87 unique records. After 31 exclusions, the final cohort comprised 56 patients.

RESULTS

Cohort assembly and demography

Of the 87 unique archival records, 31 were excluded: 13 head and neck lesions (12 paragangliomas of the carotid body, jugulotympanic region or cervical arteries, and one glomus tumor of the neck skin); 12 lower-extremity lesions; two unassignable to any site, even after chart review; one glomangioma; and three recurrences, re-excision or repeat patient-level records. The final cohort comprised 56 patients, with accession years spanning 2007–2025 (Figure 1).

The derived mean age at diagnosis was 45.9±12.7 years (median 46, range 25-80); the corresponding mean age at data extraction was 55.1±13.7 years. Forty-three patients (76.8%) were women and 13 (23.2%) were men. Women were substantially younger at diagnosis than men (42.8±11.2 versus 56.2±12.3 years; median 42 versus 59; p=0.002). The left and right sides were equally represented, with 27 lesions each (48.2%); laterality was unstated in two cases (3.6%) (Supplementary Table S1).

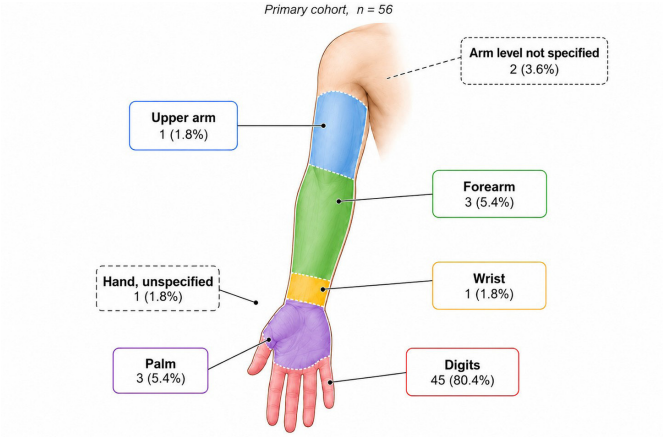

Figure 2. Regional distribution of upper-extremity glomus tumors in the primary cohort (n = 56). Digital tumors predominated (n = 45), followed by palm (n = 3), forearm (n = 3), arm level not specified (n = 2), wrist (n = 1), upper arm (n = 1), and hand, unspecified (n = 1). Values are presented as n (%).

Anatomic distribution

Forty-five tumors(80.4%)were digital and 11(19.6%) extradigital. Extradigital sites were the palm in three cases, the forearm in three cases, the wrist in one case, the upper arm in one case, the hand without further specification in one case, and the arm without a stated level in two cases. Among the 45 digital tumors, the affected digit was specified in 38 cases: the thumb in 11(28.9%),the second digit in eight(21.1%),the third and fifth digits in seven each(18.4%),and the fourth digit in five(13.2%).No single digit dominated. Seventeen tumors(30.4% of the cohort, 37.8% of digital tumors)were explicitly described as nail-related or subungual.

Digital versus extradigital lesions

Female sex was strongly associated with digital disease. Women accounted for 38 of 45 digital tumors (84.4%) but for only five of 11 extradigital tumors(45.5%);this difference was significant (Fisher exact test, p=0.013), with an odds ratio of 6.51 for female sex among digital lesions. Mean age at diagnosis was 45.0±12.7 years in the digital group and 49.8±12.7 years in the extradigital group, a difference that did not reach significance (p=0.244) (Table 1).

Table 1. Comparison of digital and extradigital upper-extremity glomus tumors.

Characteristic	Digital (*n* = 45)	Extradigital (*n* = 11)	Effect estimate	*P* value
Age, years, median (range)†	45 (25–80)	49 (28–67)	—	0.244†
Female sex, *n* (%)‡	**38 (84.4)**	**5 (45.5)**	**OR 6.51**	**0.013‡**

† Mann–Whitney *U* test.
‡ Fisher's exact test.
OR, odds ratio.

Clinical presentation, imaging and surgery

A discharge summary was retrievable for 40 of 56 patients(71.4%); 35 of these contained a usable clinical narrative. Pain was the presenting complaint in almost every record, and focal tenderness on palpation was the dominant physical sign. Cold sensitivity was explicitly documented in three patients, denied by none, and the remainder were silent on the matter. Symptom duration before surgery was reported for 15 patients, with a median of 66 months (mean 86.4; range 12-240). One patient had experienced digital pain for 20 years, including episodes that woke her at night.

Five patients received different preoperative working diagnoses: neuroma in two patients, and foreign body, ganglion, and granuloma annulare in one patient each. Three of these five lesions were extradigital or non-subungual. A further five patients had previously undergone surgery for the same lesion: two were re-excised at our institution at six months and three years after the index procedure, and three reported prior surgery elsewhere. One patient reported blunt trauma to both hands seven years before symptom onset.

Preoperative imaging was documented in eight patients: magnetic resonance imaging in five and

plain radiography in three. Bone involvement was recorded in eight patients, manifesting as cortical scalloping, a mass indenting the distal phalanx, or curettage with cauterization of the underlying bone bed; one patient required iliac crest bone grafting for a distal phalangeal defect.

Table 2. Histologic variants and margin-reporting categories in the primary cohort (n = 56).

A. Histologic variants (n = 56)	n (%)	Proportion
Conventional / unspecified solid glomus tumor	54 (96.4%)	
Symplastic glomus tumor	1 (1.8%)	
Pericytic / perivascular glomus tumor	1 (1.8%)	

No included primary case was reported as malignant.

B. Margin-reporting categories (n = 56)	n (%)	Proportion
Positive	9 (16.1%)	
Close	3 (5.4%)	
Negative	5 (8.9%)	
Unassessable	2 (3.6%)	
Not reported	37 (66.1%)	

When an operative note was available, the most frequent technique was a transungual approach with nail-bed incision, and replacement of the nail plate as a biological dressing (18 patients); lateral or midlateral incisions were used in three patients, and direct volar or dorsal approaches were used in nine patients. Anesthesia was general or by laryngeal mask in approximately half of patients, and regional (digital block or local infiltration) in the remainder. No intraoperative or postoperative complications were recorded; documented follow-up did not extend beyond the first dressing and suture removal, so recurrence rates could not be calculated.

Pathologic features

Fifty-four tumors were reported as conventional or otherwise unspecified solid glomus tumors. Representative histopathologic and immunohistochemical features are shown in Figure 3. No included lesions were malignant. The single malignant glomus tumor in the archive arose in the thigh, presented with metastases to bone and liver, and was excluded from the lower-extremity lesion category.

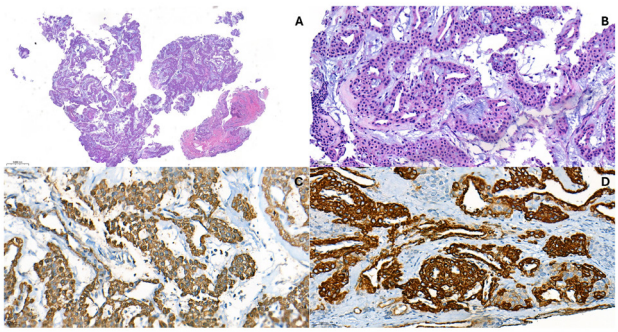

Figure 3. Representative histopathologic features. (A) Low-power haematoxylin–eosin section showing a circumscribed perivascular lesion (x2.8); (B) High-power view showing uniform round glomus cells surrounding vascular channels, (x24.2); (C) Glomus cells are positive with smooth muscle actin (x41.2); and (D) Caldesmon (x29.4) immunostains.

Explicit margin wording was present in 19 of 56 reports (33.9%): nine described lesion continuity with a surgical margin, three described a close margin, five described tumor-free margins, and two were unassessable because the specimen was fragmented. Margins were not reported in 37 cases (66.1%; Table 2).

DISCUSSION

Four findings stand out in this two-decade series of 56 adults: four-fifths of upper-extremity glomus tumors were digital; three-quarters occurred in women; women were diagnosed approximately 13 years earlier than men; and the female predominance was concentrated almost entirely in digital disease, whereas extradigital lesions showed a balanced sex distribution.

The sex-site interaction is the most clinically actionable observation. Traditional descriptions of solitary subungual glomus tumor emphasize female predominance, and our digital subgroup reproduced this at 84.4% (1,6,17). Extradigital tumors, by contrast, were as likely to occur in men as in women, a pattern consistent with the two recent large series cited above (14,15). Schiefer et al. (4) demonstrated that extradigital lesions also differ clinically from classic subungual disease, with reduced cold sensitivity and frequent diagnostic delay; our data add a demographic dimension to that argument. The practical consequence is that a painful subungual

lesion in a woman prompts immediate suspicion, whereas a small painful nodule on a man's forearm does not prompt immediate suspicion. Glomus tumor should be included in the differential diagnosis of any small, exquisitely painful, well-localized soft-tissue lesion of the upper limb, irrespective of nail involvement or patient demographic profile.

Diagnostic delay in our cohort was measured in years rather than months; the median recorded symptom duration was 66 months, with a maximum of 20 years. Five patients carried an incorrect preoperative label; three of the lesions were extradigital (outside the nail unit). Five patients had already undergone surgery for the same lesion, three of them elsewhere. These figures are consistent with reports that fingertip glomus tumor is a frequently missed diagnosis and indicate that the diagnostic problem in our setting lies in initial clinical recognition rather than in pathologic interpretation(17-20).

Our derived mean age at diagnosis of 45.9 years is lower than the 54.6 years reported by Hufschmidt et al., and the discrepancy carries a methodological lesson (3). Our pathology information system exports age at data extraction, not age at diagnosis; if used unadjusted, it would have produced a spuriously high mean of 55.1 years, coincidentally close to the published figure. Any archive-based study spanning two decades must verify the age that the data source records. A related terminological pitfall is that 12 of our 87 archival records—carotid body, jugulotympanic, or other cervical paragangliomas— were retrieved solely because the word glomus persists in their nomenclature. Neither problem is detectable without manual review of records.

The deliberate exclusion of glomuvenous malformation deserves emphasis because it distinguishes this cohort from many published series. Current name as a subtype of glomus tumor as glomuvenous malformation (properly named as glomangioma), is not simply a vascular-rich variant of the solid glomus tumor (21). It is frequently multiple, commonly familial, with autosomal dominant inheritance, compressible and blue rather than pinpoint and subungual, and typically far less painful; its management differs correspondingly (21,22). Pooling these lesions with solitary solid glomus tumors inflates the apparent proportion of extradigital and multiple disease, dilutes the pain and cold-sensitivity phenotype, and weakens any inference about diagnostic delay, because a painless blue nodule is not missed for the same reasons that a subungual tumor is. Restricting the cohort to solid tumors therefore ensures phenotypic homogeneity with almost no reduction in sample size.

Recent molecular evidence reinforces this exclusion. Agaram et al. (18) identified NOTCH-gene fusions in 54% of glomus tumors, NOTCH2 accounting for 88% of rearrangements, and proposed a sub-classification into fusion-negative benign acral tumors and NOTCH-rearranged tumors of the extremity soft tissues and viscera. Half of the fusion-negative tumors were in the fingers, including all subungual lesions, whereas the rare lesions with glomangiomatous architecture occurred exclusively in the fusion-positive, non-subungual group (18). The glomuvenous malformation phenotype therefore appears to track the NOTCH-rearranged pathway rather than the fusion-negative acral pathway that defines classic subungual disease (19). Accordingly, excluding glomuvenous malformation aligns this cohort not only phenotypically but, in all likelihood, molecularly with the fusion-negative acral subset.

No included tumor was malignant. The single malignant glomus tumor identified during screening arose in the thigh and presented with disseminated metastases, in keeping with the observation of Folpe et al. that deep location and large size are the principal determinants of malignant potential (16). Subungual and digital lesions are, almost by definition, small and superficial, consistent with the benign behaviour observed here. Nonetheless, large or deep extradigital tumors warrant careful measurement and assessment for mitotic activity and nuclear atypia, with smooth-muscle actin immunohistochemistry useful in difficult cases (2).

Only 37.8% of digital tumors were explicitly labelled nail-related, which is certainly an underestimate, since surgical series report far higher subungual proportions

(8). Our operative notes support this: a transungual approach was the most frequent technique, a finding that is difficult to reconcile with a genuinely non-subungual majority. The final diagnosis often records "finger mass" or "distal phalanx" without preserving nail-unit topography, so pathology text is reliable for broad anatomic classification but not for nail-bed zoning, matrix relationships or choice of approach (13,23). Margin wording was likewise absent in two-thirds of reports and, where present, was probably recorded selectively; the nine margin-positive cases are pathologic descriptions, not a cohort-wide estimate of incomplete excision, particularly since curettage and cauterization of the tumor bed are not captured by margin status at all (24,25).

This study has clear limitations. It is retrospective and single-center, and the source dataset originated from a pathology information system rather than a prospective registry; consequently, anatomic terminology and margin reporting were not standardized. Discharge summaries were retrievable for only 71.4% of patients; cold sensitivity, nail changes, dominant hand, tumor size, and comorbidity were documented too inconsistently to support rate estimates. Outpatient follow-up records for this period are no longer retrievable from the institutional archive; therefore recurrence, symptom-relief, and nail-outcome rates cannot be reported. The two institutional re-excisions represent a minimum rather than a measured recurrence figure. In two patients, the digit or side recorded in the pathology report conflicted with the operative record; both conflicts were resolved by the treating surgeon in favour of the clinical record. Age at diagnosis is a derived rather than directly recorded variable, albeit validated against 28 independent statements of age. Finally, no molecular testing was performed on our cases; therefore, the proposed alignment with the fusion-negative acral subset is based entirely on external evidence. The strengths include a 20-year window, a site-specific protocol, patient-level rather than specimen-level counting, the prespecified exclusion of glomuvenous malformation and glomangiomyoma, and a two-stage anatomic adjudication against clinical records, which altered the eligibility or classification of eight patients in ways that pathology text alone would not have revealed.

In conclusion, upper-extremity glomus tumors in this cohort were predominantly digital and occurred in females, whereas extradigital lesions accounted for approximately one-fifth of cases and showed a balanced sex distribution. Diagnostic delay remained substantial, often extending over several years, and extradigital or non-subungual lesions were frequently present among cases with an alternative preoperative diagnosis. Three patients presented following unsuccessful surgery performed elsewhere. These findings support maintaining a high index of suspicion for glomus tumor throughout the upper extremity, particularly in men and patients without nail-unit involvement. Because margin reporting and longitudinal follow-up were incomplete, conclusions regarding resection adequacy, recurrence, and functional outcomes cannot be drawn reliably from this retrospective cohort. Prospective studies incorporating standardized topographic classification, molecular characterization, and structured long-term follow-up are warranted.

Author Contributions: Medical and Surgical Practices: S.E.A., B.A.K., S.Y., S.S.; Concept: S.E.A., B.A.K.; Design: S.E.A.; Data Collection or Processing: S.E.A., F.Ö., B.A.K., S.Y.; Analysis or Interpretation: S.E.A., F.Ö.; Literature Search: S.E.A., F.Ö.; Writing: S.E.A., S.S.

Conflict of interest: No conflict of interest has been declared by the authors for this manuscript.

Funding: No funding has been received for this work.

Ethical Approval: Ethical approval has been obtained from Institutional Ethics Committee, approval number 2025/626, date: 6.11.2025.

Patient Consent: Patient consent was waived because the study is a retrospective review of archived pathology reports and hospital records, all data were anonymized before analysis, no identifiable patient information or images are reported, and the waiver was approved by the institutional ethics committee.

Data Availability: The anonymized dataset supporting the findings of this study is available from the corresponding

author upon reasonable request. The data are not publicly deposited because they derive from institutional patient records.

AI disclosure: The authors used artificial intelligence tools for language editing and stylistic refinement. All data analysis, clinical interpretation, and scientific conclusions remain the sole responsibility of the authors.

REFERENCES

1. Lee W, Kwon SB, Cho SH, et al. Glomus tumor of the hand. Arch Plast Surg. 2015;42:295-301.
2. Mravic M, LaChaud G, Nguyen A, et al. Clinical and histopathological diagnosis of glomus tumor: an institutional experience of 138 cases. Int J Surg Pathol. 2015;23:181-188.
3. Hufschmidt K, Foissac R, Camuzard O, et al. Glomus tumors of the upper limb: single-center retrospective study of clinical and functional outcomes. Hand Surg Rehabil. 2017;36:290-295.
4. Schiefer TK, Parker WL, Anakwenze OA, et al. Extradigital glomus tumors: a 20-year experience. Mayo Clin Proc. 2006;81:1337-1344.
5. Chou T, Pan SC, Shieh SJ, et al. Glomus Tumor: Twenty-Year Experience and Literature Review. Ann Plast Surg. 2016;76 Suppl 1:S35-40.
6. Van Geertruyden J, Lorea P, Goldschmidt D, et al. Glomus tumours of the hand. A retrospective study of 51 cases. J Hand Surg Br. 1996;21(2):257-260.
7. Altarifi ME, Kalas A, Al-Najjar A, et al. Glomus tumor: A rare differential diagnosis for subungual lesions. Radiol Case Rep. 2024;19(12):6034-6038.
8. Vasisht B, Watson HK, Joseph E, et al. Digital glomus tumors: a 29-year experience with a lateral subperiosteal approach. Plast Reconstr Surg. 2004;114:1486-1489.
9. Drapé JL, Idy-Peretti I, Goettmann S, et al. Subungual glomus tumors: evaluation with MR imaging. Radiology. 1995;195:507-515.
10. Ham KW, Yun IS, Tark KC. Glomus tumors: symptom variations and magnetic resonance imaging for diagnosis. Arch Plast Surg. 2013;40:392-396.
11. Rohrich RJ, Hochstein LM, Millwee RH. Subungual glomus tumors: an algorithmic approach. Ann Plast Surg. 1994;33:300-304.
12. Tada H, Hirayama T, Takemitsu Y. Prevention of postoperative nail deformity after subungual glomus resection. J Hand Surg Am. 1994;19(3):500-503.
13. Civan O, Güntürk ÖB, Özaksar K, et al. Glomus tumors of the nail bed: topographic anatomy and an algorithmic approach based on the topography. Handchir Mikrochir Plast Chir. 2020;52:202-206.
14. Marcoval J, Boronat-Cucarull J, Gangonells-Dols M, et al. Glomus tumors: a clinical study of 143 patients. Int J Dermatol. 2025;65:1052-1054.
15. Lee WQ, Li Y, Yeo NEM. Glomus tumour: an institutional experience of 31 cases. J Orthop Surg Res. 2023;18:741.
16. Folpe AL, Fanburg-Smith JC, Miettinen M, et al. Atypical and malignant glomus tumors: analysis of 52 cases, with a proposal for the reclassification of glomus tumors. Am J Surg Pathol. 2001;25:1-12.
17. Santoshi J, Kori V, Khurana U. Glomus tumor of the fingertips: A frequently missed diagnosis. J Family Med Prim Care. 2019;8(3):904-908.
18. Agaram NP, Zhang L, Jungbluth AA, et al. A molecular reappraisal of glomus tumors and related pericytic neoplasms with emphasis on NOTCH-gene fusions. Am J Surg Pathol. 2020;44(11):1556-1562.
19. Mosquera JM, Sboner A, Zhang L, et al. Novel MIR143-NOTCH fusions in benign and malignant glomus tumors. Genes Chromosomes Cancer. 2013;52(11):1075-1087.
20. Morey VM, Garg B, Kotwal P. Glomus tumours of the hand: review of literature. J Clin Orthop Trauma. 2016;7(4):286-291.
21. Khopkar U, Kumari I, Mohanty S, et al. Solitary extradigital glomangioma with thrombus presenting as a painful nodule. Indian J Dermatopathol Diagn Dermatol. 2019;6(1):39.
22. Borroni RG, Grassi S, Diegoli M, et al. Incomplete penetrance of GLMN gene c.395–1G>C mutation in a family with glomuvenous malformations. Int J Dermatol. 2014;53(11):1362–1364.
23. Grover C, Jayasree P, Kaliyadan F. Clinical and onychoscopic characteristics of subungual glomus tumor: a cross-sectional study. Int J Dermatol. 2021;60(6):693-702.
24. Kumar S, Tiwary SK, More RS, et al. Digital glomus tumor: an experience of 57 cases over 20 years. J Family Med Prim Care. 2020;9(7):3514-3517.
25. Huang HP, Tsai M, Hong KT, et al. Outcome of microscopic excision of a subungual glomus tumor: a 12-year evaluation. Dermatol Surg. 2015;41(4):487-492.