Nephrol Dial Transplant (1999) 14: 2461–2463

Nephrology
Dialysis
Transplantation

Case Report

Chronic graft-*versus*-host disease complicated by membranous glomerulonephritis

Gökhan Nergizoğlu[1], Kenan Keven[1], Kenan Ateş[1], Celaletttin Üstün[2], Özden Tulunay[3], Meral Beksaç[2], Oktay Karatan[1] and A. Ergün Ertuğ[1]

Departments of [1]Nephrology, [2]Haematology and [3]Pathology, Ankara University School of Medicine, İbn-i Sina Hospital, Ankara, Turkey

Key words: graft-*versus*-host disease; nephrotic syndrome

Introduction

Graft-*versus*-host disease (GVHD) is a major complication of patients who undergo allogeneic haematopoietic stem cell transplantation (alloHSCT). It occurs in 50% of patients with alloHSCT and results from recognition of recipient tissues by the engrafted donor T cells [1]. Whilst clinical manifestations appear within the first few weeks after transplantation in the acute form, the chronic form occurs a few months to a year following transplantation. Many of the features seen in chronic form GVHD (cGVHD) are similar to various immune complex disorders such as collagen vascular diseases. Although murine GVHD has been studied as a model of lupus nephritis [2], in humans glomerulonephritis is rare in bone marrow transplant recipients. Here, we report a patient who was treated with alloHSCT due to chronic myelogenous leukaemia (CML). He subsequently developed nephrotic syndrome following active mucosal cGVHD.

Case

In March 1996, a 30-year-old woman was diagnosed as having Philadelphia chromosome (Ph+) CML in chronic phase. Renal functions and liver enzymes were within the normal range.

The patient had commenced hydroxyurea until alloHSCT was performed. Busulphan 4 mg/kg/day for 4 days and cyclophosphamide 60 mg/b.w./day for 2 days were administered as conditioning regimen. In December 1996, the patient received 10.4×10^8/b.w. mononuclear cells, 8.76×10^6/b.w. CD34+ cells, from her HLA-identic sibling. Cyclosporin A (CsA) was administered for GVHD prophylaxis from day −1 to day +180. Ten-months after alloHSCT, a mucosal ulceration and dryness in her mouth was observed. A mucosal form of cGVHD was diagnosed on the basis of clinical and biopsy findings. CsA (400 mg/day) and corticosteroid (16 mg/day) were commenced. Due to response in the lesions, the corticosteroid and CsA were gradually tapered.

In December 1997, the patient was admitted to the hospital because of bilateral ankle oedema and watery diarrhoea. On the physical examination, blood pressure was 110/70 mmHg, pulse was 78/min, and temperature was 36.7°C. Conventional cytogenetics revealed absence of Ph+ chromosome in 20 metaphases which was confirmed by Variable Non-Tandom Repeats as complete chimerism. She had partially healed mucositis in her mouth. In laboratory investigations; white cell count was 5400/mm^3, haemoglobin level 13 g/l, platelet 178 000/mm^3, sedimentation rate 99 mm/h. Urine test rendered (+++) proteinuria. Twenty-four hour urinary albumin loss was 9.9 g. Serum albumin was 2.8 g/dl, total protein 4.9 g/dl, blood creatinine 1.0 mg/dl, blood urea nitrogen 21 mg/dl, AST 11 U/l, ALT 14 U/l, ALP 82 U/l, GGT 35 U/l. Total cholesterol was 466 mg/dl and triglyceride 383 mg/dl. Antinuclear antibody was negative, anti double-stranded DNA was 1.9 IU/ml, serum immunoglobulin levels and complement levels (C3, C4) were within the normal range. Viral tests were; hepatitis B surface antigen (HBsAg) (−), anti HBsAg (+), cytomegalovirus IgM (−), IgG (+), Ebstein–Barr virus IgM (−), IgG (+), hepatitis C virus antibody (−). Renal venous Doppler ultrasonography was normal excluding renal venous thrombosis. Abdominal ultrasonography chest X-rays were normal.

Renal biopsy was performed and membranous glomerulonephritis (MG) was diagnosed on the basis of light and immunofluorescence microscopy (Figure 1). There was mild thickening of the capillary basement membranes with mild interstitial fibrosis. No interstitial infiltration and any vascular abnormalities which may be the evidence for CsA toxicity were found.

Correspondence and offprint requests to: Gökhan Nergizoğlu, Şehit Cemalettin cad. 117/7, Aydınlıkevler, 06130, Ankara, Turkey.

© 1999 European Renal Association–European Dialysis and Transplant Association

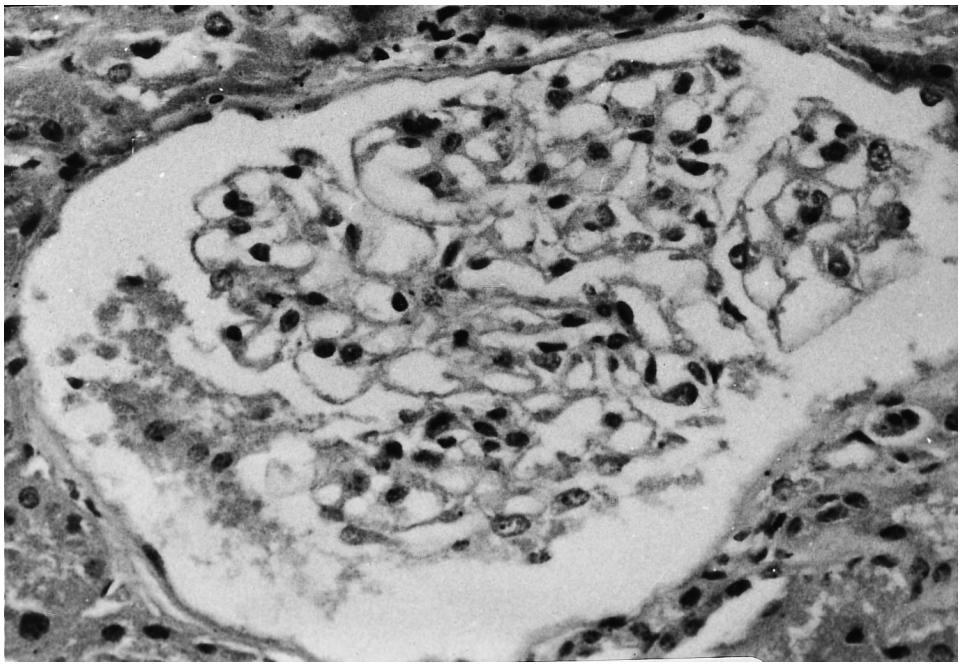

Fig. 1. Mild global thickening of the capillary basal membranes in absence of cellular proliferation. (H&E ×200).

Immunofluorescence study showed the diffuse granular basement membrane deposition of IgG and absence of complement (C3) deposition.

Corticosteroid was increased from 8 mg/day to 40 mg/day and CsA dose was not changed (275 mg/day). The proteinuria was gradually decreased the following month (3 g/day). Serum albumin and total protein returned to normal levels. Oedema disappeared. The patient has been followed up with the same immunosuppressive drugs. Now after 12 months from the diagnosis of nephrotic syndrome, the patient has 1.2 g/day albuminuria and mild oral mucositis. The current CsA dose is 200 mg/day and corticosteroid is 8 mg alternate day.

Discussion

Renal damage after HSCT can be induced by several conditions such as total-body irradiation (TBI), CsA treatment and other nephrotoxic agents [3]. In our patient, TBI was not used in conditioning regimen. Although CsA was a potential renal toxic agent, which might induce tubular damage, glomerular thrombosis, interstitial nephritis and interstitial fibrosis in our patient, the biopsy findings were not compatible with CsA toxicity. In addition, there was no history of drug and any disease that might be involved in the pathogenesis of MG. Chronic GVHD resembles variety of immune complex diseases and mostly affects skin, liver, eyes, mouth, gastrointestinal and upper respiratory system [4]. Renal involvement is a very rarely seen manifestation during the course of cGVHD. Up until now, seven cases have been reported in the literature [5–10]. In our case, nephrotic syndrome was diagnosed at the time of mucosal cGVHD. Renal biopsy was performed and revealed MG.

Of the previous seven cases, two had minimal change disease [5] and five had MG [6–10]. Interestingly, an episode of acute GVHD, which was reported in all previous cases, was not detected in our patient. Immune complex-mediated renal injury plays a key role in the pathogenesis of MG. In experimental studies, lupus nephritis was induced extensively by murine GVHD models and it provides support that immune complex-mediated mechanism during the course of GVHD may have a role in the pathogenesis of MG [2]. Since T cells play a crucial role in initiating of GVHD, attempts at prevention and treatment of GVHD include immunosuppressive drugs such as CsA and methotrexate. Previous reported cases showed that CsA appears to have substantial efficacy in MG complicated with cGVHD. In the literature, two cases of cGVHD developed nephrotic syndrome after withdrawal of CsA treatment and the proteinuria decreased gradually when CsA was recommenced [6,7]. However, in the other case of cGVHD, nephrotic syndrome developed under the CsA treatment and there was MG along with CsA toxicity on renal biopsy. The CsA was ceased and chlorambusil and prednisolone were introduced. After three cycles of the treatment, there was no prominent response. CsA was recommenced and proteinuria decreased substantially [8]. In our case, nephrotic syndrome appeared under the CsA treatment, and proteinuria decreased and serum albumin returned to the normal level with increasing doses of corticosteroid and previous doses of CsA. In addition Sato *et al.* received a good response with increasing doses of corticosteroid in their case of MG associated with cGVHD [9]. Thus, it can be inferred that the

likelihood of response to the immunosuppressive treatment appears to be effective in MG complicated with cGVHD. After increasing corticosteroid and without changing the doses of CsA, proteinuria decreased and serum albumin returned to the normal level. The patient has now been stable for more than 12 months.

In summary, glomerular disease can be a new cGVHD related immune disorder in bone marrow transplant recipients and more studies are needed to better clarify such an association.

References

1. Wick MR, Moore SB, Gastineau DA *et al.* Immunologic, clinical and pathologic aspects of human graft-versus-host disease. *Mayo Clin Proc* 1983; 58: 602–612
2. Brujin JA, Van Elven EH, Hogendoorn PCW, Corver WE, Hoedemaeker PJ, Fleuren GJ. Murine chronic graft-versus-host disease as a model for lupus nephritis. *Am J Path* 1988; 130: 639–643
3. Bergstein J, Andreoli SP, Provisor AJ, Yum M. Radiation nephritis following total-body irradiation and cyclophosphamide in preparation for bone marrow transplantation. *Transplantation* 1986; 41: 63–66
4. Nash RA, Hematopoietic stem cell transplantation. In: Lee GR, Foerster J, Lukens J, Paraskevas F, Greer JP, Rodgers GM, (eds) *Wintrobe's Clinical Hematology*, Tenth edition, Williams & Wilkins, Baltimore: 1999: 875–896
5. Garcia PG, Arroyo CH, Gomez AT *et al.* Renal involvement in chronic graft-versus-host disease: a report of two cases. *Bone Marrow Transplant* 1988; 3: 357–362
6. Barbara JAJ, Thomas AC, Smith PS, Gillis D, Ho JOK, Woodroffe AJ. Membranous nephropathy with graft-versus-host disease in a bone marrow transplant recipient. *Clin Nephrol* 1992; 37: 115–118
7. Hiesse C, Goldschmidt E, Santelli G, Charpentier B, Machover D, Fries D. Membranous nephropathy in a bone marrow transplant recipient. *Am J Kidney Dis* 1988; 11:188–191
8. Müller GA, Müller CA, Lipkowski JM. Membranous nephropathy after bone marrow transplantation in cyclosporin treatment. *Nephron* 1989; 51: 555–556
9. Sato N, Kishi K, Yagisawa K. Nephrotic syndrome in a bone marrow transplant recipient with chronic graft-versus-host disease. *Bone Marrow Transplant* 1995; 16: 303–305
10. Yorioka N, Taniguchi Y, Shimote K *et al.* Membranous nephropathy with chronic graft-versus-host disease in a bone marrow transplant recipient. *Nephron* 1998; 80: 371–372

Received for publication: 26.2.99
Accepted in revised form: 10.6.99