PATHOLOGICA 2022;114:332-338
DOI: 10.32074/1591-951X-757

Case Report

Primary adenosquamous carcinoma of the endometrium with glassy cell features. A diagnostic pitfall as a very rare tumour type in the endometrium

Selim Sevim, Duygu Enneli, Ezgi Dicle Serbes, Cevriye Cansiz Ersoz, Seher Yuksel

Department of Pathology, Ankara University Medical School, Ankara, Turkey

Summary
Primary adenosquamous carcinoma of the endometrium with glassy cell features (ASC-GCF) is an extremely rare entity and to date, 16 cases of this entity have been reported in the literature. ASC-GCF is an aggressive histological subtype of cervical carcinoma with rapid growth and early metastases; however, very little is known about those originating from the endometrium as they are limited to only a few case reports. Herein, we report a case of primary adenosquamous carcinoma of the endometrium with extensive glassy cell features which posed a major diagnostic challenge by mimicking many entities with its histological diversity.

Key words: adenosquamous, carcinoma, endometrium, glassy cell, pathology

Received: February 18, 2022
Accepted: July 2, 2022

Correspondence
Duygu Enneli
Department of Pathology Ankara University Medical School, Ahmet Adnan Saygun Street 35, Sihhiye 06230 Ankara, Turkey
Tel.: 00 90 3125958103
Fax: 00 90 3125958173
E-mail: duygu.kankaya@gmail.com

How to cite this article: Sevim S, Enneli D, Serbes ED, et al. Primary adenosquamous carcinoma of the endometrium with glassy cell features. A diagnostic pitfall as a very rare tumour type in the endometrium. Pathologica 2022;114:332-338. https://doi.org/10.32074/1591-951X-757

© Copyright by Società Italiana di Anatomia Patologica e Citopatologia Diagnostica, Divisione Italiana della International Academy of Pathology

OPEN ACCESS

This is an open access journal distributed in accordance with the CC-BY-NC-ND (Creative Commons Attribution-NonCommercial-NoDerivatives 4.0 International) license: the work can be used by mentioning the author and the license, but only for non-commercial purposes and only in the original version. For further information: https://creativecommons.org/licenses/by-nc-nd/4.0/deed.en

Introduction

Adenosquamous carcinoma with glassy cell features (ASC-GCF) was first described as a poorly differentiated variant of cervical adenosquamous carcinoma in 1956 by Glucksmann and Cherry and termed as "Glassy cell carcinoma (GCC)" [1]. GCC is a rarely reported cancer which most commonly originates in the uterine cervix and accounts for only about 1-5% of all cervical cancers [2,3]. Cases occurring in the endometrium, fallopian tube, vagina and colon have also been reported [4,5]. GCC arising in the endometrium is much rarer and to the best of our knowledge, the number of GCC cases originating from the endometrium is only 16 in the literature to date.
Herein, we present a case of endometrial adenosquamous carcinoma with extensive glassy cell features which posed a major challenge in the differential diagnosis.

Case report

A 82-year-old patient was admitted to the Department of Obstetrics and Gynecology of Ankara University Medical School with the complaint of abdominal distension. Abdominal CT imaging of the patient revealed a cystic and solid mass lesion, 86x69 mm in size, in the right pelvis (Fig. 1). The patient underwent total abdominal hysterectomy and bilateral salpingooferectomy (TAH-BSO), bilateral pelvic and paraaortic lymph node dissection, omentum resection.

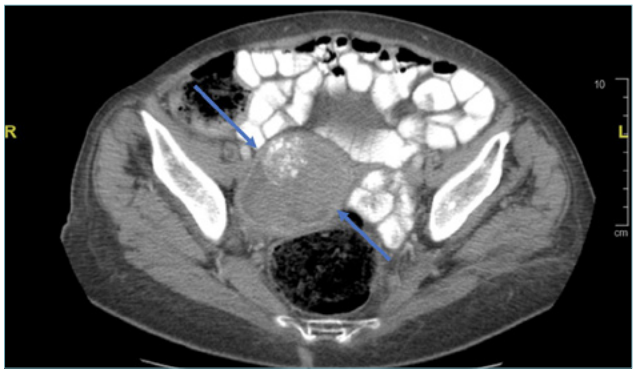

Figure 1. Pelvic computed tomography image. A solid mass, 8.6 cm in long diameter, located in the right half of the pelvis (indicated by arrows).

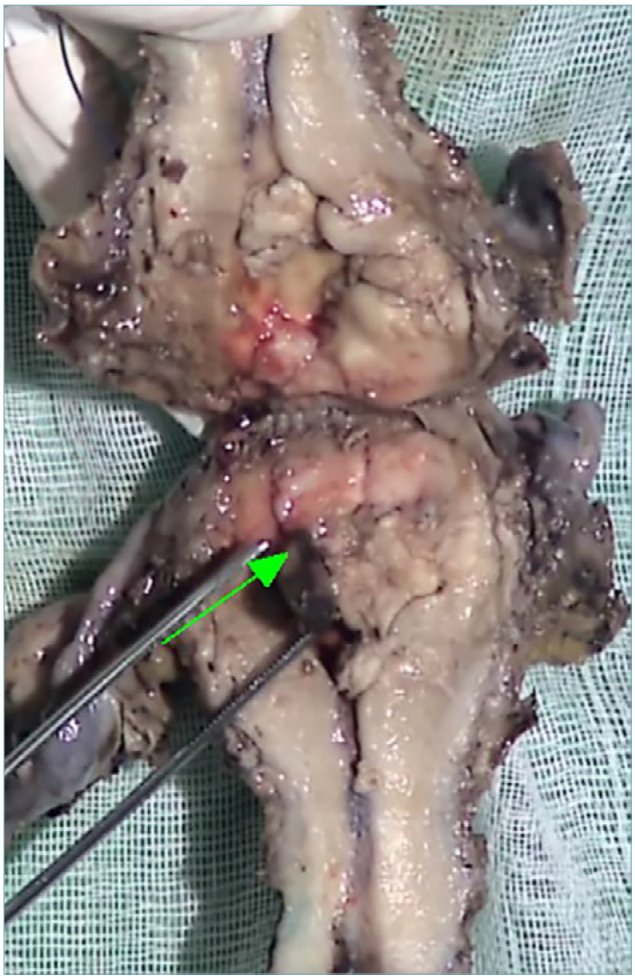

Figure 2. Gross examination of the histerectomy specimen revealed an exophytic mass filling the endometrial cavity and invading deeply the wall of the uterine corpus. It is a cream-white colored solid nodular lesion and do not extend to the cervical wall.

Pathology findings

Gross examination of TAH-BSO material revealed an exophytic mass in uterine corpus, 8.5 cm in long diameter, completely filling the endometrial cavity. It was a cream-white colored solid nodular lesion and infiltrated to the uterine serosa by traversing the uterine wall (Fig. 2). The tumor did not extend to the cervical wall.

Microscopically, the tumour cells were arranged in solid sheets, cords and the background stroma was heavily infiltrated by lymphocytes, plasma cells and eosinophils. Polygonal shaped tumour cells had pale granular eosinophilic, clear or ground glass type cytoplasm with large nuclei, distinct nucleoli and sharp cell borders. Nuclear pleomorphism was prominent and high mitotic activity was observed. Bizarre cells with multinucleation were seen. Extensive emperipolesis of tumour cells was present throughout the neoplasm. Histologic evidence of glandular or squamous differentiation were very focal and required extensive sampling. There was clear cell differentiation focally and spindling of the tumour cells in some areas imitated a sarcomatoid component (Figs. 3, 4). Tumor cells infiltrated the full thickness of the uterine corpus wall and perforated the serosal surface. The tumor was completely localized in the uterine corpus and there was no extension to the cervix. Cervix wall was free of tumour. This finding ruled out the cervix origin of the tumour. Lymphovascular space invasion was detected.

Histochemically mucicarmen was negative in the tumour cells. Periodic acid-schiff (PAS) staining revealed distinct cell membranes of tumour cells more clearly. Glassy cells were negative with PAS and PAS diastase.

A large panel of immunohistochemistry was performed for the differential diagnosis. Spindled tumour cells showed strong and diffuse cytokeratin expression. P40 and p63 were positive in the squamoid areas. Napsin A and AMACR were focally positive in the tumour cells with clear cytoplasm. Multifocal positivity was observed with MUC1. Tumour cells especially in squamoid areas showed membranous, web-like positivity with CD44. CEA (monoclonal) staining in tumour cells was sparse. Loss of E-cadherin expression was detected. P53 showed wild-type staining pattern. P16 overexpression was not seen. ER and PR were negative. Conserved expression of MSH2, MSH6, PMS2 and MLH1 suggested that the tumour is most likely microsatellite stable. High risk HPV (hrHPV) positivity of rare tumour cells were detected by chromogenic in situ hybridisation (CISH) method (Fig. 5). Our diagnosis was poorly differentiated endometrial ASC-GCF.

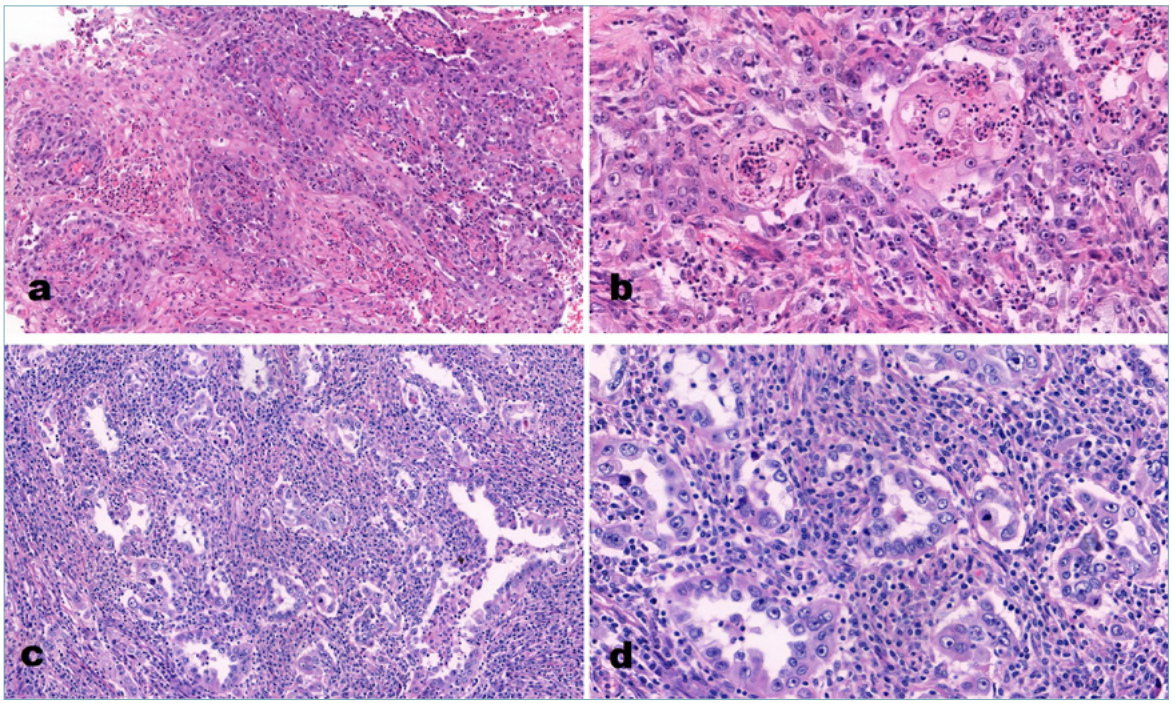

Figure 3. (a) Solid sheets of squamous cells, admixed with inflammatory cells (H&E slide, x10). (b) Higher magnification reveals clear evidence of squamous differentiation. Extensive emperipolesis of tumour cells can be seen (H&E slide, x20). (c) Histologic evidence of glandular differentiation (H&E slide, x10). (d) Glandular structures composed of round or polygonal tumour cells with prominent nucleoli, eosinophilic cytoplasm (H&E slide, x20).

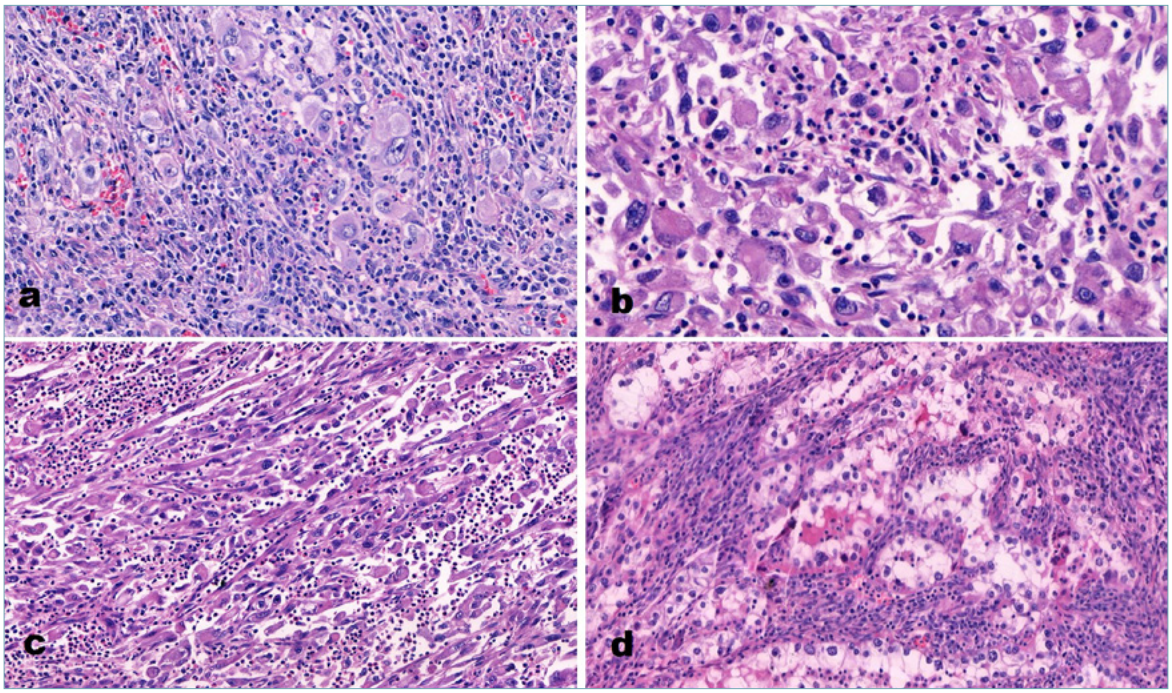

Figure 4. (a) Epithelioid polygonal shaped tumour cells, individually or in small groups, in a background stroma heavily infiltrated by inflammatory cells (H&E slide, x20). (b) Tumour cells with eccentric irregular nucleus, ground glass type cytoplasm and sharp cell borders, some with rhabdoid features. Prominent nuclear pleomorphism (H&E slide, x20). (c) Spindling of the tumour cells imitating a sarcomatoid component in a background stroma heavily infiltrated by inflammatory cells (H&E slide, x12,1). (d) Tumour cells with clear cytoplasm mimicking clear cell carcinoma (H&E slide, x20).

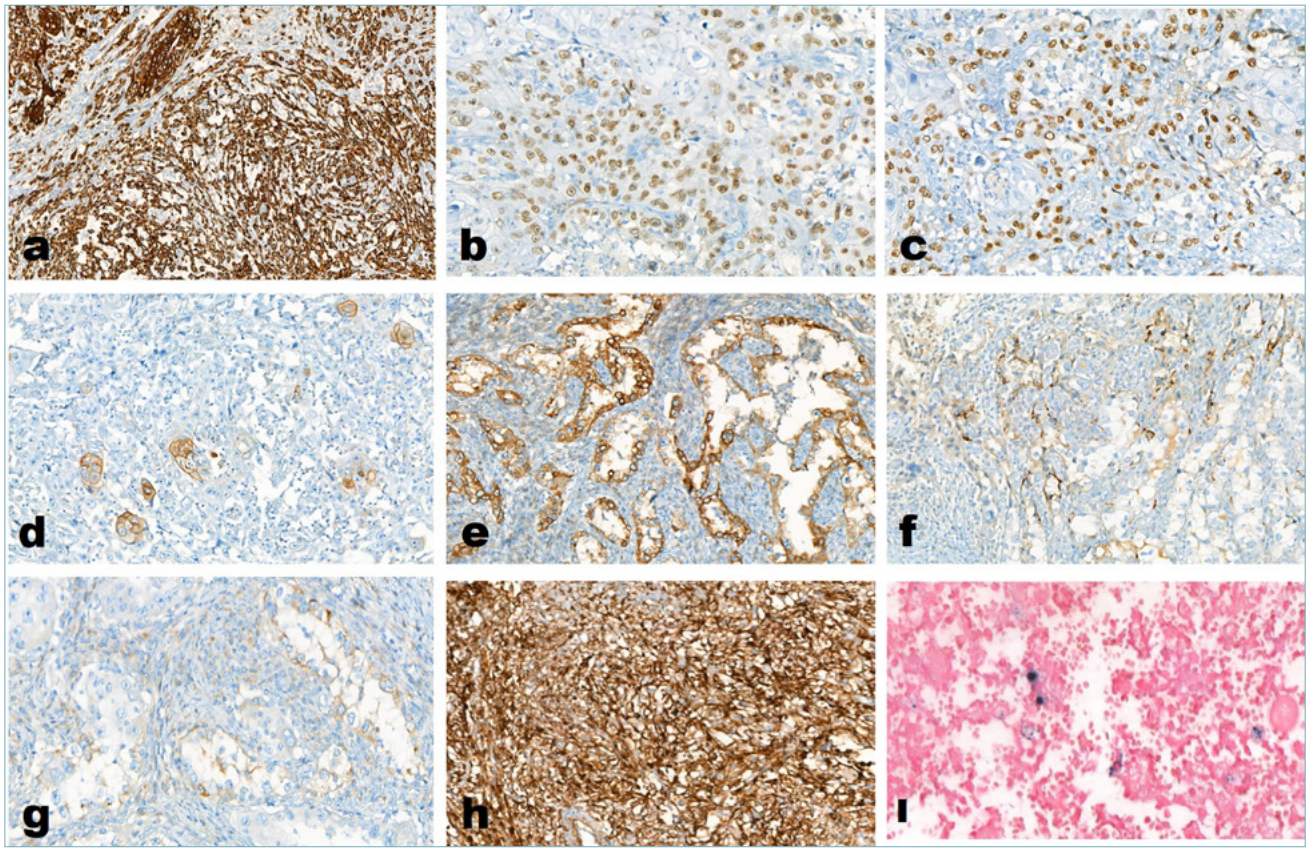

Figure 5. (a) Strong and diffuse cytokeratin positivity including spindled tumour cells (x5). (b,c) P40 and p63 immunostaining of squamoid tumour cells, respectively (x20, x20). (d) Focal carcinoembryonic antigen staining of tumour cells (x10). (e) Multifocal MUC1 immunostaining (x10). (f, g) Focal Napsin A and AMACR positivity in the tumour cells with clear cytoplasm, respectively (x10, x10). (h) Diffuse membranous, web-like positivity with CD44 (x5). (i) High risk HPV positivity of rare tumour cells, detected by chromogenic in situ hybridisation method (x20).

Of the 41 pelvic and para-aortic lymph nodes dissected, 7 left pelvic and 4 para-aortic lymph nodes were metastatic, and the largest metastasis was 4.2 cm in long diameter. There was extracapsular spread of lymph node metastases. Omentum was free of tumour. The stage of the patient was determined as FIGO IIIC2. The patient received adjuvant paclitaxel and carboplatin chemotherapy.

Review of the literature and discussion

ASC-GCF is a very rare tumour type among gynaecological malignancies and is more likely to be seen in the cervix. It causes a diagnostic pitfall when it is seen in endometrium due to its intratumoural histological diversity and the fact that it is not an expected tumor type among endometrial tumours. To the best of our knowledge, there are only 16 reported cases of endometrial ASC-GCF in the English literature. Our case is the 17th one with a different clinical presentation. Our patient presented with abdominal distension, while previous cases presented with postmenopausal bleeding. Cases of endometrial ASCGCF reported to date in the literature are listed in Table I.

Cases of ASC-GCF seen in cervix occur mainly in younger patients (mean 41 years) and some studies have noted an association with pregnancy or long term use of oral contraceptives [6]. Whereas cases arised in the endometrium occur mainly in postmenouposal period. Dawson et al. published the oldest case, a 96-year-old endometrial GCC case [7] and our patient is the second oldest one after that.

Glassy cell features in an adenosquamous carcinoma are characterized by the presence of tumour cells with ground-glass or granular cytoplasm, large eosinophilic nuclei, prominent nucleoli, and prominent cell membranes [2]. High mitotic activity, atypical mitoses and intense inflammatory cell infiltration are seen. These features can be seen at varying rates in an adeno-

Table I. Reported cases of endometrial ASC-GCF in the literature.

Author	Age (years)	Symptoms	FIGO Stage	Treatment	Follow-up
Cristopherson, et al. [22]	56	Vaginal bleeding	I	RT, H	DOD at 5 months
	70	Vaginal bleeding	I	RT, H	DOD at 32 months
	71	Vaginal bleeding	I	RT, H	Death of pneumonia after 6 years, NED
	78	Vaginal bleeding	I	RT	Suicide after 7 months
	78	Vaginal bleeding	III	RT	DOD after 5 months
Arends, et al. [11]	59	Vaginal bleeding	IIIA	TAH, BSO, RT, Progestins	NED after 24 months
Dawson, et al. [7]	96	Vaginal bleeding	IVB	Megestrol	NED after 16 months
De Rosa, et al. [23]	58	Metrorrhagia	IB	TAH, BSO	DOD after 12 months
	52	Metrorrhagia	IB	TAH, BSO, PND	DOD after 16 months
	58	Metrorrhagia	IB	TAH, BSO, PND	ED at 36 months
Hachisuga, et al. [24]	62	Vaginal bleeding	IIIC	TAH, BSO, PND, RT	NED after 66 months
Mhawech, et al. [25]	60	Vaginal bleeding	IB	TAH, BSO, PND, RT	NED after 60 months
Ferrandina, et al. [21]	63	Vaginal bleeding	IB	TAH, BSO, PND	NED after 69 months
Nagy and Sipos, et al. [26]	68		IA	TAH, BSO, RT	NED after 24 months
Callegari, et al. [27]	64	Abnormal cytology	IA	TAH, BSO, PND	NED after 14 months
Fox, et al. [4]	58	Vaginal bleeding	IA	TAH, BSO, PND	NED after 18 months
Sevim, et al. (Current case)	81	Abdominal distension	IIIC2	TAH, BSO, PND, PaND, O, CT	NED after 15 months

Abbreviations: BSO = Bilateral salpingo-oophorectomy, CT = Chemotherapy, DOD = Death of disease, ED = Alive with evidence of disease, NED = No evidence of disease, O = Omentectomy, PaND = Para-aortic lymph node dissection, PND = Pelvic lymph node dissection, RT = Radiotherapy, TAH = Total abdominal hysterectomy

squamous carcinoma and tumours which are composed entirely of glassy cell features may have no histological evidence of glandular or squamous differentiation [3]. There is confusion in the literature regarding the definition of GCC. While adenosquamous carcinomas containing 30% to 100% glassy cell features were designated as GCC previously, the latest World Health Organization (WHO) classification of female genital tumours no longer recommends the use of the terminology of GCC [8]. The present case caused a diagnostic challenge in our routine practice and we started with a wide list of various tumour types for differential diagnosis. The areas of spindled tumour cells gave the impression of a sarcomatoid component and led to a preliminary misdiagnosis of uterine carcinosarcoma consisting of squamous cell carcinoma as an epithelial component and rhabdomyosarcoma as a heterologous sarcomatous component. Diffuse and strong cytokeratin positivity of the tumour cells indicated that the spindled tumour cells were also of epithelial nature. Desmin and myogenin negativity of the glassy cells with rhabdoid features ruled out the morphological impression of rhabdomyoblastic differentiation. These findings excluded the preliminary diagnosis of uterine carcinosarcoma. Poorly differentiated endometrioid carcinoma with areas of squamous metaplasia was another possibility in the differential diagnosis since the tumour was localised in the uterine corpus and consisted of squamous and glandular components. However, ER and PR negativity of the tumour cells and the absence of endometrioid-like appearance in the glandular areas ruled out this possibility. Tumour cells with clear cytoplasm showed focal Napsin A and AMACR positivity mimicking clear cell carcinoma, but the documentation of squamous differentiation by p63 and p40 immunostaining in tumour cells were contrary to the diagnosis of clear cell carcinoma. Malignant melanoma was also included in the differential diagnosis list due to the presence of large eosinophilic nuclei in tumour cells, however diffuse and strong cytokeration expression precluded this possibility. The tumour also showed areas mimicking lymphoepithelioma-like carcinoma, with sheets of poorly differentiated epithelioid cells surrounded by prominent inflammatory cell infiltration, but the obvious glandular and squamous differentiation of the tumour were inconsistent features with this entity. In conclusion, all the histological and immunohistochemical features led us to the diagnosis of "Poorly differentiated ASC-GCF". Since adenosquamous carcinoma is very rare in the uterine corpus in comparison with the cervix, origin of the cervix had to be ruled out first. Localization of the tumour mass entirely in the uterine corpus and absence of any tumour infiltration to the cervical wall excluded the cervix origin, which is the primary site of origin for uterine adenosquamous carcinomas.

Cervical ASC-GCF has been believed to originate from subcolumnar reserve cells [9] and strong association has been found with hrHPV infection, especially HPV type 18 [10]. Histogenesis of endometrial ASC-GCF are unknown. Arends et al. suggested that the ASC-GCF seen in the endometrium might originate from endocervical or isthmic mucosal cells, based on the finding of lysozyme immunoreactivity of tumour cells, which is expected to be expressed in endocervical and isthmic mucosal cells [11]. However, reported cases of stage I endometrial ASC-GCF limited to the uterine corpus without any association with cervix, like our present case, contradict to this hypothesis.

Our case showed hrHPV by CISH, but not accompanied by p16 overexpression. The prevalence of HPV in endometrial cancers is low, even in tumours with squamous differentiation or in pure endometrial squamous tumors. HPV infection does not seem to have any role in the initiation of endometrial carcinoma. It may only be a mere "passenger" in the endometrium since endometrium isnot a suitable host for HPV replication [12]. HPV-associated tumours show a strong overexpression of p16. Despite of the hrHPV positivity, p16 was negative in our case. Negative *p16* immunostaining has been described in a small percentage of cases of hrHPV-positive carcinomas of the vagina, vulva and head and neck [13]. The absence of *p16* immunostaining in a hrHPV-positive tumour may be explained by the inactivation of the tumour suppressor gene p16 due to genetic or epigenetic alterations [14]. Interestingly, p16 inactivation due to either mutation or methylation is a relatively frequent event in different cancers and has been associated with tumor progression and dissemination and with a more aggressive behaviour [15].

As adenosquamous cell carcinoma is a rare tumour type in the cervix and much rarer in the endometrium, very limited genomic profiling has been performed. In a case of endometrial glassy cell carcinoma reported in 2019, next-generation sequencing showed PTEN (phosphatase and tensin), KRAS (v-Ki-ras2 Kirsten rat sarcoma viral oncogene), and TP53 (tumor protein) gene mutations [4]. In an *in vitro* study performed on cell culture obtained from endometrial adenosquamous carcinoma, it was determined that endometrial adenosquamous carcinoma cell lines have a *PTEN* termination mutant, are MSI-Low, are copy number high, and do not have a *POLE* mutation [16]. Since endometrial adenosquamous carcinoma is a very rare tumour type and was not included in the genomic characterisation analysis of endometrial carcinomas within the Cancer Genome Atlas (TCGA) project, the genomic profile of this endometrial tumour type and in which group of the endometrial carcinoma molecular subgroups they should be included in the recent molecular classification are unknown. When we consider the molecular profile of cervical adenosquamous carcinomas according to the findings of the TCGA project, only 3 of the 178 cervical cancers included in were adenosquamous carcinomas. Among the novel genomic and proteomic characteristics that subclassify cervical cancers, cervical adenosquamous carcinoma cases were involved in the "Keratin-low Squamous" group and "Adenocarcinoma-rich" subgroups. They were characterised by overexpression of hormone receptor genes ESR1, PGR and PIK3CA amplification, and PTEN gene deletion [17].

An important problem with this tumour is the lack of standardised treatment protocols, due to their rarity. ASC-GCF of the cervix is an aggressive tumour with a tendency to metastasise early and be relatively resistant to radiation therapy [18]. However, more recent reports suggest that multimodal treatment strategies with postsurgical radiochemotherapy based on paclitaxel-carboplatin has been shown to be effective in cases originating from cervix [19]. Paclitaxel-carboplatin has also been shown to be effective in recurrent cases or in neoadjuvant treatment of tumours [20]. ASC-GCF arised in the endometrium was also reported as a highly aggressive malignancy with a poor prognosis [21]. Our patient received adjuvant chemotherapy and no local recurrence or distant metastasis have been detected for 15 months.

Conclusion

We presented this unusual case as a significant diagnostic pitfall in endometrial pathology. ASC-GCF causes diagnostic problems in the endometrium, because it does not come to mind among the endometrial malignancies as it is very rare in the endometrium (limited to a few case reports reported in the literature) and it mimics several endometrial carcinomas due to its intratumoural histological diversity.

Conflict of interest

The authors declare no conflicts of interest.

Funding

The authors received no specific funding for this work

Ethical consideration

None.

References

1 Cherry CP, Glucksmann A. Incidence, histology, and response to radiation of mixed carcinomas (adenoacanthomas) of the uter-

ine cervix. Cancer 1956;9:971-979. https://doi.org/10.1002/1097-0142(195609/10)9:5<971:aid-cncr2820090518>3.0.co;2-t

2 Zolciak-Siwinska A, Jonska-Gmyrek J. Glassy cell carcinoma of the cervix: a literature review. Eur J Obstet Gynecol Reprod Biol 2014;179:232-235. https://doi.org/10.1016/j.ejogrb.2014.03.035

3 Gray HJ, Garcia R, Tamimi HK. Glassy cell carcinoma of the cervix revisited. Gynecol Oncol 2002;85:274-277. https://doi.org/10.1006/gyno.2001.6523

4 Fox C, Schimp V, Ge L, et al. Glassy cell carcinoma of the endometrium presenting as an ıntracavitary leiomyoma on ultrasound. Am J Case Rep 2019;20:961-964. https://doi.org/10.12659/AJCR.915809

5 Nasu K, Hamasaki C, Takai N, et al. Glassy cell carcinoma arising in the vagina. Acta Obstet Gynecol Scand 2008;87:982-984. https://doi.org/10.1080/00016340802326381

6 Takahashi M, Aoki K, Noda S. Some effect of long-term use of oral contraceptives on cervical neoplasia. In: Kurihara S, ed. Cervical pathology and colposcopy. Amsterdam: Excerpta Medica 1985;21-27.

7 Dawson EC, Belinson JL, Lee K. Glassy cell carcinoma of the endometrium responsive to megestrol acetate. Gynecol Oncol 1989;33:121-124. https://doi.org/10.1016/0090-8258(89)90616-1

8 Stolnicu S, Felix A, Kong CS, eds. WHO Classification of Tumours of Female Genital Tumors. 5th ed. Lyon: IARC 2020, p. 383.

9 Amălinei C, Balan R, Stolnicu S, et al. Adenosquamous cervical carcinoma morphological characteristics. Rev Med Chir Soc Med Nat Iasi 2005;109:343-346.

10 Kim SK, Shim HS, Lee KG, et al. Glassy cell carcinoma predominantly commits to a squamous lineage and is strongly associated with high-risk type human papillomavirus infection. Int J Gynecol Pathol 2009;28:389-395. https://doi.org/10.1097/PGP.0b013e31819343a5.

11 Arends JW, Willebrand D, DeKoning Gans HJ, et al. Adenocarcinoma of the endometrium with glassy-cell features--immunohistochemical observations. Histopathology 1984;8:873-879. https://doi.org/10.1111/j.1365-2559.1984.tb02402.x

12 Giatromanolaki A, Sivridis E, Papazoglou D, et al. Human papillomavirus in endometrial adenocarcinomas: infectious agent or a mere "passenger"? Infect Dis Obstet Gynecol 2007;2007:60549. https://doi.org/10.1155/2007/60549

13 Rakislova N, Clavero O, Alemany L, et al. VVAP study group. Histological characteristics of HPV-associated and -independent squamous cell carcinomas of the vulva: A study of 1,594 cases. Int J Cancer 2017;141:2517-2527. https://doi.org/10.1002/ijc.31006

14 Ferreux E, Lont AP, Horenblas S. Evidence for at least three alternative mechanisms targeting the p16INK4A/cyclin D/Rb pathway in penile carcinoma, one of which is mediated by high-risk human papillomavirus. J Pathol 2003;201:109-118. https://doi.org/10.1002/path.1394

15 Poetsch M, Hemmerich M, Kakies C, et al. Alterations in the tumor suppressor gene p16(INK4A) are associated with aggressive behavior of penile carcinomas. Virchows Arch 2011;458:221-229. https://doi.org/10.1007/s00428-010-1007-4

16 Devor EJ, Gonzalez-Bosquet J, Thiel KW, Leslie KK. Genomic characterization of five commonly used endometrial cancer cell lines. Int J Oncol 2020;57:1348-1357. https://doi.org/10.3892/ijo.2020.5139

17 Cancer Genome Atlas Research Network. Integrated genomic and molecular characterization of cervical cancer. Nature. 2017;543(7645):378-384. https://doi.org/10.1038/nature21386

18 Tamimi HK, Ek M, Hesla J, et al. Glassy cell carcinoma of the cervix redefined. Obstet Gynecol 1988;71(6 Pt 1):837-841.

19 Nasu K, Takai N, Narahara H. Multimodal treatment for glassy cell carcinoma of the uterine cervix. J Obstet Gynaecol Res 2009;35:584-587. https://doi.org/10.1111/j.1447-0756.2008.00968.x

20 Takekuma M, Hirashima Y, Takahashi N. A case of glassy cell carcinoma of the uterine cervix that responded to neoadjuvant chemotherapy with paclitaxel and carboplatin. Anticancer Drugs 2006;17:715-718. https://doi.org/10.1097/01.cad.0000217420.14090.a9

21 Ferrandina G, Zannoni GF, Petrillo M, et al. Glassy cell carcinoma of the endometrium: a case report and review of the literature. Pathol Res Pract 2007;203:217-220. https://doi.org/10.1016/j.prp.2007.02.001

22 Christopherson WM, Alberhasky RC, Connelly PJ. Glassy cell carcinoma of the endometrium. Hum Pathol 1982;13:418-421. https://doi.org/10.1016/s0046-8177(82)80024-5

23 De Rosa G, Barra E, Palombini L, et al. Il carcinoma a cellule vitree dell'endometrio (glassy cell carcinoma dell'endometrio) [Glassy cell carcinoma of the endometrium]. Pathologica 1987;79(1061):339-345.

24 Hachisuga T, Sugimori H, Kaku T, et al. Glassy cell carcinoma of the endometrium. Gynecol Oncol 1990;36:134-138. https://doi.org/10.1016/0090-8258(90)90124-4

25 Mhawech P, Dellas A, Terracciano LM. Glassy cell carcinoma of the endometrium: a case report and review of the literature. Arch Pathol Lab Med 2001;125:816-819. https://doi.org/10.5858/2001-125-0816-GCCOTE

26 Nagy PS, Sipos J. Glassy cell carcinoma of the uterine body: case report and review of the literature. Clinical and Experimental Medical Journal 2009;3:499-503. https://doi.org/10.1556/cemed.3.2009.28527

27 Callegari C, Algeri P, Buzzi A, et al. A case of endometrial glassy cell carcinoma: a rare entity which necessitates of better understanding. Obstet Gynecol Sci 2019;62:478-482. https://doi.org/10.5468/ogs.2019.62.6.478