Matthew S. Hestand, PhD[h]
Joris Delanghe, MD, PhD[j]
Joris R. Vermeesch, Ir, PhD[h,i]
Isabelle Meyts, MD, PhD[c,d]
Xavier Bossuyt, MD, PhD[a,k]

From [a]the Department of Microbiology and Immunology, Experimental Laboratory Immunology, KU Leuven, Leuven, Belgium; [b]the Department of Pediatrics, University Hospital Brussels, Brussels, Belgium; [c]the Department of Microbiology and Immunology, Childhood Immunology, KU Leuven and [d]the Department of Pediatrics, University Hospitals Leuven, Leuven, Belgium; [e]the Department of Pediatrics, CHU Dinant-Godinne, UCL Namur, Yvoir, Belgium; [f]the Department of Pediatrics, AZ Delta, Roeselare, Belgium; [g]the Department of Internal Medicine, Allergy and Clinical Immunology, University Hospitals Leuven, [h]the Department of Human Genetics, KU Leuven, and [i]Genomics Core, UZ Leuven, Leuven, Belgium; [j]the Department of Laboratory Medicine, Ghent University Hospital, Ghent, Belgium; and [k]the Department of Laboratory Medicine, University Hospitals Leuven, Belgium. E-mail: xavier.bossuyt@uzleuven.be.

This work was supported by a Geconcerteerde Onderzoeksactie (GOA) grant from the Research Council of the Catholic University of Leuven, Belgium, and IWT-TBM (ZL36300700). I.M. is supported by a Klinisch onderzoeksfonds (KOF) mandate of the KU Leuven, Belgium.

Disclosure of potential conflict of interest: G. Frans personally received a GOA grant from KU Leuven and support for travel from Academische Stichting Leuven and Fonds Wetenschappelijk Onderzoek (FWO) for this work. I. Meyts' institution received a grant from Shire-CSL Behring for other works and travel expenses from Octapharma-Gilead. X. Bossuyt personally received the GOA grant from KU Leuven for this work. The rest of the authors declare that they have no relevant conflicts of interest.

REFERENCES

1. Akira S, Takeda K. Toll-like receptor signaling. Nat Rev Immunol 2004;4:499-511.
2. Picard C, Casanova JL, Puel A. Infectious diseases in patients with IRAK-4, MyD88, NEMO, or IκB-α deficiency. Clin Microbiol Rev 2011;24:490-7.
3. Picard C, von Bernuth H, Ghandil P, Chrabieh M, Levy O, Arkwright PD, et al. Clinical features and outcome of patients with IRAK-4 and MyD88 deficiency. Medicine (Baltimore) 2010;89:403-25.
4. Hanson EP, Monaco-Shawver L, Solt LA, Madge LA, Banerjee PP, May MJ, et al. Hypomorphic nuclear factor-kappaB essential modulator mutation database and reconstitution system identifies phenotypic and immunologic diversity. J Allergy Clin Immunol 2008;122:1169-77.
5. Frans G, Meyts I, Picard C, Puel A, Zhang SY, Moens L, et al. Addressing diagnostic challenges in primary immunodeficiencies: laboratory evaluation of Toll-like receptor- and NF-κB-mediated immune responses. Crit Rev Clin Lab Sci 2014;51:112-23.
6. Bhattacharya CG. A simple method of resolution of a distribution into Gaussian components. Biometrics 1967;23:115-35.
7. Conte MI, Pescatore A, Paciolla M, Esposito E, Miano MG, Lioi MB, et al. Insight into IKBKG/NEMO locus: report of new mutations and complex genomic rearrangements leading to incontinentia pigmenti disease. Hum Mutat 2014;35:165-77.
8. Keller MD, Petersen M, Ong P, Church J, Risma K, Burham J, et al. Hypohidrotic ectodermal dysplasia and immunodeficiency with coincident NEMO and EDA mutations. Front Immunol 2011;2:61.
9. Frans G, Moens L, Schrijvers R, Wuyts G, Bouckaert B, Schaballie H, et al. PID in disguise: molecular diagnosis of IRAK-4 deficiency in an adult previously misdiagnosed with autosomal-dominant hyper IgE syndrome. J Clin Immunol 2015;35:739-44.

Available online May 5, 2017.
https://doi.org/10.1016/j.jaci.2017.04.017

Treatment of severe forms of LPS-responsive beige-like anchor protein deficiency with allogeneic hematopoietic stem cell transplantation

To the Editor:

LPS-responsive beige-like anchor protein (LRBA) deficiency is a severe primary immunodeficiency with a variable clinical phenotype, including features overlapping with common variable immunodeficiency, autoimmune lymphoproliferative syndrome, and immune dysregulation polyendocrinopathy enteropathy X-linked syndrome and an association with lymphoma.[1-3] Despite accumulating experience, the procedure of allogeneic hematopoietic stem cell transplantation (HSCT) to treat primary multiorgan autoimmunity disorders and combined immunodeficiencies with immune dysregulation, such as LRBA deficiency, is not routine. First, the indication and optimal time point are undetermined. Second, the outcome of HSCT in patients with syndromes with predominant autoimmunity is unclear, given that target antigens of autoimmune reactions remain unchanged, and both autoimmunity and inflammation can persist because of disease-causing factors extrinsic to the hematopoietic and immune system. For instance, LRBA is a ubiquitously expressed protein functioning in autophagy and intracellular vesicle trafficking, facilitating cell-surface translocation of cytotoxic T lymphocyte–associated antigen 4 (CTLA4).[4,5] Its relevance in tissues other than immune cells is unknown.

Augmentation of regulatory T-cell function in LRBA-deficient patients manifesting with chronic enteropathy by regular CTLA4-Ig infusions potentially induces remission.[4] However, not all symptoms respond equally, and patients remain dependent on CTLA4 substitution. Furthermore, the additional use of steroids, sirolimus, hydroxychloroquine, and other immunosuppressants might not prevent the long-term deterioration of patients with this potentially fatal disease. Finally, CTLA4-Ig is not available in many countries because of limited resources. Although HSCT has proved helpful in single patients,[1,6-9] early reports of HSCT in cases of LRBA deficiency indicated a higher transplant-related mortality than in other inborn errors (2 of first 4 patients); it is unclear whether disease status at the time of HSCT or other disease- or transplant-related factors were involved.

To better understand the role of HSCT as a potentially curative treatment for LRBA deficiency, we performed an international European Group for Blood and Marrow Transplantation– and European Society for Immunodeficiencies–wide survey in 2016 to collect information about the HSCT experience. Data were obtained in accordance with the Declaration of Helsinki and an institutional review board review (IRB00002556, 29-142ex16/17) by means of retrospective chart review by local physicians.

From a cohort of 72 patients with LRBA deficiency, 12 underwent HSCT between 2005 and 2016 (Table I).[1,6-9] Indications for transplantation included refractory immune cytopenias, gastrointestinal problems, parenchymal lung disease, failure to thrive, severe neurological or infectious complications, or "severe course of the disease" (Fig 1, *A*, and Table I). Overall survival of patients undergoing transplantation was 67% (8/12 patients); all deaths were due to transplant-related mortality (pre-existing infections, graft failure, multiorgan failure, and thrombotic microangiopathy) and occurred within 3 months of HSCT (Fig 1, Table I, and see Fig E1 in this article's Online Repository at www.jacionline.org). Eleven donors were HLA-matched unrelated (n = 4) or family (n = 7) donors. One of the deceased patients was the only subject of the cohort with a mismatched (haploidentical family) donor. Surviving patients had mostly favorable degrees of remission (complete, 4; good partial, 2 [some mild or moderate potentially LRBA-related symptoms not requiring immunosuppressive

therapy]; and partial, 2 [amelioration of disease but need of immunosuppression for potentially LRBA-related symptoms]) with a median follow-up of 26 months (range, 4-142 months; Fig 1 and Table I). HSCT course and recurrence or persistence of symptoms were apparently not dependent on the donor's LRBA status or on the type/intensity of conditioning. All survivors in complete or good partial remission showed full donor chimerism (>95% donor white blood cells [WBCs]). Two patients with partial remission (requiring immunosuppressive treatment) showed decreasing donor WBC chimerism of less than 90%. Patient 3 had 89% donor WBCs and 88% donor T cells on day +240, further decreasing to 83% and 84%, respectively, on day +720, and was treated with sirolimus and romiplostim for moderate immune thrombocytopenia and autoimmune hemolytic anemia that developed on days +90 and +270, respectively. Patient 9, with only 7% WBC and 23% T-cell chimerism on day +578, was successfully treated with abatacept after attempts with steroids and rituximab for autoimmune hemolytic anemia (see details in Table I). Both patients are clinically stable under the current treatment and did not have other autoimmune symptoms previously showed because of LRBA deficiency (Fig 1, *A*, and Table I). Thus the best results of HSCT for LRBA deficiency were associated with full donor chimerism. Donor source, transplantation regimen, graft-versus-host disease incidence, and disease response are listed in Fig 1 and Table I. Strikingly, LRBA-related symptoms resolved or decreased significantly in number and intensity, and performance scores increased in all HSCT survivors (Fig 1, *A-C*). Consequently, the need for immunosuppressive treatment decreased, and most patients were off immunoglobulin replacement after HSCT (Fig 1, *D* and *E*). Unfortunately, there are no up-to-date follow-up and survival data of patients not undergoing transplantation beyond previous publications of large cohort studies that reported at least 6 deceased of 58 patients not undergoing transplantation but many patients with new diagnoses and family members.[1,2,5]

Although the number of patients surveyed was too small to routinely recommend HSCT for LRBA deficiency based on the evidence collected, these data support the feasibility and curative potential of HSCT and allow us to state 3 important points.

First, remissions without further need for immunosuppression are achievable and occurred in 6 of the 8 surviving patients. No relapse occurred in patients with full donor chimerism. Importantly, although the treatment-requiring autoimmune cytopenias in patients 3 and 9 observed after HSCT were possibly caused by LRBA deficiency because of waning donor chimerism, they could also be attributed to graft failure, after HSCT immune dysregulation or marrow dysfunction, as suspected in the growth factor–responsive thrombocytopenia and neutropenia of patient 11, because such sequelae can occur similarly in HSCT recipients with other underlying diseases. With a median follow-up of 2 years, 6 of 8 patients did not need further pharmacologic immunosuppression or immunoglobulin replacement therapy, indicating curability. Only 1 patient in this cohort received abatacept as bridging treatment to HSCT. It is unclear whether response to abatacept would have changed the HSCT indication. However, despite the overall satisfying responses to abatacept (reported in 10 patients in the cohort of 72 patients), the long-term dependency on this treatment with its associated potential risks remains. The risk of LRBA-related lymphoma or immunosuppression-associated malignancy would be anticipated to be substantially reduced or abolished in HSCT survivors, as well as the future risk of infections, compared with patients undergoing continuous treatment with CTLA4-Ig, sirolimus, or other immunosuppression. Thus, based on the present results, we would proceed to HSCT if a suitable donor was present. The optimal time point remains to be determined, but it can be expected that long-term organ damage will have a negative effect on HSCT results.

Second, among the small cohort of 12 LRBA-deficient patients who underwent transplantation from heterozygous LRBA mutation carriers (n = 6) or LRBA wild-type (n = 1) or unrelated donors (n = 5), no correlation between residual or recurring LRBA-related symptoms and donor LRBA status was detected, arguing against a dose effect of LRBA.[2,6]

Lastly, these data indicate that any alluded LRBA-dependent effects outside the (transplanted) hematopoietic/immune tissues play no or only an inferior role with regard to outcome and remission.

Together, accepting the limitation that the retrospective case series lacked a matched control group, our findings strongly support the use of early HSCT in patients with severe presentations of LRBA deficiency.

We thank the European Group for Blood and Marrow Transplantation and European Society for Immunodeficiencies for providing platforms for data accrual and Sara Crockett for scientific editing. Dr Sharapova thanks E. Haapaniemi, Karolinska Institutet, Huddinge, Sweden, for help with the genetic analyses.

Markus G. Seidel, MD[a]
Katrin Böhm, Cm[a]
Figen Dogu, MD[b]
Austen Worth, MD[c]
Adrian Thrasher, MD[c]
Benoit Florkin, MD[d]
Aydan İkincioğulları, MD[b]
Anke Peters, MD[e]
Shahrzad Bakhtiar, MD[f]
Marie Meeths, MD[g]
Polina Stepensky, MD[h]
Isabelle Meyts, MD[i]
Svetlana O. Sharapova, MD[j]
Laura Gámez-Díaz, PhD[k]
Lennart Hammarström, MD[l]
Stephan Ehl, MD[e,k]
Bodo Grimbacher, MD[k]
Andrew R. Gennery, MD[m]
on behalf of the Inborn Errors Working Party of the European Group for Blood and Marrow Transplantation

From [a]the Research Unit of Pediatric Hematology and Immunology, Division of Pediatric Hematology-Oncology, Department of Pediatrics and Adolescent Medicine, Medical University Gwraz, Graz, Austria; [b]the Department of Pediatric Immunology and Allergy, Ankara University School of Medicine, Ankara, Turkey; [c]the Institute of Child Health, University College London, London, United Kingdom; [d]Immuno-Hémato-Rhumatologie Pédiatrique, Service de Pédiatrie, CHR Citadelle, Liege, Belgium; [e]the Department of Pediatrics and Adolescent Medicine and [k]the Center for Chronic Immunodeficiency (CCI), Medical Center, University of Freiburg, Freiburg, Germany; [f]the Division for Pediatric Stem-Cell Transplantation and Immunology, University Hospital Frankfurt, Frankfurt/Main, Germany; [g]the Childhood Cancer Research Unit, Department of Women's and Children's Health and Clinical Genetics Unit, Department of Molecular Medicine and Surgery, and Center for Molecular Medicine, Karolinska Institutet, Karolinska University Hospital Solna, Stockholm, Sweden; [h]the Department of Bone Marrow Transplantation, Hadassah Hebrew University Medical Center, Jerusalem, Israel; [i]the Department of Pediatric Immunology, Microbiology and Immunology, University Hospitals Leuven, KU Leuven, Leuven, Belgium; [j]the Research Department, Belarusian Research Center for

TABLE I. Clinical characteristics and laboratory parameters of 12 LRBA-deficient patients who underwent allogeneic HSCT

Characteristics	1	2	3	4	5	6
Mutation	c.7162delA	c.5505delT	c.675G>A	c.1420G>A; c.2834_2837delTCTT	c.7162delA	c.2004+2A>G
Age at onset (y)	7	1	3	3	2	3
Previous publication	Tesi et al[7]	Sari et al[8]	*	Gámez-Díaz et al[1]	Gámez-Díazet al[1] and Seidel et al[6]	Gámez-Díazet al[1]
LRBA-directed treatment before SCT						
Steroids	X	X	X	X	X	X
Rituximab					X	
Abatacept						
Sirolimus				X	X	
Hydroxychloroquine						
MMF			X			
Azathioprine	X					X
Other IS			CSA/FK	CSA/FK, infliximab		CSA/FK, basiliximab
IVIG	X	X	X	X	X	X
SCIG	X		X			
SCT conditioning and course						
Indication for SCT	Severe CVID-related clinical problems, ADEM	Severe clinical course unresponsive to treatment	Severe clinical course unresponsive to treatment	Chronic interstitial lung disease, chronic inflammatory bowel disease	Refractory pancytopenia and lymphoproliferation	Recurrent respiratory infections and insufficiency, pancytopenia, lymphoproliferation
Age at HSCT (y)	13	12	7	11	10	6
Year of SCT	2013	2014	2015	2015	2005	2013
Donor type (and LRBA status)	MFD (het)	MSD (ND)	MSD (het)	MUD (ND)	MFD (het)	MMFD (het)
Fludarabin and serotherapy	X	X	X	X	X	X
Treosulfan	X			X		
Busulfan		X	X			
Thiotepa				X		X
Melphalan					X	X
aGvHD						1° (skin)
cGvHD						
Peri-SCT infections				Aspergillosis and CMV (pre-SCT)		AdV
Post-SCT complications/TRM and cause of death				Invasive aspergillosis	Post-SCT autoimmune hepatitis, successfully treated with AZT and resolved	Respiratory failure, lung fibrosis, granuloma, adenovirus pneumonia, graft rejection
Outcome						
Overall survival	X	X	X		X	
FU (mo)	36	25	27	(3)	142	(3)
Donor chimerism (% WBC unless otherwise stated)‡	>95 T, B, myeloid (+3 y)	98 (+2 y)	83 WBC, 84 CD3+ (+2 y†)	100 (d+100)	100 (+3 y)	NA
Remission status	GPR (mild thrombocytopenia and thyroid disease)	CR	PR (moderate cITP and AIHA)	died 3 mo after SCT (TRM)	GPR (mild cITP, vitiligo)	Died 3 mo after SCT (TRM)
Current treatment	None	None	TRA, sirolimus, IVIG	NA	TRA (recently discontinued)	NA

ADEM, Acute disseminated encephalomyelitis; *AdV*, adenovirus; *aGvHD*, acute graft-versus-host disease; *AIHA*, autoimmune hemolytic anemia; *AZT*, azathioprine; *cGvHD*, chronic graft-versus-host disease; *cITP*, chronic immune thrombocytopenia; *CMV*, cytomegalovirus; *CNS*, central nervous system; *CR*, complete remission; *CSA*, cyclosporine A; *CVID*, common variable immunodeficiency; *FK*, tacrolimus/FK506; *FU*, follow-up; *GCSF*, granulocyte colony stimulating factor; *GPR*, good partial remission (mild residual symptoms, potentially LRBA related, but without requirement of immunosuppressive treatment); *het*, heterozygous; *IDDM*, insulin-dependent diabetes mellitus (in this case as sequelae after pancreatitis); *IS*, immunosuppressive drugs; *IVIG*, regular intravenous immunoglobulin replacement therapy; *MFD*, matched family donor; *MMF*, mycophenolate mofetil; *MMFD*, mismatched family donor; *MSD*, matched sibling donor; *MTX*, methotrexate; *MUD*, matched unrelated donor; *ND*, no data or not determined; *PR*, partial remission (moderate residual symptoms, potentially LRBA related, with requirement of immunosuppressive treatment); *SC boost*, stem cell boost; *SCT*, stem cell transplantation; *SCIG*, regular subcutaneous immunoglobulin replacement therapy; *steroids*, glucocorticoids; *T* and *B*, T and B lymphocytes; *TMA*, thrombotic microangiopathy; *TRA*, thrombopoietin receptor agonist treatment; *TRM*, transplant-related mortality; *WT*, wild-type.

*Manuscripts (single patient reports) in preparation (personal communication).

†Decreasing donor chimerism in patient 3 from 95% to 99% donor WBCs with 91% donor T cells (days +30 and +60) to 89% WBCs and 88% $CD3^+$ cells (day +240) and further decreasing to 83% WBC and 84% T-cell chimerism 2 years after HSCT and in patient 9 from 100% donor WBCs on days +30 and +60 to 93% on day +82, which further decreased to 15% WBCs and 31% $CD3^+$ cells on day +430 and down to 7% donor-derived WBCs and 23% CD3+ T cells day +578 at the latest follow-up (as shown).

‡Time point after HSCT.

TABLE I. *(Continued)*

7	8	9	10	11	12
c.3647_3651delCTAA; c.7937T>G	Exon 1-30 deletion	c.2978C>G	c.4522 C>T	c.7937T>G	c.2762G>C
0,1	4	1	3	1	4
Bakhtiar et al[9]	Gámez-Díaz et al[1]	*	*	*	*
X	X	X	X	X	X
X	X	X	X		X
				X	
X			X	X	
			X	X	
	X	X	X		
X			X		
MTX, CSA/FK			CSA/FK		Not specified
X		X	X	X	X
	X	X			
Enteropathy, autoimmunity	Steroid refractory lymphocytic interstitial pneumonia	Severe clinical course, enteropathy, infections, failure to thrive	Refractory CNS lymphoproliferation	Lymphoproliferation	Severe humoral immunodeficiency, intestinal problems, autoimmunity
11	10	3	16	9	10
2010	2012	2015	2015	2016	2009
MSD (het)	MUD (ND)	MFD (WT)	MUD (ND)	MSD (het)	MUD (ND)
X	X	X	X	X	X
		X		X	
			X		
X					
X	X				X
1°-2° (skin)					
			Limited: eye, gut		
	AdV, CMV				
	TMA, AdV viremia, pneumonitis	Post-SCT AIHA		Still requires hematopoietic growth factor support, might need SC boost	Poor engraftment, CMV pneumonitis, Enterobacter and Acinetobacter sepsis
Outcome					
X		X	X	X	
75	(2)	22	9	4	(2)
100 (+3 y)	100 (d+30)	7 WBC, 23 $CD3^+$ (d+578†)	97 WBC, 44 $CD3^+$ (d+180)	100 (d+120)	0 (d+30)
CR	died 2 mo after SCT (TRM)	PR (AIHA; irreversible IDDM after pancreatitis)	CR	GPR (thrombocytopenia, neutropenia, flares of arthritis)	Died 2 mo after SCT (TRM)
None	NA	Abatacept IVIG	None	TRA, GCSF	NA

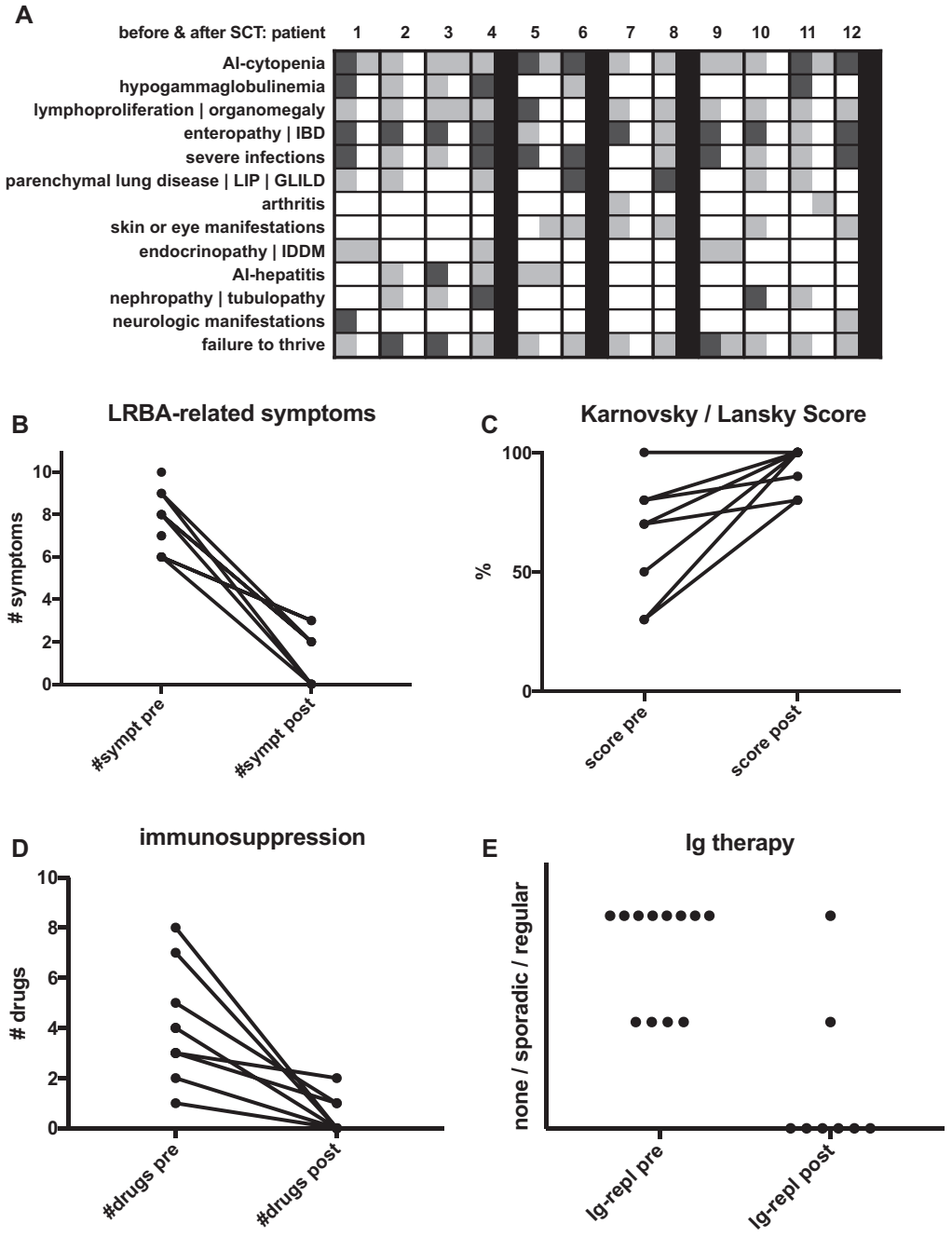

FIG 1. Qualitative and semiquantitative assessment of disease activity of 12 patients with LRBA deficiency before and after HSCT. **A,** A heat map of LRBA-related symptoms is shown, indicating symptom severity in patients before and after HSCT in pairs of columns (*white*, absent; *light gray*, mild to moderate; *dark gray*, severe and considered as HSCT indication; black, deceased patients). **B,** Number of symptoms (as listed in Fig 1, *A*) before and after HSCT. **C,** Karnovsky/Lansky performance scores before and after HSCT. Deceased patients were excluded from the analysis after HSCT. **D,** Number of immunosuppressive drugs used simultaneously or sequentially for treatment of LRBA-related symptoms before and after HSCT. **E,** Immunoglobulin therapy shown as *none (bottom line)*; *sporadic*, indicating use as irregular immunomodulatory treatment *(center level)*; or *regular*, indicating monthly intravenous or weekly subcutaneous replacement therapy *(top)*. *AI*, Autoimmune; *GLILD*, granulomatous-lymphocytic interstitial lung disease; *IBD*, inflammatory bowel disease; *IDDM*, insulin-dependent diabetes mellitus; *LIP*, lymphocytic interstital pneumonitis; *SCT*, stem cell transplantation.

Pediatric Oncology, Hematology and Immunology, Minsk Region, Belarus; [l]the Division of Clinical Immunology, Department of Laboratory Medicine, Karolinska Institutet at Karolinska University Hospital Huddinge, Stockholm, Sweden; and [m]the Institute of Cellular Medicine, Newcastle University, Newcastle upon Tyne, United Kingdom. E-mail: markus.seidel@medunigraz.at.

M.G.S. was funded in part by the Styrian Children's Cancer Aid (Steirische Kinderkrebshilfe). The work was also supported by the BMBF (grant 01EO1303 to S.E. and B.G.).

REFERENCES

1. Gámez-Díaz L, August D, Stepensky P, Revel-Vilk S, Seidel MG, Noriko M, et al. The extended phenotype of LRBA deficiency. Front Immunol 2016;137:223-30.
2. Alkhairy OK, Abolhassani H, Rezaei N, Fang M, Andersen KK, Chavoshzadeh Z, et al. Spectrum of phenotypes associated with mutations in LRBA. J Clin Immunol 2016;36:33-45.
3. Charbonnier LM, Janssen E, Chou J, Ohsumi TK, Keles S, Hsu JT, et al. Regulatory T-cell deficiency and immune dysregulation, polyendocrinopathy, enteropathy, X-linked-like disorder caused by loss-of-function mutations in LRBA. J Allergy Clin Immunol 2015;135:217-27.
4. Lo B, Zhang K, Lu W, Zheng L, Zhang Q, Kanellopoulou C, et al. Autoimmune disease. Patients with LRBA deficiency show CTLA4 loss and immune dysregulation responsive to abatacept therapy. Science 2015;349:436-40.
5. Lopez-Herrera G, Tampella G, Pan-Hammarstrom Q, Herholz P, Trujillo-Vargas CM, Phadwal K, et al. Deleterious mutations in LRBA are associated with a syndrome of immune deficiency and autoimmunity. Am J Hum Genet 2012;90:986-1001.
6. Seidel MG, Hirschmugl T, Gamez-Diaz L, Schwinger W, Serwas N, Deutschmann A, et al. Long-term remission after allogeneic hematopoietic stem cell transplantation in LPS-responsive beige-like anchor (LRBA) deficiency. J Allergy Clin Immunol 2015;135:1384-90.e8.
7. Tesi B, Priftakis P, Lindgren F, Chiang SC, Kartalis N, Lofstedt A, et al. Successful hematopoietic stem cell transplantation in a patient with lps-responsive beige-like anchor (LRBA) gene mutation. J Clin Immunol 2016;36:480-9.
8. Sari S, Dogu F, Hwa V, Haskologlu S, Dauber A, Rosenfeld R, et al. A successful HSCT in a girl with novel LRBA mutation with refractory celiac disease. J Clin Immunol 2016;36:8-11.
9. Bakhtiar S, Gamez-Diaz L, Jarisch A, Soerensen J, Grimbacher B, Belohradsky B, et al. Treatment of infantile inflammatory bowel disease and autoimmunity by allogeneic stem cell transplantation in LPS-responsive beige-like anchor deficiency. Front Immunol 2017;8:52.

Available online May 10, 2017.
https://doi.org/10.1016/j.jaci.2017.04.023

Allergen-specific immunotherapy modulates the balance of circulating Tfh and Tfr cells

To the Editor:

Follicular helper T cells (Tfh cells) are a CD4 T-cell subset specialized in providing help for the development and maintenance of B-cell responses.[1] Tfh cells are essential for germinal center formation and the development of effective humoral immunity.[2] In humans, circulating resting memory Tfh cells are minimally defined as $CD3^+CD4^+CD45RO^+CXCR5^+$.[3] Follicular regulatory T cells (Tfr), a T-cell subset believed to originate from thymic-derived $FOXP3^+$ T-cell precursors, have been shown to regulate and suppress germinal center reactions.[4] Several reports suggest that Tfh cells likely play a role in mediating allergic disease[5,6]; however, there is a lack of human studies of Tfh cell biology in the context of allergy[7,8] and allergen-specific immunotherapy (AIT). Given the critical role of Tfh and Tfr cells in the regulation of IgE production in the context of allergic disease in murine models,[6] we hypothesized that AIT modulates Tfh and/or Tfr cells.

A total of 70 subjects were recruited for this study, including 25 timothy grass allergic patients, 32 patients who received subcutaneous shots of AIT and were in treatment maintenance at the time of blood draw, and 13 nonallergic healthy controls identified as having negative skin prick test results to a panel of 32 allergen extracts and no clinical history of allergy (see Table E1 in this article's Online Repository at www.jacionline.org).

The effect of AIT on Tfh cell frequency was assessed by flow cytometry, quantifying the total peripheral memory Tfh cell population (defined as $CD3^+CD4^+CD45RO^+CXCR5^+$) (Fig 1, *A*). We found a significant reduction in Tfh cells in AIT-treated patients compared with untreated allergic donors (median 6.4% in allergics, 3.5% in AIT-treated patients; $P = .008$; Fig 1, *B*). Reduction in Tfh cells after AIT was also seen compared with nonallergic controls (median, 5.1%) but this difference did not reach statistical significance ($P = .13$; Fig 1, *B*). To verify our manual gating analysis results, we also analyzed the data using a FLOCK-based automated gating strategy, which produced similar results (see Fig E1 in this article's Online Repository at www.jacionline.org).

Given that the reduction in Tfh cells in patients treated with AIT is most prominent in the $CXCR5^{hi}$ subset, we characterized gene expression in $CXCR5^{hi}$ versus $CXCR5^{lo}$ cells in 5 allergic donors with a predominant $CXCR5^{hi}$ Tfh population (Fig 1, *A*, red box) and 5 AIT-treated donors with a predominantly $CXCR5^{lo}$ Tfh population (Fig 1, *A*, blue box). $CXCR5^{hi}$ and $CXCR5^{lo}$ cells were sorted and high-quality RNA (RNA Integrity Number [RIN] > 7.5) was obtained for subsequent transcriptomic analysis. As expected, transcription of CXCR5 was significantly reduced in $CXCR5^{lo}$ cells compared with $CXCR5^{hi}$ cells (Fig 1, *C*). Paired comparisons of $CXCR5^{hi}$ versus $CXCR5^{lo}$ samples identified 26 genes with significantly different expression levels (multiple hypothesis adjusted *P* value <.05; Fig 2, *D*). Examination of the 26 differentially expressed genes revealed that several had known immunological functions, including regulatory activity (*FOXP3, CCR8, LAG3, CD200, LRRC32*, and *CD70*), inflammation (CCL5, LGALS3, and ENC1), cytotoxicity (GZMA), and proliferation (MKI67). Unsupervised hierarchical clustering of samples based on the expression pattern of the 26 genes resulted in separation of $CXCR5^{hi}$ from $CXCR5^{lo}$ cells independent of the AIT status of the donor from which the samples were derived (Fig 2, *E*). Thus, the differences observed are intrinsic properties of $CXCR5^{hi}$ versus $CXCR5^{lo}$ cells and are independent of AIT treatment status.

To determine how the identified differences in mRNA levels between $CXCR5^{hi}$ and $CXCR5^{lo}$ cell populations impacted protein expression, we performed fluorescence-activated cell sorting analyses for proteins from 7 out of the 26 differentially expressed genes, based on antibody availability (Fig 2, *A*). In addition, we included antibodies against Helios because transcription of this gene was borderline significant in our analysis (*P* adjusted = .16; see Table E2 in this article's Online Repository at www.jacionline.org) and Helios has been shown to be important for regulatory T-cell function.[9] Significantly higher expression in $CXCR5^{lo}$ versus $CXCR5^{hi}$ cells was detected for FOXP3, Helios, and Granzyme A. Comparing the frequency of Helios and Granzyme A expression in $CXCR5^{lo}FOXP3^+$ versus $CXCR5^{lo}FOXP3^-$ cells revealed an enrichment of $FOXP3^+Helios^+$ cells, which was significantly higher than $FOXP3^+$Granzyme A^+ cells (median, 7.0 and 0.5, respectively, $P < .0001$) (Fig 2, *B*), suggesting that Helios and FOXP3 are

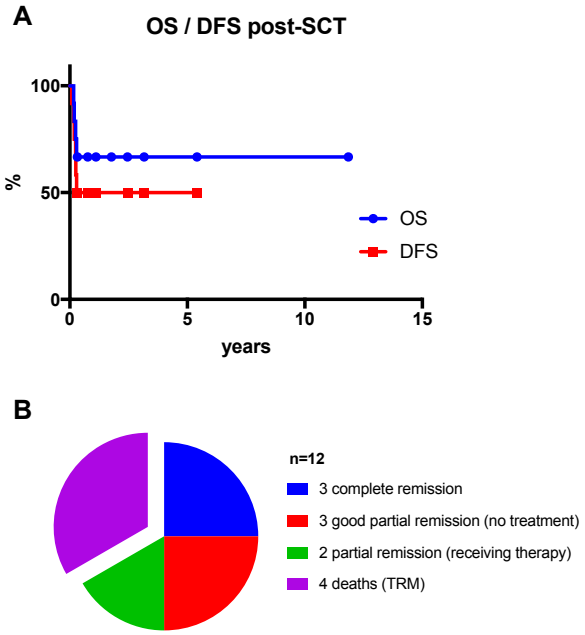

FIG E1. Survival and remission status of 12 patients with LRBA deficiency after allogeneic HSCT. **A,** Kaplan-Meier curves show overall and disease-free survival. **B,** Pie chart indicating outcome and remission status of 12 patients at their last follow-up after HSCT. *DFS*, Disease-free survival; *OS*, overall survival; *TRM*, transplant-related mortality.