# Pediatric Plasmablastic Lymphoma in the Setting of *CD70* Deficiency

*Kubra Baskin, MD,* Ozge Vural, MD,† Sule Haskologlu, MD,‡ Baran Erman, PhD,§‖ Pinar Uyar Gocun, MD,¶ Arzu Okur, MD,† Figen Dogu, MD,‡ Faruk Guclu Pinarli, MD,† and Aydan Ikinciogullari, MD‡*

Downloaded from http://journals.lww.com/jpho-online by BhDMf5ePHKav1zEoum1tQfN4a+kJLhEZgbsIHo4XMi0hCywCX1AWnYQp/IlQrHD3i3D0OdRyi7TvSFl4Cf3VC1y0abggQZXdgGj2MwlZLeI= on 12/24/2024

**Abstract:** Combined immunodeficiency due to *CD70* deficiency is characterized by increased susceptibility to infections, hypogammaglobulinemia, and malignancy. These patients typically present with chronic Epstein Barr virus (EBV) viremia, severe EBV-related hemophagocytic lymphohistiocytosis, lymphoproliferation, and Hodgkin and non-Hodgkin lymphomas. Plasmablastic lymphoma (PBL) is an extremely rare malignancy in all ages and is predominantly seen in male adults with human immunodeficiency virus infection. EBV infection, immunosuppression, solid organ transplantation, and age-related immune deterioration are also suspected causes of PBL. Nevertheless, there is scarce data about its association with primary immunodeficiencies in the literature. Here, we present the first case of a *CD70*-deficient pediatric patient with PBL.

**Key Words:** *CD70* deficiency, pediatric, plasmablastic lymphoma, primary immunodeficiency

(*J Pediatr Hematol Oncol* 2024;46:438–441)

Primary immunodeficiencies (accurately inborn errors of immunity [IEI]) have many aspects and present clinically not only as increased susceptibility to infections, but also as autoimmunity, autoinflammatory diseases, allergy, bone marrow failure, and/or malignancy. Up to date, 485 genetic defects are known to cause IEI.[1] Patients with certain types of IEI, such as germline-inherited loss-of-function mutations in *SH2D1A*, *XIAP*, *ITK*, *MAGT1*, *CTPS1*, *CORO1A*, *RASGRP1*, *STK4*, *CARMIL2*, *TNFRSF9*, *CD27*, or *CD70* are particularly prone to Epstein Barr virus (EBV) infection.[1] *CD70* deficiency was first identified in 2017,[2,3] and since then, different types of lymphomas (eg, Hodgkin lymphoma, non-Hodgkin lymphoma [NHL], unclassified B-cell non-Hodgkin lymphoma (B-NHL), Burkitt lymphoma, and diffuse large B-cell lymphoma) have been reported in these patients.[4] However, plasmablastic lymphoma (PBL) has not yet been reported. Here we report a *CD70* deficient pediatric patient presenting with PBL at diagnosis.

Received for publication June 11, 2024; accepted August 9, 2024.

From the *Department of Pediatric Allergy and Immunology; †Department of Pediatric Oncology; ‡Can Sucak Research Laboratory for Translational Immunology; §Department of Medical Pathology, School of Medicine, Gazi University; ‖Institute of Child Health, Hacettepe University; and ¶Department of Pediatric Allergy and Immunology, School of Medicine, Ankara University, Ankara, Türkiye.

The authors declare no conflict of interest.

Reprints: Kubra Baskin, MD, Department of Pediatric Allergy and Immunology, School of Medicine, Gazi University, Emniyet Mahallesi, Mevlana Bulvarı No: 29 06500 Yenimahalle/Ankara/Türkiye (e-mail: akbaskin@hotmail.com).

Copyright © 2024 Wolters Kluwer Health, Inc. All rights reserved.

DOI: 10.1097/MPH.0000000000002948

## CASE REPORT

A 7-year-old girl was admitted to the emergency department due to stomachache, bloating, loss of appetite, icterus, and confusion. On admission, her clinical status was moderate, with a Glasgow coma scale of 9. She presented with icteric skin and sclera, respiratory distress, and abdominal distension. Physical examination revealed hepatosplenomegaly, generalized lymphadenopathy (left cervical conglomerated and fixed, 5×5 cm-sized, left supraclavicular 2×2 cm-sized, left inguinal and axillary), and a few ecchymotic lesions with edema on the lower extremities. Laboratory tests indicated leucocytosis, thrombocytopenia, hyponatremia, hypoalbuminemia, elevated liver enzymes with direct hyperbilirubinemia, elevated lactate dehydrogenase, uric acid, and international normalized ratio values (Table 1).

After the initial evaluation, she was admitted to the pediatric intensive care unit on suspicion of acute hepatic encephalopathy. It was gathered from her medical history that her complaints lasted for 3 months, and she was evaluated for malignancy. A lymph node biopsy was performed, and atypical lymphoid proliferation was demonstrated. Her parents were third-degree cousins, and there was no family history of primary immunodeficiency. Serological tests for infections (hepatitis A, B, C, D, E, human immunodeficiency virus [HIV], toxoplasmosis, rubella, cytomegalovirus, and parvovirus) were found negative except for EBV (Epstein-Barr virus nuclear antigen IgG and EBV Viral capsid antigen immunoglobulin G were positive). EBV polymerase chain reaction was found to be $19.6\times10^6$ copies. She was treated with vigorous intravenous hydration, allopurinol, vitamin K supplementation, lactulose, and cefotaxime.

The abdominal ultrasound on admission showed hepatosplenomegaly, multiple conglomerate lymphadenopathies around the portal vein, uncinate process of pancreas, splenic hilus, and mesenteric adipose tissue. We thought that these pathologic lymphadenopathies contributed to hepatic dysfunction and hepatosplenomegaly by obstruction. Bone marrow aspiration and biopsy were performed. Bone marrow aspiration revealed >90% locally vacuolated L1-type blasts. Bone marrow biopsy showed diffuse atypical lymphoid cell infiltrates. Immunophenotypical studies proved lymphoid cells with positive expression of CD79a, MUM1, and CD38, negative expression of PAX5 and CD20, and 95% Ki67 expression supporting PBL diagnosis (Figs. 1 and 2). EBV-encoded RNA was diffusely positive in the chromogenic in situ hybridization study. Thoracal and



Copyright © 2024 Wolters Kluwer Health, Inc. All rights reserved.

Downloaded from http://journals.lww.com/jpho-online by BhDMf5ePHKav1zEoum1tQfN4a+kJLhEZgbsIHo4XMi0hCywCX1AWnYQp/IlQrHD3i3D0OdRyi7TvSFl4Cf3VC1y0abggQZXdgGj2MwlZLeI= on 12/24/2024

**TABLE 1.** Admission Laboratory Results

| | |
|---|---|
| Hemoglobin (g/dL) | 11.2 (10.6-13.2) |
| Leukocytes (per μL) | **17300** (4270-11400) |
| Neutrophils (per μL) | 7200 (1640-7870) |
| Lymphocytes (per μL) | **9100** (1160-4280) |
| Platelets (per μL) | **74000** (199000-367000) |
| BUN (mg/dL) | **29** (9-22) |
| Creatinine (mg/dL) | 0.33 (0.29-0.66) |
| Sodium (mEq/L) | **116** (139-146) |
| Potassium (mEq/L) | 5.1 (3.8-5.4) |
| Clor (mEq/L) | **83** (103-112) |
| Albumin (g/dL) | **2.7** (3.4-4.8) |
| Lactate dehydrogenase (UI/L) | **2404** (195-349) |
| Uric acid (mg/dL) | **15.9** (2.2-5.6) |
| AST (U/L) | **747** (27-49) |
| ALT (U/L) | **421** (15-35) |
| GGT (U/L) | **311** (15-35) |
| Total bilirubin, (mg/dL) | **7.3** (0.3-1.2) |
| Direct bilirubin, (mg/dL) | **5.4** (0.1-0.4) |
| PT (sc) | **31.1** (10.5-14.5) |
| INR | **3.01** (0.8-1.2) |
| APTT (sc) | **56.3** (20-30) |

Bold values indicate abnormal laboratory levels.

ALT indicates alanine aminotransferase; APTT, activated partial thromboplastin time; AST, aspartate aminotransferase; GGT, gamma-glutamyltransferase; INR, international normalized ratio; PT, protrombin time; BUN, blood urea nitrogen.

abdominopelvic computed tomography imaging was performed for staging. computed tomography imaging also confirmed hepatosplenomegaly and extensive lymphadenopathies both in the abdomen and thorax.

She was admitted to the pediatric oncology department after a 4-day pediatric intensive care unit hospitalization. The staging work-up for the central nervous system (CNS) was negative. The disease was classified as Murphy stage 4, and she received NHL Berlin-Frankfurt-Münster group protocol. After cytoreductive prephase chemotherapy (consisting of dexamethasone, cyclophosphamide, intrathecal methotrexate/cytarabine/prednisolone), bilirubin levels normalized and she received 3 courses of chemotherapy consisting of dexamethasone, vincristine, cytarabine, etoposide, methotrexate, ifosfamide, doxorubicin, intrathecal methotrexate/cytarabine/prednisolone.

The chemotherapy doses had to be reduced by 25% due to cytopenia and suspected immunodeficiency. After the first cycle of chemotherapy, she experienced neutropenia, fungal pneumonia, and CNS aspergillosis. The patient was consulted by the pediatric immunology department because of a primary diagnosis of PBL, consanguinity, a high EBV viral load, and an unexpected-complicated chemotherapy course. Immunologic work-up under chemotherapy revealed hypogammaglobulinemia, and decreased levels of natural killer cells, B lymphocytes, and B-lymphocyte subsets (switched memory B cells, marginal zone B cells, and naïve B cells), but was not diagnostic (Table 2). She was suspected of having a combined immunodeficiency, and antimicrobial prophylaxis (trimethoprim-sulfamethoxazole, acyclovir, and voriconazole) and intravenous immunoglobulin replacement therapy was started. For genetic examination, whole exome sequencing was performed and showed that the patient had a homozygous missense variant of uncertain significance mutation (c.331A > C) in the *CD70* gene. Unfortunately, progression was observed after the third cycle of chemotherapy, and the bortezomib, cyclophosphamide, doxorubicin, vincristine and prednisone (B-CHOP) (bortezomib, cyclophosphamide, doxorubicin, vincristine, prednisolone) regimen was initiated. After 2 B-CHOP courses, she was relatively better (improving general condition, regression hepatosplenomegaly, and normal blood count). However, after the third course of chemotherapy, her clinical condition rapidly deteriorated. She was treated with broad-spectrum antibiotics with a diagnosis of septicemia, complicating the progressive disease with extensive bone marrow infiltration, but she succumbed to the disease.

## DISCUSSION

Cancer prevalence in patients with IEI is higher than in the general population. Hence, nearly 30% of causative genes participate in tumorigenesis.[5,6] Several hallmarks for cancer are proposed,[5] and profound T-cell lymphopenia or dysfunction are identified as risk factors for cancers related to oncogenic viruses such as Kaposi sarcoma herpes virus, EBV, human papillomavirus, and Merkel cell polyomavirus.[6] *CD27-CD70* axis plays a critical role in T-lymphocyte activation, survival, proliferation, and differentiation, and thereby in EBV immunosurveillance.[4,7] *CD27*/*CD70* deficient patients are susceptible to EBV-related pathologic conditions such as chronic EBV viremia, lymphoproliferation, hemophagocytic lymphohistiocytosis, and lymphomas.[4] The largest series of these patients reported that 60% of patients had lymphoma (eg, Hodgkin lymphoma, NHL, unclassified B-NHL, Burkitt lymphoma, and diffuse B cell lymphoma) at earlier ages.[4]

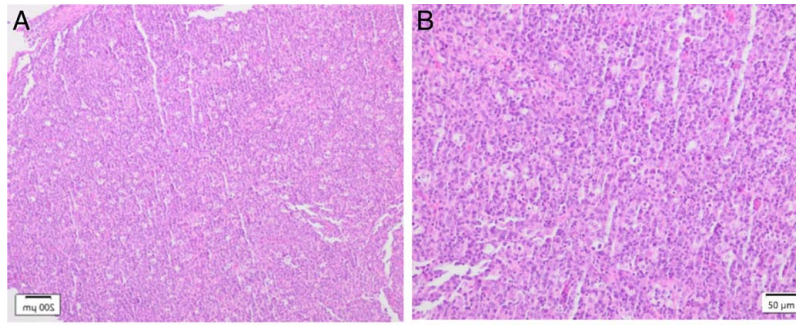


**FIGURE 1.** A and B, the light microscopic section of bone marrow stained with hematoxylin-eosin. full color online

Copyright © 2024 Wolters Kluwer Health, Inc. All rights reserved.


Copyright © 2024 Wolters Kluwer Health, Inc. All rights reserved.

Downloaded from http://journals.lww.com/jpho-online by BhDMf5ePHKav1zEoum1tQfN4a+kJLhEZgbsIHo4XMi0hCywCX1AWnYQp/IlQrHD3i3D0OdRyi7TvSFl4Cf3VC1y0abggQZXdgGj2MwlZLeI= on 12/24/2024

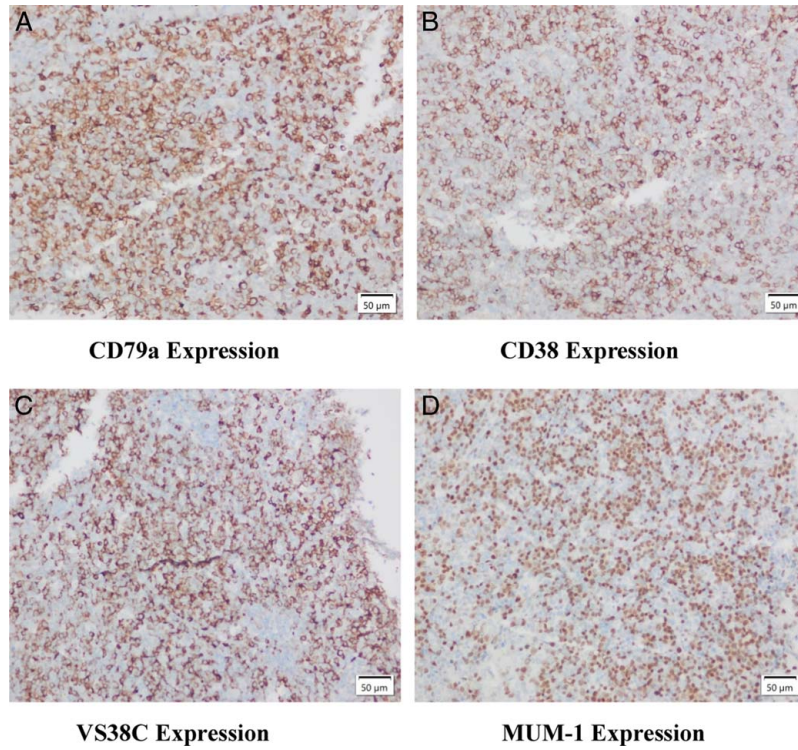


**FIGURE 2.** A–D, Immunophenotypical studies of bone marrow. full color online

**TABLE 2.** The Immunologic Investigations of the Patient (Under Chemotherapy)

| | Patient's value | Age references |
|---|---|---|
| IgG (mg/dL) | **737** | 764-2134 |
| IgA (mg/dL) | **66** | 70-303 |
| IgM (mg/dL) | **50.2** | 69-387 |
| Absolute lymphocyte counts (/mm$^3$) | **1300** | 1500-4280 |
| T.Ig E ( IU/L) | < 20.7 | 161 |
| CD3+T cells (%, /mm$^3$) | 87 | 57-81 |
| | 1131 | 1000-4900 |
| CD3+CD4+ T cells (%, /mm$^3$) | 51 | 24-47 |
| | 663 | 500-2700 |
| CD3+CD8+ T cells (%, /mm$^3$) | 34 | 17-37 |
| | 442 | 300-2100 |
| CD4+CD45RA+ T cells (%, /mm$^3$) | 32 | 17-40 |
| | 416 | 300-2400 |
| CD19+ B cells (%, /mm$^3$) | **5** | 10-27 |
| | **65** | 200-2200 |
| CD3-CD16+CD56+ NK cells (%, /mm$^3$) | **2** | 8-28 |
| | **26** | 200-900 |
| γδ cells (%) | 3 | < 5 |
| CD45RA+CD31+ (%) | **54** | 55-74 |
| CD4/CD8 ratio | 1.5 | 2 |
| Lymphocte activation response to PHA (%) | | |
| CD3+CD25+ | 74 | 48-89 |
| CD3+CD69+ | 72 | 50-76 |
| Lymphocte activation response to anti-CD3(%) | | |
| CD4+CD25+ | 44 | — |
| CD4+CD69+ | 44 | — |
| CD4+ | 45 | — |
| B-lymphocyte subsets (%) | | |
| CD19+IgM+27-IgD+ (naive B) | **36.6** | 47-77 |
| CD19+ IgM-27+ IgD- (switched memory B) | **7** | 10.9-30.4 |
| CD19+CD38$^{Low}$CD21$^{Low}$ (active B) | **39.2** | 2.3-10 |
| CD19+ IgM+27+ IgD+ (marginal zone B) | **2.4** | 5.2-24.7 |

Bold values indicate abnormal laboratory levels.
NK indicates natural killer; PHA, phytohemaglutinin.


Copyright © 2024 Wolters Kluwer Health, Inc. All rights reserved.
Copyright © 2024 Wolters Kluwer Health, Inc. All rights reserved.

Downloaded from http://journals.lww.com/jpho-online by BhDMf5ePHKav1zEoum1tQfN4a+kJLhEZgbsIHo4XMi0hCywCX1AWnYQp/IlQrHD3i3D0OdRyi7TvSFl4Cf3VC1y0abggQZXdgGj2MwlZLeI= on 12/24/2024

PBL is an extremely rare, aggressive NHL.[8] First cases were identified in 1997 as diffuse large B-cell lymphoma of the oral cavity with plasmacytic differentiation, unique immunophenotypic features, and a strong association with HIV and EBV infection.[9] The fifth edition of the World Health Organization classification for hematological and lymphoid cancers identifies PBL as a unique subtype of "large B-cell lymphomas."[10] To date, <1100 cases have been reported, 35 of whom were pediatric.[8] The median age of presentation is late 50s with earlier presentation in HIV-positive patients.[11] There is a male predominance. PBL can be seen in not only HIV-infected patients but in posttransplant settings and geriatric immunocompetent individuals as well.[11] PBL involves most commonly the oral cavity; additional sites, such as the gastrointestinal tract, skin, soft tissue, liver, lung, CNS, lymph nodes, bone marrow, etc, may also be affected.[8,12] Plasmablasts are accepted as the biological origin of PBL.[8] Immunophenotypical studies show that the tumor cells express plasma cells' markers, such as CD38, Vs38c, CD138, and IRF4/MUM1.[8,11,12] Most of the HIV-negative patients are reported to have a Ki-67 index higher than 80%.[12] JAK-STAT, RAS-RAF, NOTCH, IRF4, and MYC signaling pathways are suspected in the molecular pathogenesis of PBL.[13]

The literature is lacking in information about the underlying primary immunodeficiency. A recent study assessing 281 adult patients with PBL revealed that immunodeficiency of any kind (except primary immunodeficiency, personal communication, Di Ciaccio et al[14]) was identified in 51% of individuals. Only 3 patients with primary immunodeficiency (a patient with adenosine deaminase-deficient severe combined immunodeficiency, a patient with activated phosphoinositide 3-kinase δ syndrome, and a patient with probable common variable immunodeficiency) were reported to have PBL.[15–17] To the best of our knowledge, this is the first report of PBL in a *CD70*-deficient patient.

There is no standard of care for patients with PBL. Although PBL was considered a rare subtype of aggressive B-NHL and patients were widely treated with B-NHL chemotherapy protocols, the tumor does not express B-cell markers. However, cyclophosphamide, doxorubicin, vincristine and prednisone (cyclophosphamide, doxorubicin, vincristine, and prednisone) is considered inadequate therapy, and more intensive regimens are recommended despite the underlying immunodeficiency in most patients.[18] Bortezomib, a proteasome inhibitor, has shown promising activity both in adults and children against lymphoid malignancies, usually in combination with other chemotherapy protocols.[19,20] We preferred a BMZ-containing regimen for second-series chemotherapy. Although we obtained an initial response, a rapid progression of the disease complicated with neutropenic sepsis led to a dismal outcome.

Patients with PBL, unfortunately, have unfavorable outcomes.[8,11,12] While the earliest studies revealed median survival between 8 and 15 months, recent studies revealed enhanced survival rates ranging from 32 to 47 months.[8] Pediatric patients has also poor prognosis; hence, most patients present with advanced stages.[8]

## CONCLUSION

Primary immunodeficiencies should be considered in the presence of consanguinity, high EBV viral load, and rare malignancies with complicated course. The underlying disease causes extra difficulties in the cancer treatment in these patients. The paucity of pediatric PBL cases is an obstacle to developing treatment strategies.

## REFERENCES


1. Tangye SG, Al-Herz W, Bousfiha A, et al. Human inborn errors of immunity: 2022 update on the classification from the International Union of Immunological Societies Expert Committee. *J Clin Immunol*. 2022;42:1473–1507.
2. Izawa K, Martin E, Soudais C, et al. Inherited CD70 deficiency in humans reveals a critical role for the CD70-CD27 pathway in immunity to Epstein-Barr virus infection. *J Exp Med*. 2017;214:73–89.
3. Abolhassani H, Edwards ES, Ikinciogullari A, et al. Combined immunodeficiency and Epstein-Barr virus-induced B cell malignancy in humans with inherited CD70 deficiency. *J Exp Med*. 2017;214:91–106.
4. Ghosh S, Köstel Bal S, Edwards ESJ, et al. Extended clinical and immunological phenotype, and transplant outcome in CD27 and CD70 deficiency. *Blood*. 2020;136:2638–2655.
5. Wang Y, Abolhassani H. Updates of cancer hallmarks in patients with inborn errors of immunity. *Curr Opin Allergy Clin Immunol*. 2022;22:352–363.
6. Pai SY, Lurain K, Yarchoan R. How immunodeficiency can lead to malignancy. *Hematology Am Soc Hematol Educ Program*. 2021;2021:287–295.
7. Gennery AR. CD27-CD70 defects: a wolf in wolf's clothing? *Blood*. 2020;136:2600–2602.
8. Bibas M. Plasmablastic lymphoma. A state-of-the-art review: part 1-epidemiology, pathogenesis, clinicopathologic characteristics, differential diagnosis, prognostic factors, and special populations. *Mediterr J Hematol Infect Dis*. 2024;16:e2024007.
9. Delecluse HJ, Anagnostopoulos I, Dallenbach F, et al. Plasmablastic lymphomas of the oral cavity: a new entity associated with the human immunodeficiency virus infection. *Blood*. 1997;89:1413–1420.
10. Alaggio R, Amador C, Anagnostopoulos I, et al. The 5th edition of the World Health Organization Classification of Haematolymphoid Tumours: Lymphoid Neoplasms. *Leukemia*. 2022;36:1720–1748; [published correction appears in Leukemia. 2023;37(9):1944-1951].
11. Kaur S, Kollimuttathuillam S. Plasmablastic lymphoma: past, present, and future. *Clin Lymphoma Myeloma Leuk*. 2023;23:e253–e259.
12. Li JW, Peng HL, Zhou XY, et al. Plasmablastic lymphoma: current knowledge and future directions. *Front Immunol*. 2024;15:1354604.
13. Frontzek F, Hailfinger S, Lenz G. Plasmablastic lymphoma: from genetics to treatment. *Leuk Lymphoma*. 2023;64:799–807.
14. Di Ciaccio PR, Polizzotto MN, Cwynarski K, et al. The influence of immunodeficiency, disease features, and patient characteristics on survival in plasmablastic lymphoma. *Blood*. 2024;143:152–165.
15. Migliavacca M, Assanelli A, Ponzoni M, et al. First occurrence of plasmablastic lymphoma in adenosine deaminase-deficient severe combined immunodeficiency disease patient and review of the literature. *Front Immunol*. 2018;9:113.
16. Yin Z, Tian X, Zou R, et al. Case report: first occurrence of plasmablastic lymphoma in activated phosphoinositide 3-kinase δ syndrome. *Front Immunol*. 2021;12:813261.
17. Yaqoob N, Anis S, Mansoor N, et al. Plasmablastic lymphoma in a human immunodeficiency virus-positive child with a suspicion of concomitant primary immunodeficiency disorder. *J Pediatr Hematol Oncol*. 2023;45:e931–e935.
18. Castillo JJ, Bibas M, Miranda RN. The biology and treatment of plasmablastic lymphoma. *Blood*. 2015;125:2323–2330.
19. Sabry W, Wu Y, Kodad SG. Bortezomib, lenalidomide, and dexamethasone combination induced complete remission in relapsed/refractory plasmablastic lymphoma: case report of a potential novel treatment approach. *Curr Oncol*. 2022;29:5042–5053.
20. Hasegawa D, Yoshimoto Y, Kimura S, et al. Bortezomib-containing therapy in Japanese children with relapsed acute lymphoblastic leukemia. *Int J Hematol*. 2019;110:627–634.


*Copyright © 2024 Wolters Kluwer Health, Inc. All rights reserved.*


Copyright © 2024 Wolters Kluwer Health, Inc. All rights reserved.