Histological assessment of root cementum at periodontally healthy and diseased human teeth

Emel Ökte*, Berrin Ünsal*, Belgin Bal*, Esra Erdemli† and Anil Akbay*

*Department of Periodontology, Faculty of Dentistry, Gazi University, Ankara, Türkiye
†Department of Histology and Embryology, Faculty of Medicine, Ankara University, Ankara, Turkey

(Received 24 March and accepted 16 November 1999)

Abstract: This study aimed to investigate and compare the lipid and polysaccharide content of the cemental surfaces of healthy and periodontally-involved teeth. Thirty periodontally-involved single-rooted teeth from fifteen patients with localized juvenile, adult and rapidly progressive periodontitis were included in the experimental group and 5 healthy teeth were assessed in the control group. Frozen serial sections were obtained and stained with hematoxylin-eosin for morphological assessment. Oil-Red-O and Alcian Blue-Periodic Acid Schiff stains were used to evaluate the presence of lipids, neutral and acidic polysaccharides using light microscopy. It was found that with hematoxylin-eosin staining in the experimental group, both the involved and uninvolved cementum surfaces of teeth, which belong to all periodontitis groups, showed generally irregular surfaces that contain some resorption areas. Alcian Blue-Periodic Acid Schiff positive staining was observed only superficially and at the areas associated with microbial dental plaque. However, Oil-Red-O staining was positive only superficially at 5 teeth that belonged to localized juvenile and rapidly progressive periodontitis groups. Apparent lipopolysaccharide staining into cementum was not seen in any of the diseased teeth. The results presented here suggest that endotoxin was only localized in superficial layers and associated with only microbial colonization. (J. Oral Sci., 41, 177-180, 1999)

Key words: periodontal diseases; cementum; histology.

Introduction

The cementum, which is continuously deposited and rarely remodeled, is an important component of periodontium and also contains various proteins which facilitate cell migration, attachment, differentiation and proliferation (1-3). Progression of plaque-induced chronic inflammatory periodontal disease leads to continuous loss of periodontal attachment and exposure of the root cementum to the oral environment. When the exposed cementum comes into intimate contact with microbial dental plaque, changes occur in the diseased cementum including hypermineralization of the cemental surface, degeneration of the collagen matrix, and presence of resorption lacunae due to penetration and/or absorption of endotoxin at the exposed cementum (4-9).

Endotoxins can also have etiologic significance in periodontal disease. The presence of cytotoxic products of bacterial origin, especially endotoxin which is a lipopolysaccharide (LPS) component of the cell wall of gram negative bacteria, was shown in varying degrees within the cementum by Limulus Amoebocyte Lysate (LAL) assay studies (10-16). In these studies, great variation of the amount and penetration depth of endotoxin was found. Therefore different treatment modalities such as superficial cemental curettage (11,12,16), excessive or deep removal of the diseased cementum (10,14), or even polishing (15) were suggested. As a result, the management of cemental tissue proximal to periodontal pockets has been and continues to be controversial (17).

Releasing of the cytotoxic factors from diseased root surfaces were also investigated by *in vitro* tissue culture studies. A group of these studies showed that releasing of the toxic factors by the diseased root surface led to irreversible cellular changes. It has therefore been recommended that, besides the removal of the bacterial deposits, periodontal treatment should also include the excessive removal of exposed cementum in order to achieve a root surface free of bacterial contamination (18,19).

On the other hand, other *in vitro* culture studies have shown no differences in patterns of cell growth, migration or cytotoxic reaction between root planed and non-root planed areas (6,20). Also, such studies demonstrated that cells can successfully attach to diseased cementum and suggested that the great amount of entodoxin was only superficially located at the diseased cementum (7,21).

According to these controversial studies, most of which evaluated adult periodontitis groups, it is still unclear whether or not endotoxin penetrates into deeper cementum or how much, if any, cementum should be removed. Thus, the aim of this present investigation was to histologically establish the presence and location of lipid and polysaccharide in the diseased cementum of localized juvenile (LJP), rapidly progressive (RPP) and adult periodontitis (AP) patients as compared with healthy cementum.

Corresponse to Dr. Emel Ökte, Gazi Üniversitesi, Dis Hekimligi Fakültesi, Periodontoloji Anabilim Dali, Biskek Caddesi, 82.sokak, 06510, Emek, Ankara, Türkiye.

Materials and Methods

For this study, thirty periodontally-involved single-rooted, vital human teeth, from 15 LJP, RPP and APP patients were included in the experimental group, and 5 healthy teeth extracted for orthodontic reasons were included in the control group, leading to a total of 35 teeth. In periodontally-involved teeth, probing depths ranged from 7 to 9 mm and they had neither a history of scaling and root planing in the last 12 months nor periodontal surgery within 24 months. Both experimental and control teeth did not possessed caries or restorations. The patients from both groups were generally healthy and had not received any antibiotics during the past 6 months. Before extractions, a notch was made at the level of the gingival margin. During extractions, care was taken to avoid excess instrumentation to root surfaces. Involved and uninvolved portions of the roots were demarcated in order to compare each experimental tooth with its healthy part. Extracted teeth were fixed for 48 h in 10% formol-saline solution and demineralization was completed in EDTA (pH 7). Frozen serial sections, 7 μm thick, were cut in bucco-lingual direction parallel to the long axis of each root and stained with hematoxylin-eosin (HE), Alcian Blue-Periodic Acid Schiff (AB-PAS), and Oil-Red-O stains. Neutral and acidic polysaccharide was evaluated by using the AB-PAS staining procedure. By this method, neutral polysaccharides showed PAS positive, whereas acidic polysaccharide stained Alcian Blue positive. To detect for the presence of lipids, sections were stained using the Oil-Red-O procedure.

Results

The cementum of the control teeth displayed a smooth and regular surface with healthy periodontal ligament fibers as shown in Fig. 1A, whereas teeth which belong to the adult periodontitis group had a generally rough and irregular cementum surface with some resorption lacunae (Fig. 1B). The specimens which belong to the LJP and RPP groups also exhibited an irregular cementum surface, but with more instances of resorption lacunae. Also, as can be observed in Fig. 1C, the most coronal exposed parts of the root were devoid of cementum and were covered with deposits of microorganisms.

As seen in Fig. 2A, the cementum of the control teeth with healthy periodontal ligament fibers appeared more PAS-positive than adjacent dentin.

Involved root surfaces of nearly all the specimens within the periodontitis groups were frequently found to be covered with bacterial plaque, which was both AB and PAS positively stained. For the LJP group, in areas where the cemental surface was preserved, superficial PAS positive staining was distinguished partially (Fig. 2B).

The cementum of the control teeth did not show any positive staining demonstrating the presence of lipid (Fig. 3A).

Two of the specimens in the LJP group revealed positive granular and superficial lipid staining in some of the resorptive cemental areas, which can be observed in Fig. 4B, whereas specimens which belong to the AP group did not show any positive staining (Fig. 3B). In the RPP group, granular positive lipid staining was distinguished in the microbial dental plaque which covered the cemental surfaces of 3 teeth (Fig. 4A).

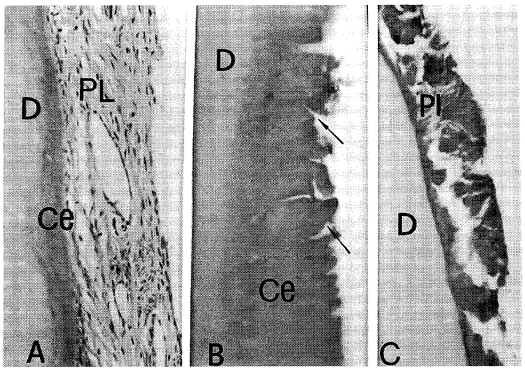

Fig. 1 A. Smooth and regular cementum (Ce) surface of the control teeth with healthy periodontal ligament (PL) fibers (HE × 50). B. Involved cementum (Ce) in adult periodontitis group, showing rough and irregular cementum surface with resorption lacunae (arrows) (HE × 100). C. The most coronal exposed root portion in the RPP group which is devoid of cementum (Ce), with overlying microbial dental plaque (Pl) (D: Dentin) (HE × 50).

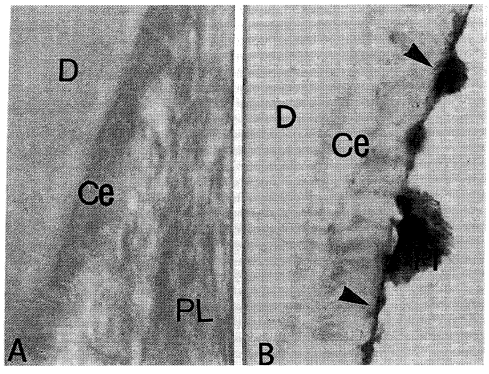

Fig. 2 A. In general the control teeth cementum (Ce) appeared more PAS positive when compared to dentin (D) (PL: Periodontal ligament) (AB-PAS × 250). B. Superficial PAS-positive staining (arrowheads) observed within the involved cementum (Ce) of the LJP group, which was covered with both AB and PAS-positive stained microbial dental plaque (Pl) (D: Dentin) (AB-PAS × 250).

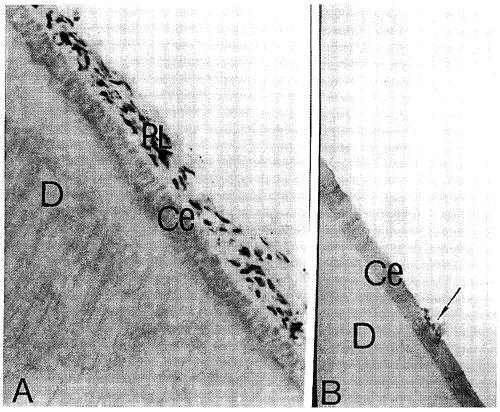

Fig. 3 A. Healthy cementum (Ce) in the control teeth without any positive staining for the presence of lipid (PL: Periodontal ligament) (Oil-Red-O × 100). B. Absence of lipid granules, even beneath the resorption area (arrow) of cementum (Ce) in the AP group (D: Dentin) (Oil-Red-O × 25).

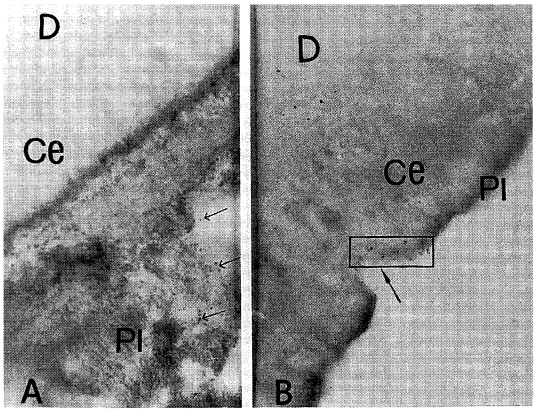

Fig. 4 A. Appearance of granular positive Oil-Red-O staining (open arrows) in the microbial dental plaque (Pl), covering the cemental (Ce) surface of a specimen which belong to the RPP group (Oil-Red-O × 250). B. Beneath the resorption area (arrow) of cementum (Ce) superficial Oil-Red-O granular lipid staining (inset) in the specimen of LJP group (D: Dentin) (Oil-Red-O × 250).

Discussion

Endotoxins, which affect tissues directly or through activation of host responses, were previously termed as lipopolysaccharide (LPS) and today are defined as lipo-oligosaccharide (LOS). Most of the toxic properties of the molecule are caused by the lipid moiety, while the polysaccharide portion is responsible for immunological specificity (22). It is unclear how deeper endotoxin penetrates into cementum, and this penetration depth directly effects the amount of cementum which will be removed during periodontal treatment. Due to the importance of knowing the optimum amount of cementum to be removed, in our study we aimed to comparatively investigate the presence of lipid and polysaccharide in the cementum tissues which were involved or uninvolved by periodontal diseases.

With the HE staining, all root surfaces affected by the periodontal disease, especially in the LJP and RPP groups, showed irregular and rough cementum structures involving resorption areas.

With the AB-PAS staining, although AB and PAS positive superficial staining was seen on the microbial dental plaque of the experimental teeth in LJP groups, PAS positive staining was more apparent. Daly et al. (5) observed the superficial penetration of lipid and polysaccharides in the cementum in their study and because in some cases microbial invasion was seen down to the level of the cemento-dentinal junction, they reported that the whole diseased cementum should be removed during root planing. In our study, involved cementum displayed a superficial and localized PAS positive appearance, especially in the areas that were covered with microbial dental plaque. Positive staining of the root surfaces may have involved factors such as the presence or thickness of cementum and the destruction level due to the duration of the disease. It is known that most of the toxic properties of the molecule are caused by the lipid moiety; therefore, PAS positive staining may not always show the toxicity (22).

Overlying microbial dental plaque of cemental surfaces, Oil-Red-O stained granules of lipid appearance were observed in only 5 of the experimental teeth which belong to the LJP and the RPP groups. Similarly, Daly et al. (5) observed positive lipid staining in only one involved specimen in their study.

The results presented in our study suggest that the periodontally-involved cementum showed no distinct lipid or polysaccharide staining. Our results are in accordance with the recent studies that used LAL assays (11,12,15,16). Moore et al. (15) have shown that the LPS on periodontally-involved root surfaces is associated with loosely attached surface deposits, since 39% could be removed by gentle washing and a further 60% by gentle brushing for one minute. They concluded that effective root surface debridement may be achieved by methods other than traditional hand instrumentation. They further assert that such LPS can be removed even by polishing, where minute residual amounts of it are either tolerated or neutralized by local host defenses. Similarly, Chiew et al. (12) and Cheetham et al. (11) demonstrated that LPS was only superficially adherent onto periodontally-involved root surfaces and, therefore, suggested that extensive root planing may not be warranted. Smart et al. (16) also found that the LPS levels of diseased teeth were comparable to the LPS levels found on healthy, uninvolved control teeth. Nakib et al. (21) demonstrated that LPS is only weakly bound to the root surface and can readily be brushed away.

In an attempt to elicit a local Schwartzman phenomenon, Ito et al. (7) concluded that only extremely small amounts of endotoxin were present in periodontally-involved cementum and also questioned whether the extracted substance was actually endotoxin.

Newman et al. (23) suggested that during root planing, the excessive removal of the root cementum for the purpose of eliminating endotoxins which are possibly present within the cementum is not necessary for accomplishing periodontal health. Furthermore, their histometric data demonstrated that

the result of healing was similar whether the previously exposed root cementum had been removed or not. In their tissue culture study, Fukasawa et al. (6) suggested that improved cellular attachment can be promoted on areas of root surfaces previously damaged by periodontitis if superficial cementum is first removed by mechanical curettage.

In summary, these studies have produced results that suggest that the role of traditional root surface management needs to be reassessed. Results of this study also show the superficial presence of endotoxin in the diseased cementum and therefore is consistent with the previous studies. Further studies are needed to determine the therapeutic implication of the cementum with root planing or chemical treatment in order to achieve an available root surface for healthy attachment. In this study, endotoxin was a weakly adherent surface phenemonon in all periodontally-involved root surfaces, independent of different periodontal disease groups. According to our results, removal of unattached and weakly attached microbial dental plaque and subgingival calculus may be the goal of the periodontal therapy, instead of the total removal of the periodontally-involved cementum.

References

1. Ishikawa, I., Oda, S., Hayashi, J. and Arakawa, S. (1996) Cervical cemental tears in older patients with adult periodontitis. Case reports. J. Periodontol. 67, 15-20
2. McAllister, B., Narayanan, A.S., Miki, Y. and Page, R.C. (1990) Isolation of a fibroblast attachment protein from cementum. J. Periodontal Res. 25, 99-105
3. Somerman, M.J., Sauk, J.J., Foster, R.A., Norris, K., Dickerson, K. and Argraves, W.S. (1991) Cell attachment activity of cementum: bone sialoprotein II identified in cementum. J. Periodontal Res. 26, 10-16
4. Corbet, E.F., Vaughan, A.J. and Kieser, J.B. (1993) The periodontally-involved root surface. J. Clin. Periodontol. 20, 402-410
5. Daly, C.G., Seymour, G.J., Kieser, J.B. and Corbet, E.F. (1982) Histological assessment of periodontally involved cementum. J. Clin. Periodontol. 9, 266-274
6. Fukazawa, E. and Nishimura, K. (1994) Superficial cemental curettage: its efficiacy in promoting improved cellular attachment on human root surfaces previously damaged by periodontitis. J. Periodontol. 65, 168-176
7. Ito, K., Hindman, R.E., O'Leary, T.J. and Kafrawy, A.H. (1985) Determination of the presence of root-bound endotoxin using the local Schwartzman phenomenon (LSP). J. Periodontol. 56, 8-17
8. Nightingale, S.H. and Sheridan, P.J. (1982) Root surface demineralization in periodontal therapy: subject review. J. Periodontol. 53, 611-616
9. Ökte, E., Bal, B., Doğan, B., Ünsal, B. and Baloş, K. (1996) A scanning electron microscopic evaluation of cemental changes in different types of periodontal disease. J. Dental Faculty of Atatürk Univ. 6, 52-58
10. Aleo, J.J., De Renzis, F.A., Farber, P.A. and Varboncoeur, A.P. (1974) The presence and biologic activity of cementum-bound endotoxin. J. Periodontol. 45, 672-675
11. Cheetham, W.A., Wilson, M. and Kieser, J.B. (1988) Root surface debridement -an in vitro assessment. J. Clin. Periodontol. 15, 288-292
12. Chiew, S.Y., Wilson, M., Davies, E.H. and Kieser, J.B. (1991) Assessment of ultrasonic debridement of calculus-associated periodontally-involved root surfaces by the limulus amoebocyte lysate assay. An in vitro study. J. Clin. Periodontol. 18, 240-244
13. Maidwell-Smith, M., Wilson, M. and Kieser, J.B. (1987) Lipopolysaccharide (endotoxin) from individual periodontally involved teeth. J. Clin. Periodontol. 14, 453-456
14. McCoy, S.A., Creamer, H.R., Kawanami, M. and Adams, D.F. (1987) The concentration of lipopolysaccharide on individual root surfaces at varying times following in vivo root planing. J. Periodontol. 58, 393-399
15. Moore, J., Wilson, M. and Kieser, J.B. (1986) The distribution of bacterial lipopolysaccharide (endotoxin) in relation to periodontally involved root surfaces. J. Clin. Periodontol. 13, 748-751
16. Smart, G.J., Wilson, M., Davies, E.H. and Kieser, J.B. (1990) The assessment of ultrasonic root surface debridement by determination of residual endotoxin levels. J. Clin. Periodontol. 17, 174-178
17. Drisko, C.H. (1998) Root instrumentation. Power-driven versus manual scalers, which one? Dent. Clin. North Am. 42, 229-244
18. Jones, W.A. and O'Leary, T.J. (1978) The effectiveness of in vivo root planing in removing bacterial endotoxin from the roots of periodontally involved teeth. J. Periodontol. 49, 337-342
19. Olson, R.H., Adams, D.F. and Layman, D.L. (1985) Inhibitory effect of periodontally diseased root extracts on the growth of human gingival fibroblasts. J.Periodontol. 56, 592-596
20. Adelson, L.J., Hanks, C.T., Ramfjord, S.P. and Caffesse, R.G. (1980) In vitro cytotoxicity of periodontally diseased root surfaces. J. Periodontol. 51, 700-704
21. Nakib, N.M., Bissada, N.F., Simmelink, J.W. and Goldstine, S.N. (1982) Endotoxin penetration into root cementum of periodontally healthy and diseased human teeth. J. Periodontol. 53, 368-378
22. Hammond, B.F. (1992) Major bacterial diseases. In Contemporary oral microbiology and immunology. Slots, J. and Taubman, M.A. eds., Mosby-Year Book, St. Louis, 169-170
23. Nyman, S., Sarhed, G., Ericsson, I., Gottlow, J. and Karring, T. (1986) Role of "diseased" root cementum in healing following treatment of periodontal disease. An experimental study in the dog. J. Periodontal Res. 21, 496-503