Letter

Advance Publication DOI: 10.5582/irdr.2021.01034

Mild congenital myopathy due to a novel variation in *SPEG* gene

Mirac Yildirim[1,*], Ozgur Balasar[2], Engin Kose[3], Melih Timucin Dogan[4]

[1] Department of Pediatric Neurology, Ankara University Faculty of Medicine, Ankara, Turkey;
[2] Department of Medical Genetics, Konya Research and Training Hospital, Konya, Turkey;
[3] Department of Pediatric Metabolism and Nutrition, Ankara University Faculty of Medicine, Ankara, Turkey;
[4] Department of Pediatric Cardiology, Konya Research and Training Hospital, Konya, Turkey.

SUMMARY Centronuclear myopathies (CNMs) are a subgroup of congenital myopathies (CMs) characterized by muscle weakness, genetic heterogeneity, and predominant type 1 fibers and increased central nuclei in muscle biopsy. Mutations in CNM-causing genes such as *MTM1*, *DNM2*, *BIN1*, *RYR1*, *CACNA1S*, *TTN*, and extraordinary rarely *SPEG* (striated muscle preferentially expressed protein kinase) have been identified for about 60-80% of patients. Herein, we report a case of CM due to a novel variation in the *SPEG* gene, manifested by mild neonatal hypotonia, muscle weakness, delayed motor milestones, and ophthalmoplegia, without dilated cardiomyopathy. We identified a novel variation [c.153C>T (p.Asn51=) in exon 1] in the *SPEG* gene with whole-exome sequencing and confirmed by Sanger sequencing. Mild intellectual disability has not been associated with SPEG-related CM in the previous reports. We suggest that this report expands the phenotypic spectrum of SPEG-related CM, and further case reports are required to expand the genotype-phenotype correlations.

Keywords congenital myopathy, striated muscle preferentially expressed protein kinase, SPEG, centronuclear myopathy, intellectual disability

Congenital myopathies (CMs) are a heterogeneous group of muscle diseases usually characterized by muscle weakness and hypotonia at birth or in infancy. The severity of clinical presentation ranges from mild hypotonia due to delayed motor skills to severe muscle weakness that causes death due to cardiac or respiratory involvement in the neonatal period (*1*).

Centronuclear myopathies (CNMs) are a subgroup of CMs. The histological manifestations include an increase in the number of fibers with central nuclei and the predominance of type I fibers (*2*). Mutations in genes such as *MTM1*, *DNM2*, *BIN1*, *RYR1*, *CACNA1S*, and *TTN* have been identified for about 60-80% of patients with CNM. In recent studies, the mutations in the *SPEG* gene (striated muscle preferentially expressed protein kinase) have been associated with CNM in a small case series (*3-7*). Herein, we report a case of CM due to a novel variation in the *SPEG* gene, which is manifested by intellectual disability, a new clinical finding.

We present a case of 7-year-old boy who presented with motor developmental delay. He was born after uneventful pregnancy and delivery, with third-degree consanguineous marriage of his parents. There was a family history with three siblings (two girls and a boy) death with similar severe phenotypic characteristics (Figure 1A). At birth, he had mild hypotonia without respiratory distress or swallowing difficulty. The motor milestones were delayed, head control developed at 1-year-old, and unsupported sitting at 2-year-old. He has never been able to walk with or without support. Social and language skills were mildly delayed.

According to the findings of physical examination at 7-year-old, his weight, height, and head circumference were between the 3rd and 10th percentile. He had a high arched palate, facial weakness, nasal speech, episodic weak cough, pectus excavatum, mild scoliosis, pes planovalgus, vertical supranuclear ophthalmoplegia, globally absent deep tendon reflexes, axial hypotonia, and contracture of bilateral ankles (Figure 1B). His maximum muscle strength was sitting without support. He had mild intellectual disability [intelligence quotient (IQ) test score was 55].

In laboratory tests, serum creatine kinase (CK) levels were mildly elevated (240 and 252 UI/L; reference range: 0-170 UI/L). Plasma and urine amino acids, tandem mass spectrometry, and urine organic acids were unremarkable. Liver and renal function tests and blood gases analysis were normal. At 5-year, 6-month-old, brain MRI and abdominal ultrasound findings were unremarkable. At 7-year-old, electrocardiogram and echocardiogram were normal (ejection fraction:

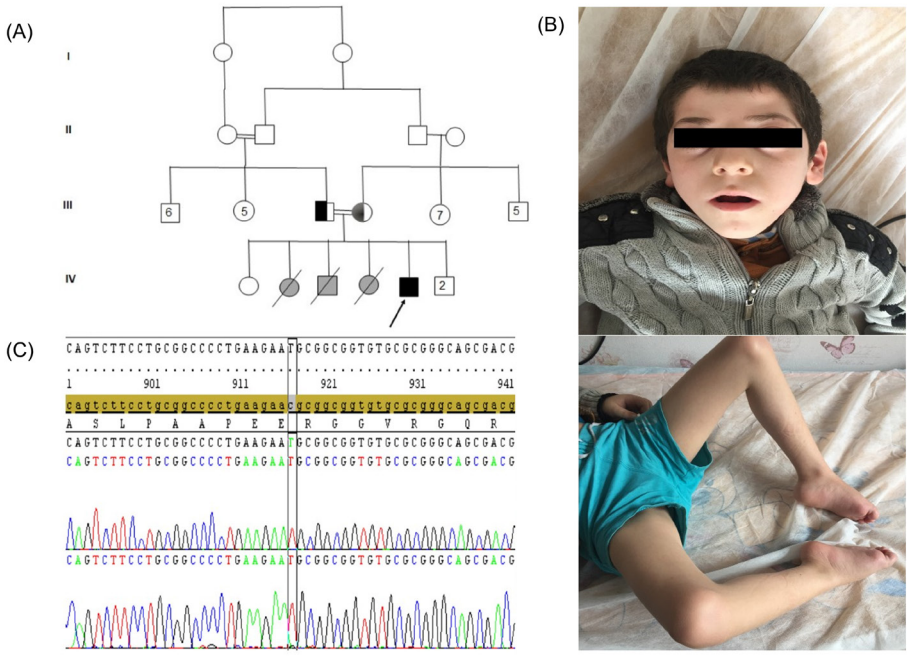

Figure 1. (A) Pedigree of the family; **(B)** Physical examination of patient; **(C)** Sequencing of SPEG variant c.153C>T with Sanger sequencing. Informed consent for genetic analysis and publication of clinical reports and photographs were obtained from patient's parents.

65%, shortening fraction: 32%). The ophthalmological evaluation revealed external ophthalmoplegia. Whole-exome sequencing was performed as the parents did not consent to the muscle biopsy. We identified a novel homozygous variation of c.153C>T (p.Asn51=) in exon 1 of the *SPEG* gene, and the variant was confirmed by Sanger sequencing (Figure 1C).

To date, in the majority of patients with *SPEG* mutations were reported with neonatal hypotonia, muscle weakness, delayed motor milestones, facial weakness, ophthalmoplegia, respiratory support or nasogastric tube feeding requirement, and dilated cardiomyopathy (*4-7*). Consistent with the previously reported cases, our case presented with neonatal hypotonia, delayed motor milestones, intellectual disability, muscle weakness, scoliosis, pes planovalgus, pectus excavatum, and ophthalmoplegia. However, dilated cardiomyopathy, which was reported in most of the cases with *SPEG* mutation, was not present in our case. Similarly, cases with *SPEG* gene mutations present with milder clinical features and delayed motor milestones without dilated cardiomyopathy were recently reported (*3,8*). The present patient is the third case in the literature who did not develop dilated cardiomyopathy despite reaching the age of 7. We believe that more reports of cases with *SPEG* gene mutation will lead us to better understand the clinical variation of the disease and its genotype-phenotype correlation.

One of the major pathogenic pathways of *SPEG* function is the interaction with *MTM1*. The region in the C-terminal of the *SPEG* gene (amino acid 2530-2674) is required for *MTM1* interaction (*5*). In the literature, it was found that *SPEG* mutations leading to loss of interaction between *MTM1* and C-terminal were associated with more severe phenotypes such as death in the neonatal period and dilated cardiomyopathy (*4,5*). Although presenting with mild neonatal hypotonia and delayed motor milestones, the present case was able to sit unsupported at two years of age, did not require ventilatory support or nasogastric tube feeding, and did not develop dilated cardiomyopathy. We suggest that our case had a milder clinical phenotype because of having a novel homozygous variation outside of C-terminal in the *SPEG* gene. However, we did not perform a muscle biopsy to investigate whether central nuclei were present.

To conclude, in previous reports, mild intellectual disability and elevation of CK levels have been associated with other CM subgroups, but not with SPEG-related CM (*1-3,8*). Our case expands the phenotypic spectrum, and we suggest that SPEG-related CM can be associated with mild phenotypes with intellectual disability. Further case reports on SPEG-related CM are required to expand the genotype-phenotype correlations.

Funding: None.

Conflict of Interest: The authors have no conflicts of interest to disclose.

References

1. Nance JR, Dowling JJ, Gibbs EM, Bönnemann CG. Congenital myopathies: an update. Curr Neurol Neurosci Rep. 2012; 12:165-174.

2. Romero NB, Bitoun M. Centronuclear myopathies. Semin Pediatr Neurol. 2011; 18:250-256.
3. Qualls AE, Donkervoort S, Herkert JC, D'gama AM, Bharucha-Goebel D, Collins J, Chao KR, Foley AR, Schoots MH, Jongbloed JDH, Bönnemann CG, Agrawal PB. Novel *SPEG* mutations in congenital myopathies: Genotype-phenotype correlations. Muscle Nerve. 2019; 59:357-362.
4. Wang H, Castiglioni C, Kaçar Bayram A, Fattori F, Pekuz S, Araneda D, Per H, Erazo R, Gümüş H, Zorludemir S, Becker K, Ortega X, Bevilacqua JA, Bertini E, Cirak S. Insights from genotype-phenotype correlations by novel *SPEG* mutations causing centronuclear myopathy. Neuromuscul Disord. 2017; 27:836-842.
5. Agrawal PB, Pierson CR, Joshi M, *et al*. SPEG interacts with myotubularin, and its deficiency causes centronuclear myopathy with dilated cardiomyopathy. Am J Hum Genet. 2014; 95:218-226.
6. Wang H, Schänzer A, Kampschulte B, Daimagüler HS, Logeswaran T, Schlierbach H, Petzinger J, Ehrhardt H, Hahn A, Cirak S. A novel *SPEG* mutation causes non-compaction cardiomyopathy and neuropathy in a floppy infant with centronuclear myopathy. Acta Neuropathol Commun. 2018; 6:83.
7. Tang J, Ma W, Chen Y, Jiang R, Zeng Q, Tan J, Jiang H, Li Q, Zhang VW, Wang J, Tang H, Luo L. Novel SPEG variant cause centronuclear myopathy in China. J Clin Lab Anal. 2020; 34:e23054.
8. Lornage X, Sabouraud P, Lannes B, Gaillard D, Schneider R, Deleuze JF, Boland A, Thompson J, Böhm J, Biancalana V, Laporte J. Novel *SPEG* mutations in congenital myopathy without centralized nuclei. J Neuromuscul Dis. 2018; 5:257-260.

Received February 13, 2021; Revised March 29, 2021; Accepted May 18, 2021.

**Address correspondence to:*
Mirac Yildirim, Department of Pediatric Neurology, Ankara University Faculty of Medicine, Ankara, RI 06590, Turkey.
E-mail: miracyildirim81@hotmail.com

Released online in J-STAGE as advance publication May 22, 2021