https://doi.org/10.17221/144/2020-VETMED

Partial uterine prolapse and ovarian cysts in two Djungarian hamsters

Hatice Esra Colakoglu[1], Murat Onur Yazlik[1], Arzu Esen[1], Arda Selin Tunc[2]*

[1]*Small Animal Hospital, Department of Obstetrics and Gynecology, Faculty of Veterinary Medicine, Ankara University, Ankara, Turkey*
[2]*Department of Pathology, Faculty of Veterinary Medicine, Ankara University, Ankara, Turkey*
**Corresponding author: canatan@ankara.edu.tr*

Citation: Colakoglu HE, Yazlik MO, Esen A, Tunc AS (2021): Partial uterine prolapse and ovarian cysts in two Djungarian hamsters. Vet Med-Czech 66, 40–44.

Abstract: A 2-year-old multiparous (Case 1) and a 2.5-year-old nulliparous (Case 2) Djungarian hamster each presented with a history of a prolapsed mass from the vulva. A partial uterine prolapse was diagnosed in both cases, according to the clinical and diagnostic examinations. The prolapsed mass was replaced in each hamster, and an ovariohysterectomy was performed. The histopathological examination of the removed tissues revealed a cyst and papillary hyperplasia in the ovary. This first case report, to our knowledge, demonstrates the possibility of a uterine prolapse with a cyst and papillary hyperplasia in the ovary and how to surgically manage this condition. The report could also contribute to having a better understanding of the occurrence of a uterine prolapse without parturition in hamsters.

Keywords: cysts; ovariohysterectomy; prolapse; uterus

A uterine prolapse is a protrusion of one or two uterus horns through the opening of the vulva. If only one of the horns is prolapsed, the condition is called a partial uterine prolapse. The occurrence of a uterine prolapse can be seen in women and most domestic animals (Jelovsek et al. 2007; Deroy et al. 2015). The exact cause of a uterine prolapse is still unknown. Many risk factors have a role in the occurrence of a uterine prolapse; genetic predisposition, aberrant connective tissue, obesity, advancing age, parturition influencing the formation of uterine prolapse in women like in animals (Dietz 2008; Miesner and Anderson 2008). Uterine prolapse has rarely been described in exotic small mammals, and only referred to in guinea pigs (Richardson 2000; Bennet 2012), rabbits (Rosell and de la Fuente 2016; Di Graloma et al. 2019) and a mouse (Chawla et al. 2019). There are no case reports about a uterine prolapse and the clinical management of a uterine prolapse in hamsters regardless of parturition.

Cystic ovaries have been described as being a common occurrence in all small rodents older than 2 years, especially in hamsters (Martorell 2017). The aetiology of ovarian cysts is not clear in small rodents. Cystic ovaries are often associated with concurrent diseases in the reproductive tract (Keller et al. 1987; Paterson 2006).

There is no information about the occurrence of a uterine prolapse, which has not been associated with parturition. This case herein describes the clinical presentation of a uterine prolapse in two Djungarian hamsters with ovarian cysts and the successful treatment with an ovariohysterectomy.

https://doi.org/10.17221/144/2020-VETMED

Case summary

CASE 1

A 2-year old multiparous Djungarian hamster was presented to a small animal clinic with a history of mass prolapses from the vulva (Figure 1). The female was being kept together with a male. The owner did not report inappetence or weakness. The hamster gave birth 2 months previously and there was no history of abortion.

The owners observed that the hamster had come into heat a few days ago. The mass was noticed 2 days prior to the visit to the clinic. During the routine clinical examination, the activity, body condition and general health status were judged as good. The tissue, which protruded from the vulva was diagnosed as a uterine horn. Initially, the swollen mass was kept under pressure gently with hyperosmotic solutions (30% dextrose; 20% mannitol) to decrease the oedema and reduce the volume of the mass. This procedure was planned for the replacement of the prolapsed mass. However, this type of intervention was not successful and subsequently a decision to solve the problem surgically was made.

General anaesthesia was induced and maintained with isoflurane administered in 100% oxygen. The hamster was placed in the dorsal position. The wall of the abdomen was routinely prepared for the surgery and a midline laparotomy was performed.

At first, the prolapsed uterine horn was replaced to its normal anatomical position (Figure 2), then an ovariohysterectomy was performed per the owner's request (Figure 3).

The abdomen was closed according to a routine procedure. Preventively, enrofloxacin was administered 10 mg/kg twice a day for 5 days.

CASE 2

A 2.5 year-old Djungarian hamster was presented to our small animal clinic with a history of a mass with haemorrhages protruding from the vulva. The owner reported that the mass was found 4 days previously. There were no signs of inappetence or weakness. The owner also reported that the hamster was nulliparous and had come into heat before the mass prolapse. The mass was identified as a uterine horn. On the horn of the uterus,

Figure 1. Prolapsed mass of Case 1

Figure 2. Replacing the prolapsed tissue from Case 1. Prolapsed horn (arrow)

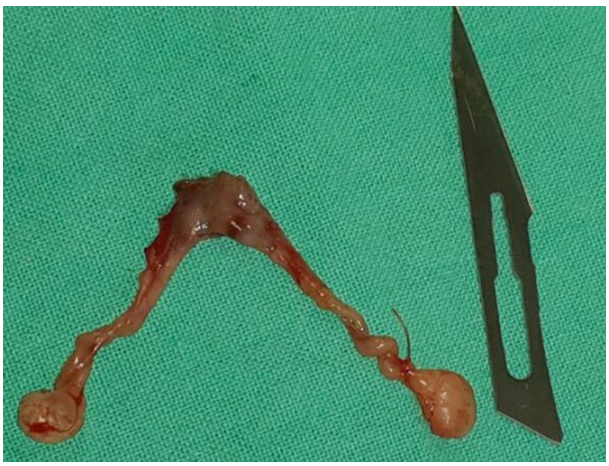

Figure 3. Both ovaries and horns of the uterus from Case 1

https://doi.org/10.17221/144/2020-VETMED

surface erosions, haemorrhagic areas and cannibalism symptoms were seen (Figure 4). Because of the injury to the prolapsed tissue and haemorrhages, the decision to perform surgery was immediately made. An ovariohysterectomy was performed, similar to the procedure as in Case 1. The abdominal wound was closed according to standard procedures. Enrofloxacin 10 mg/kg b.i.d. was administered for 5 days.

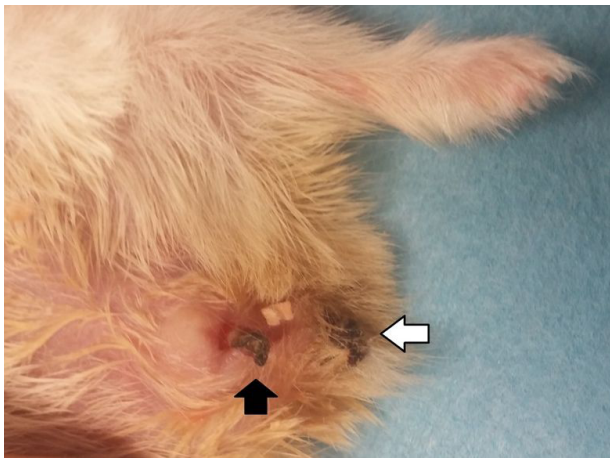

Figure 4. Necrotic and haemorrhagic areas on the uterine horn (black arrow) and tail (white arrow) from Case 2

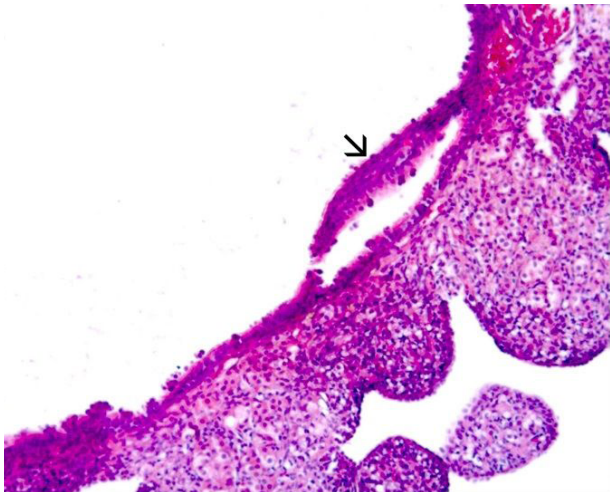

Figure 5. Papillary hyperplastic area from Case 1 (arrow). H&E; ×100

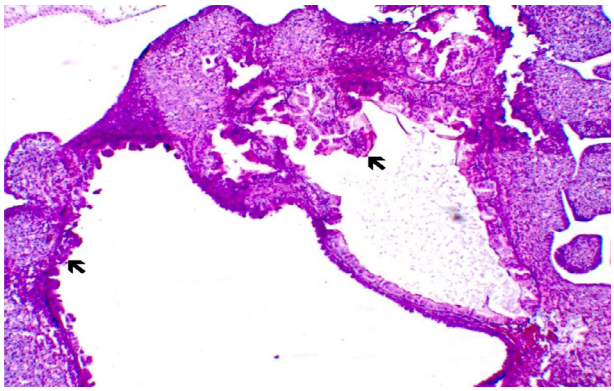

Figure 6. Cystic and papillary hyperplastic areas from Case 2 (arrows). H&E; ×40

In the post-operative hospitalisation process of the hamsters, signs of pain, such as an abnormal posture, decreased activity and appetite, abnormal aggression, elevated respiratory rate (NRC 2009) were not present and all the sutures were removed on the fifth day after surgery.

The histopathological examination of the tissues revealed that ovaries in both cases had cystic structures, papillary hyperplasia (Figures 5 and 6) and subacute steatitis. There were no pathological lesions detected on the uterine tissue.

DISCUSSION AND CONCLUSION

This case report tackles the random occurrence of a uterine prolapse with cysts and papillary hyperplasia in the ovary. A uterine prolapse more commonly occurs in women, cows, pigs, and cats (Jelovsek et al. 2007; Miesner and Anderson 2008; Deroy et al. 2015). It is rarely reported in exotic animals such as guinea pigs (Richardson 2000; Bennet 2012), rabbits (Di Girolamo et al. 2019) and mice (Chawla et al. 2019). However, there are no data in literature about the occurrence of a uterine prolapse in hamsters.

The main cause of the uterine prolapse is the relaxation of the pelvic ligaments and muscles, and, as a result, the inability to support the uterus. A uterine prolapse is occasionally observed in animals with dystocia and parturition. The predisposing factors could include high levels of oestrogen and relaxin, being overweight, having an altered micro- and macro-mineral metabolism, constipation, ovarian cysts or a genetic predisposition (Dietz 2008; Reid 2011; Yotov et al. 2013; Deroy et al. 2015). In the cases reported hereof, there was no recent parturition in the two cases and, therefore, the uterine prolapse could not be associated with parturition. Because of the similarities between human and rodent anatomy, rodents are accepted as a model in studies of uterine prolapse (Couri et al. 2012). In human medicine, the main causes of uterine prolapse have been described as the weakness of the pelvic floor diaphragm and the loss of integrity of the uterosacral and cardinal ligament complex (Reid

https://doi.org/10.17221/144/2020-VETMED

2011). A uterine prolapse is presumed to be a connective tissue disorder and changes in the collagen tissue have a role in prolapse formation (Rinne and Kirkinen 1999). Oestrogen also plays a role in the collagen metabolism. Oestrogen stimulates the collagen degradation by increasing the proteinase activity such as matrix metalloproteinase 2 (MMP-2) (Jackson et al. 2002). MMP-2 would lead to a loss in strength of the fibrous collagen and the reduction of its mechanical strength and increase the risk of a prolapse (Jackson et al. 1996; Ma et al. 2012).

Based on the owners' observations, we know that both hamsters came into heat days before the uterine prolapse. Exposure to oestrogen might be effective in decreasing the tension of the structural contents. Decreasing the tension triggers a uterine prolapse like a domino effect.

In both cases, the oestrogen during the oestrous cycle might have contributed to the development of the uterine prolapse.

Additionally, Dietz (2008) reported a progressive relaxation of the pelvic support of the uterus and vagina with an advancing age in women. Therefore, this relaxation may lead to a clinically important uterine prolapse in susceptible women as well (Dietz 2008). The average life of hamsters is 3 years, and both hamsters in the study were of an advanced age.

Because of the similarities between humans and rodents, it could be stated that cause of the uterine prolapse may be related to the relaxation of the pelvic ligaments and muscles depending on the advanced age in both hamsters.

A uterine prolapse is a life-threatening situation. Treatment approaches vary depending on the breed and tissue injury. The most appropriate treatment procedure for a uterine prolapse in hamsters is a surgical approach. Because of the anatomy, structure and size of the genital tissues, there was no possibility to push the prolapsed tissue back and to place a suture in the vulva. Also, connective tissue disorders and the uterine tissue function loss might be irreversible (Abramowitch et al. 2009). Accordingly, an ovariohysterectomy was performed with the idea that the traumatic tissue will not be functional, and to prevent the recurrence of a uterine prolapse.

The histopathological examination of the ovarian tissue revealed cysts and papillary hyperplasia in both cases. Cystic ovaries have been described as being a common occurrence in all small rodents older than 2 years, especially in hamsters (Percy and Barthold 2007; Girling 2013; Martorell 2017). The aetiology of ovarian cysts is unknown, but a certain role may be played by oestrogenic substances in hay. Serous cysts (cystic *rete ovarii*) are one of the types of cysts seen in exotic animals. These cysts are incapable of steroidogenesis. Cysts are usually asymptomatic, however, as they grow in size, symmetric alopecia, abdominal distension and infertility may be observed (Martorell 2017). Cystic ovaries are often associated with concurrent diseases in the reproductive tract such as cystic endometrial hyperplasia, mucometra or endometritis (Keller et al. 1987; Paterson 2006; Pilny 2014).

A definitive diagnosis requires an ovariectomy/ovariohysterectomy along with a histopathologic examination of the affected tissues (Sayers and Smith 2010).

In both cases, the owners stated that both hamsters did not experience infertility and showed oestrus before the prolapse. The cysts were detected accidentally during the surgery. It is thought that these cysts may be inactive rete cysts and associated with the uterine pathology as mentioned in the literature.

The fact that a uterine prolapse has a multifactorial aetiopathogenesis, further research, especially from the genetics point of view, need to be undertaken to understand the exact cause.

In conclusion, although it is a rare case in veterinary literature, a uterine prolapse may appear with cystic and papillary hyperplasia in hamsters regardless of parturition.

Conflict of interest

The authors declare no conflict of interest.

REFERENCES

Abramowitch SD, Feola A, Jallah Z, Moalli PA. Tissue mechanics, animal models, and pelvic organ prolapse: A review. Eur J Obstet Gynecol Reprod Biol. 2009 May;Suppl 1: S146-58.

Bennett RA. Soft tissue surgery. In: Quesenberry KE, Carpenter JW, editors. Ferrets, rabbits, and rodents: Clinical medicine and surgery. 3rd ed. St. Louis, MO, USA: Elsevier; 2012. p. 326-38.

Chawla S, Mahara K, Bathrachalam C. Successful treatment of postparturient pelvic prolapse in mouse (Mus muscu-

https://doi.org/10.17221/144/2020-VETMED

lus) using a novel hydropropulsion technique. J Exotic Pet Med. 2019 April;29:79-82.

Couri BM, Lenis AT, Borazjani A, Paraiso MF, Damaser MS. Animal models of female pelvic organ prolapse: Lessons learned. Expert Rev Obstet Gynecol. 2012 May 1;7(3): 249-60.

Deroy C, Bismuth C, Carozzo C. Management of a com-plete uterine prolapse in a cat. JFMS Open Rep. 2015 Jun 1; 1(1): [4].

Dietz HP. The aetiology of prolapse. Int Urogynecol J Pelvic Floor Dysfunct. 2008 Oct;19(10):1323-9.

Di Girolamo N, D'Ovidio D, Del Duca V, Donnelly TM, Montani A, Selleri P. Surgical resolution of uterine prolapse in three pet rabbits. J Small Anim Pract. 2019 Dec 7. Forthcoming.

Girling SJ. Common diseases of small mammals. In: Girlgling S, editor. Veterinary nursing of exotics pets. 2nd ed. New Jersey, USA: Willey Online Library; 2013. p. 59-90.

Jackson SR, Eckford SD, Abrams P, Avery NC, Tarlton JF, Bailey AJ. Changes in metabolism of collagen in genitourinary prolapse. The Lancet. 1996 June 15;347(9016): 1658-61.

Jackson S, James M, Abrams P. The effect of oestradiol on vaginal collagen metabolism in postmenopausal women with genuine stress incontinence. BJOG. 2002 Mar;109(3): 339-44.

Jelovsek JE, Maher C, Barber MD. Pelvic organ prolapse. The Lancet. 2007 Mar 24;369(9566):1027-38.

Keller LS, Griffith JW, Lang CM. Reproductive failure associated with cystic rete ovarii in guinea pigs. Vet Pathol. 1987 July 1;24(4):335-9.

Ma Y, Guess M, Datar A, Hennesey A, Cardenas I, Johnson J, Connell KA. Knockdown of Hoxa11 in vivo in the uterosacral ligament and uterus of mice results in altered collagen and matrix metalloproteinase activity. Biol Reprod. 2012 Apr 5;86(4):100.

Martorell J. Reproductive disorders in pet rodents. Vet Clin Exot Anim. 2017 May;20(2):589-608.

Miesner MD, Anderson DE. Management of uterine and vaginal prolapse in the bovine. Vet Clin North Am Food Anim Pract. 2008 Jul;24(2):409-19.

NRC – National Research Council. National Research Council (US) committee on recognition and alleviation of pain in laboratory animals. Recognition and alleviation of pain in laboratory animals. Washington (DC): National Academies Press (US); 2009. 177 p.

Paterson S. Dermatology of mammals. In: Paterson S, editor. Skin diseases of exotic pets. 1st ed. Iowa, USA: Blackwell Publishing Professional; 2006. p. 242-4.

Percy DH, Barthold SW. Rats. In: Percy DH, Barthold SW, editors. Pathology of laboratory rodents and rabbits. 3rd ed. Iowa, USA: Wiley-Blackwell Publishing; 2007. p. 125-77.

Richardson VCG. The reproductive system. In: Richardson VCG, editor. Diseases of domestic guinea pigs. 2nd ed. Malden, USA: Blackwell Publishing; 2000. p. 14-38.

Pilny A. Ovarian cystic disease in guinea pigs. Vet Clin Exot Anim. 2014 Jan;17(1):69-75.

Rinne KM, Kirkinen PP. What predisposes young women to genital prolapse?. Eur J Obstet Gynecol Reprod Biol. 1999 May;84(1):23-5.

Reid F. Uterine prolapse-preservation or excision? Obstet Gynaecol Reprod Med. 2011 June;21(6):176-9.

Rosell JM, de la Fuente LF. Causes of mortality in breeding rabbits. Prev Vet Med. 2016 May 1;127:56-63.

Sayers I, Smith S. Mice, rats, hamsters and gerbils. In: Meredith A, Johnson-Delaney C, editors. BSAVA manual of exotic pets. 5th ed. Gloucester, England: BSAVA; 2010. p. 1-27.

Yotov ST, Atanasov A, Antonov A, Karadaev M. Post oestral vaginal prolapse in a non-pregnant heifer (a case report). Trakia J Sci. 2013;11(1):95-101.

Received: July 9, 2020
Accepted: October 22, 2020