Human Reproduction Vol.23, No.8 pp. 1910–1916, 2008 doi:10.1093/humrep/den167
Advance Access publication on May 16, 2008

Combined laparoscopic surgery and pentoxifylline therapy for treatment of endometriosis-associated infertility: a preliminary trial

Montserrat Creus, Francisco Fábregues, Francisco Carmona, Marta del Pino, Dolors Manau and Juan Balasch[1]

Institut Clinic of Obstetrics, Gynaecology and Neonatology, Faculty of Medicine-University of Barcelona, Hospital Clínic - Institut d'Investigacions Biomèdiques August Pi i Sunyer (IDIBAPS), c/ Casanova 143, 08036-Barcelona, Spain

[1]Correspondence address. E-mail: jbalasch@ub.edu

BACKGROUND: Surgical treatment has modest efficacy for the treatment of infertility associated with early-stage endometriosis. Immunomodulation with pentoxifylline is considered as a new strategy potentially useful in treating endometriosis. Thus, this study investigated the usefulness of combined laparoscopic surgery and pentoxifylline therapy in the treatment of infertility associated with minimal to mild endometriosis. METHODS: A prospective, randomized, controlled blind trial was conducted. Patients entered the study immediately after laparoscopic surgery and were randomly assigned to the treatment with either oral pentoxifylline (800 mg/day) (pentoxifylline group, $n = 51$) or an oral placebo (placebo group, $n = 53$). Patients were then observed for pregnancy for 6 months. RESULTS: Among 98 patients finally considered in the evaluation of the results, the 6 month overall pregnancy rates were 28 and 14% in the pentoxifylline and placebo groups, respectively. Thus, an absolute difference of 14% (95% CI −2 to 30) (Chi-squared test, $P = 0.1$) in the cumulative probability of pregnancy in 6 months after laparoscopic surgery in patients receiving pentoxifylline versus placebo post-operatively was observed. CONCLUSION: Our findings provide preliminary clinical evidence to suggest the new experimental treatment approaches, toward endometriosis, that are based on immunomodulation deserve further attention. Well-designed multicenter trials are warranted to confirm or refute our results.

The ClinicalTrials.gov Identifier is NCT00632697.

Keywords: endometriosis; immunomodulation; infertility; laparoscopic surgery; pentoxifylline

Introduction

Current guidelines for the treatment of stages I–II endometriosis-associated infertility recommend ablation of endometriosis lesions plus adhesiolysis to improve fertility (Kennedy *et al*., 2005; The Practice Committee of the American Society for Reproductive Medicine, 2006). This recommendation is based on a meta-analysis of two similar but contradictory randomized controlled trials investigating the effect on pregnancy rates of surgical ablation or resection of the endometriosis lesions (Marcoux *et al*., 1997; Parazzini, 1999). When the results of the two studies were combined, the absolute treatment difference was 8%, yielding a number needed to treat of 12, thus indicating that for every 12 women undergoing laparoscopy that have ablation of minimal or mild endometriosis lesions, there will be one additional pregnancy, compared with not doing ablation. Thus, it was concluded that there is a statistical evidence for a slight beneficial effect of surgical removal of the lesions, but the size of this effect is small and may be short-lived (ESHRE Capri Workshop Group, 2004).

The modest efficacy of minimal to mild endometriosis ablation in increasing the pregnancy rate in infertile women may be explained by the fact that the surgical treatment can remove visible lesions but will leave behind a number of occult ones, which, after removal of the visible lesions, may develop into minimal endometriosis and proceed from there (Evers, 2004). This would explain why the optimal time for conception to occur is within the first months following surgical resection (Silverberg, 1992; Donnez *et al*., 2003). On the other hand, considering that the monthly fecundity rate among women who underwent laparoscopic surgery is lower than the rate expected in fertile women, it must be assumed that the destruction of visible endometriotic implants do not affect all factors by which minimal and mild endometriosis contributes to infertility (Marcoux *et al*., 1997). In other words, it is possible that the visible lesions contribute only a small fraction of the reduced fecundity seen in women with early-stage endometriosis (The Practice Committee of the American Society for Reproductive Medicine, 2006).

© *The Author 2008. Published by Oxford University Press on behalf of the European Society of Human Reproduction and Embryology. All rights reserved. For Permissions, please email: journals.permissions@oxfordjournals.org*

Downloaded from https://academic.oup.com/humrep/article/23/8/1910/2914066 by ANKARA UNIVERSITESI user on 11 December 2021

On the above evidence, combined therapy involving surgical excision of visible endometriosis followed by the administration of ovulation-suppression hormones to treat potential residual lesions has been extensively used (Winkel, 1999; The Practice Committee of the American Society for Reproductive Medicine, 2006). The goal is similar to that commonly applied in then treatment of ovarian cancer, i.e. cytoreductive surgery followed by chemotherapy. By definition, however, post-operative hormone therapy in patients with endometriosis prevents attempts at conception during what may be the optimal time for conception to occur following surgery. Therefore, a surgical and post-operative medical therapy combined approach avoiding ovulation suppression would be warranted for treatment of endometriosis-associated infertility. In fact, the need for clinical trials assessing potential new medical treatments combined with surgical therapies has been recently stressed (Olive, 2003; Guidice and Kao, 2004; Olive *et al*., 2004).

It is now generally accepted that the immune system is involved in the pathogenesis of endometriosis. Although the peritoneal fluid of women with endometriosis contains increased numbers of immune cells, these facilitate rather than inhibit the development of endometriosis. Also, endometriotic lesions secrete several proinflammatory molecules and the pelvic inflammation in women with endometriosis contributes to the development of their most common complaints, pain and infertility (Nothnick, 2001; Seli and Arici, 2003; Guidice and Kao, 2004). Thus, the use of general immunomodulators is considered as a new strategy potentially useful in endometriosis (Nothnick, 2001; Nothnick and D'Hooghe, 2003; Olive, 2003; Olive *et al*., 2004). In fact, early experimental work showed that immunomodulation affects both endometriotic implant growth and endometriosis-associated infertility (Steinleitner *et al*., 1991a,b,c; Nothnick *et al*., 1994; Keenan *et al*., 1999; Badawy *et al*., 2001), but available data in the clinical setting are limited and indefinite (Balasch *et al*., 1997; Alborzi *et al*., 2007).

Therefore, this prospective, randomized clinical study was undertaken to investigate the usefulness of combined laparoscopic surgery and pentoxifylline therapy for the treatment of early-stage endometriosis-associated subfertility.

Material and Methods

A total of 98 patients were finally evaluated in a randomized controlled blind trial investigating the effect of pentoxifylline therapy after laparoscopic surgery on future fertility in infertile women with asymptomatic endometriosis. The study was approved by the Ethics Committee of our hospital. Because in our previous clinical trial using pentoxifylline alone, all patients who became pregnant did so within 6 months of starting therapy (Balasch *et al*., 1997), this was the period of treatment and follow-up allowed by the Committee for the current investigation. Patients were recruited after a laparoscopy for infertility involving minimal or mild endometriosis which had been diagnosed and treated surgically. All patients with other pelvic disorders such as adhesions and tubal obstructions in addition to endometriosis were excluded. Patient characteristics and inclusion criteria were thus similar to those reported in our previous study (Balasch *et al*., 1997). All women had complained of at least 12 months of asymptomatic primary infertility and none of them had previous pelvic surgery, clinical or laparoscopic–laparotomic diagnosis of endometriosis, or previous therapy for this condition. All the subjects were regularly menstruating (menstrual cycles of 26–33 days) premenopausal women 23–37 years old and having a normal body mass index (BMI) of 19–26 kg/m^2. Diagnostic evaluation for infertility included semen analysis, post-coital test, assessment of ovulation by mid-luteal progesterone and prolactin determinations, hysterosalpingogram (and hysteroscopy when necessary) and laparoscopy. Patients with other infertility factors were included if those factors were correctable and ultimately assessed to be non-contributory.

In all cases, diagnosis of endometriosis was made by laparoscopy as previously reported (Balasch *et al*., 1996, 1997). Briefly, a systematic evaluation of all pelvic peritoneal surfaces was carried out in all patients, endometriosis was staged according to the revised American Fertility Society (1985) scoring, and superficial ovarian and peritoneal endometriosis was classified as red lesion, black lesion, or white lesion (Brosens *et al*., 1993). Biopsies of suspicious lesions were taken when the visual diagnosis of endometriosis was in doubt (six cases) and were considered positive for endometriosis only when a histopathological study revealed the presence of endometrial glands and stroma (five cases). All laparoscopies included tubal dye perfusion. The laparoscopic surgical treatment involved the destruction of all visible endometriotic implants by cautery.

Patients entered the study immediately after laparoscopic surgery and all of them gave written informed consent. They were assigned, according to a computer-generated randomization list generated using the method of simple randomization, to one of the following treatments: oral pentoxifylline (Elorgán, Aventis Pharma, Madrid, Spain) 400 mg twice daily ($n = 51$) or an oral placebo ($n = 53$) to be taken twice daily. Concealment of treatment allocation was achieved with the use of sealed opaque envelopes each containing a unique study number and prepared independently by a secretary. Treatment was started with the first menses following laparoscopic surgery and patients were then observed for pregnancy for 6 months. During this period, other infertility factors such as male problems or ovulatory defects were treated with the appropriate therapeutic modalities including intrauterine insemination with husband or donor semen and/or ovulation induction. Remarkably, patients, who had been treated for additional correctable infertility factors before laparoscopy, received the same additional infertility treatments during the same number of cycles after endometriosis was treated surgically. This was also true for those couples empirically treated with intrauterine insemination plus ovulation induction before laparoscopic surgery. Thus, patients were their own control for additional infertility factors, which adds to the homogeneity of the study groups. Pregnancy was diagnosed by ultrasonography, and if so, treatment with pentoxifylline or placebo was discontinued.

Data were analysed by Statistics Package for Social Sciences (SPSS) statistical software using Chi-square test, Mann-Whitney U-test and Fisher's exact test. Results were expressed as mean (SD). $P < 0.05$ was considered significant.

Results

A flow chart of inclusion, randomization and drop-out of patients treated in the study is shown in Fig. 1. There were 104 patients who were initially randomized but, in total, the responses of 98 patients to either pentoxifylline ($n = 47$) or placebo ($n = 51$) after laparoscopic surgery were finally evaluated. All these 98 patients took the drug or placebo regularly

Downloaded from https://academic.oup.com/humrep/article/23/8/1910/2914066 by ANKARA UNIVERSITESI user on 11 December 2021

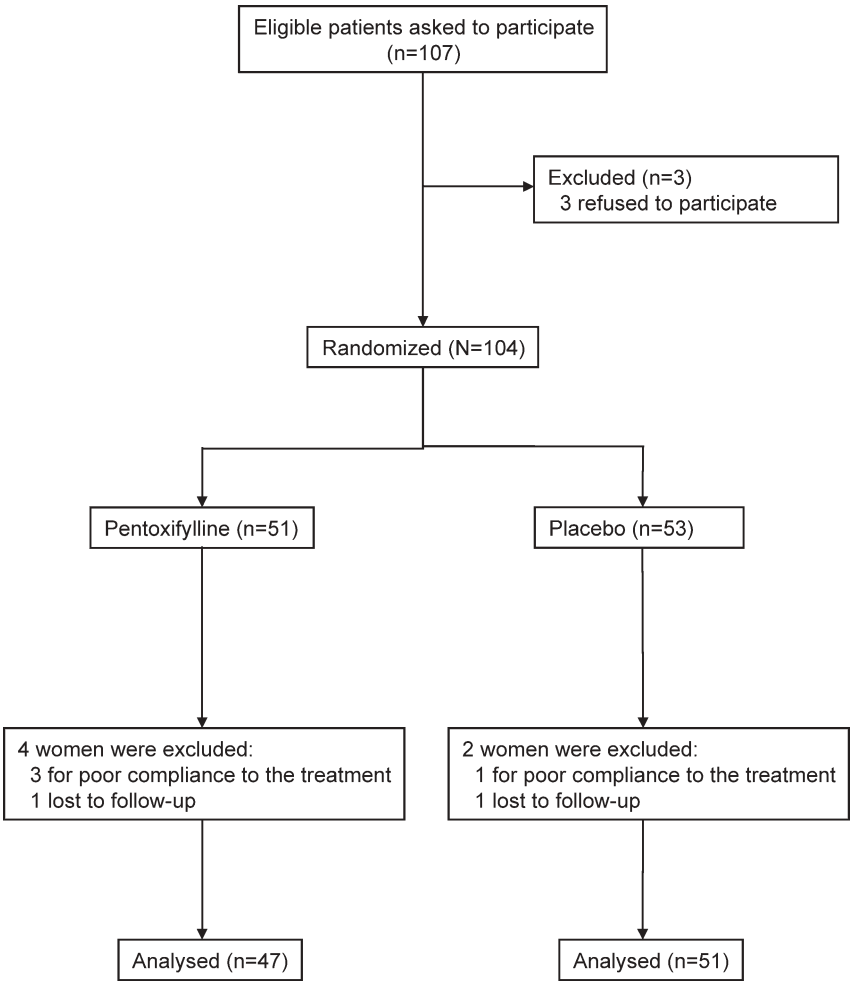

Figure 1: Flow chart of inclusion, randomization and drop-out of patients included in this study.

and actively tried to become pregnant during the 6-month study period.

Table I shows baseline characteristics of the patients and the distribution of other infertility factors in each study group. Both treatment groups were similar regarding age, BMI, duration of infertility, prevalence of endometriosis by revised American Fertility Society (1985) classification, and diagnosis of appearances of the condition. The frequency of additional correctable infertility factors and additional infertility treatments were also similar for both study groups (Table I).

Among 98 patients finally considered in the evaluation of the results, there were a total of 20 pregnancies, giving 6 month overall pregnancy rates of 28 and 14% in the pentoxifylline ($n = 13$ gestations) and placebo ($n = 7$ gestations) groups, respectively. Thus, an absolute difference of 14% (95% CI −2 to 30%) ($P = 0.1$) in the cumulative probability of pregnancy in the first 6 months after laparoscopic surgery in patients receiving pentoxifylline versus placebo postoperatively was observed (Fig. 2). One patient in the pentoxifylline group miscarried at 5 weeks gestation.

When patients were categorized as pregnant or nonpregnant, according to treatment regimen, again the presence of corrected additional infertility factors did not appear to influence the rate of pregnancy by Fisher's exact test (Table II).

Discussion

The hypothesis that endometriosis causes a decrease in fecundity or infertility remains controversial. Whereas there is a considerable evidence to demonstrate an association between endometriosis and infertility, a cause and effect relationship has not been established in early stages of the disease where there is no disruption of the pelvic anatomy. Accordingly, the management of this disease is a source of controversy and so far no consensus has been reached (Donnez *et al*., 2003; Nezhat *et al*., 2005; The Practice Committee of the American Society for Reproductive Medicine, 2006). This notwithstanding surgery has been extensively used in an attempt to enhance fertility on the premise that the eradication of the disease should improve fecundity and on the evidence that the ablation of endometriotic lesions in minimal–mild endometriosis is effective compared with diagnostic laparoscopy alone (Kennedy *et al*., 2005; The Practice Committee of the American Society for Reproductive Medicine, 2006).

In fact, originally the disease was felt to be the best treated surgically and with the progressive development of operative laparoscopy, the treatment of endometriosis could be instituted at the time of diagnosis, resulting in a more efficient but not necessarily more effective therapy. However, as the complexity and chronicity of endometriosis has been recognized, the

Downloaded from https://academic.oup.com/humrep/article/23/8/1910/2914066 by ANKARA UNIVERSITESI user on 11 December 2021

Table I. Baseline characteristics and additional correctable infertility factors in the pentoxifylline and placebo groups.

Variable	Pentoxifylline group ($n = 51$)	Placebo group ($n = 53$)
Age (year)	33.1 (3.6)	31.1 (3.3)
Body mass index (kg/m^2)	23.3 (3.0)	23.1 (3.1)
Duration of infertility (year)	3.8 (1.9)	3.4 (1.7)
AFS stage		
I	39 (76%)	46 (87%)
II	12 (24%)	7 (13%)
Laparoscopic appearance[a]		
Red lesion	7 (14%)	5 (9%)
Black lesion	41 (80%)	43 (81%)
White lesion	13 (25%)	15 (28%)
Additional infertility factors		
None	40 (78%)	41 (77%)
Male factor	7 (14%)	10 (19%)
Oligo-ovulation	2 (4%)	1 (2%)
Poor post-coital test	1 (2%)	1 (2%)
Hyperprolactinemia	1 (2%)	0
Additional infertility treatments		
IUI+ovulation induction	9 (18%)	16 (30%)
Ovulation induction	2 (4%)	2 (4%)
Bromocriptine	1 (2%)	0

AFS, American fertility society; IUI, intrauterine insemination (donor semen used in three and five patients in pentoxifylline and placebo groups, respectively). Values are mean (SD) or *n* (%). There were no significant differences between the groups. [a]A subject may have different type of lesions.

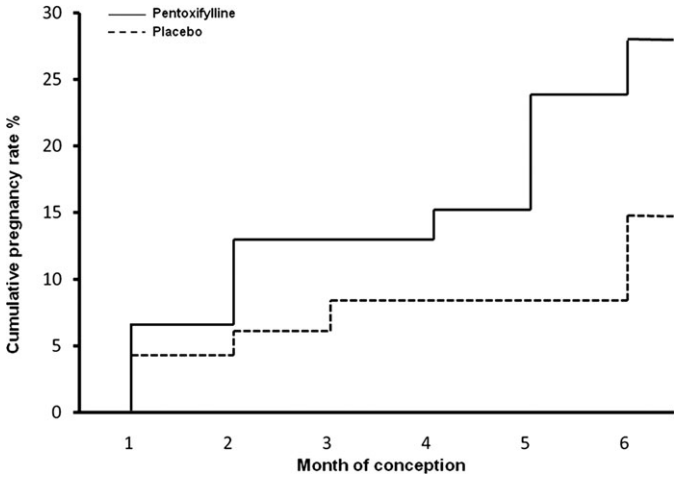

Figure 2: Overall 6 month probability of becoming pregnant in 98 subjects with minimal or mild endometriosis according to treatment allocation.

pendulum has been swinging relentlessly towards medical options and it is now accepted that medical treatment that can induce a generalized suppression of the disease is necessary (Nothnick, 2001; Olive, 2003; Evers, 2004; Olive *et al*., 2004).

The medical treatment of endometriosis has long centered upon inducing a hypoestrogenic environment by producing pituitary suppression using hormones such as progestogens, oral contraceptives, danazol, GnRH-agonists or gestrinone generally given over 6 months. However, a quantitative overview of controlled trials in endometriosis-associated infertility showed that hormonal therapy is an ineffective treatment for this condition (Olive, 2003; Kennedy *et al*., 2005; The Practice Committee of the American Society for Reproductive Medicine, 2006). Remarkably, it has been stressed that what is frequently overlooked is the fact that not only do these hormones fail to enhance fertility, they may also delay fertility in that the patient is unable to conceive while being medicated for several months (Olive, 2003). If those controlled trials are reanalysed with follow-up beginning at the time of diagnosis rather than at the conclusion of therapy, medical therapy is significantly worse than no treatment, with a relative risk of 0.60 (95% CI 0.38–0.93) (Olive, 2003). Thus, suppressive medical therapy for early-stage endometriosis may in fact be counterproductive to the subfertile patient. This drawback becomes even more important in the infertile patient with endometriosis treated surgically because traditional post-operative hormone therapy interferes with ovulation during a critical period for conception (Silverberg, 1992; Donnez *et al*., 2003).

Among new medical treatments proposed as potentially useful for endometriosis, pentoxifylline is an exciting and promising candidate. The following facts support this contention. First, this medication influences both the production of inflammatory mediators and the responsiveness of immunocompetent cells to inflammatory stimuli. As endometriosis is a disease associated with immune and inflammatory disorders, this medication has a rationale in an attempt to correct immune dysfunction (Nothnick, 2001; Olive *et al*., 2004). Second, in the animal model, pentoxifylline is capable of inducing regression of endometriotic tissue without inducing a hypoestrogenic state (Nothnick, 2001; Nothnick and D'Hooghe, 2003). Third, it has been shown that pentoxifylline administration can reverse endometriosis-associated infertility in hamsters with surgically induced disease (Steinleitner *et al*., 1991a,b). Fourth, as it is not an inhibitor of ovulation, pentoxifylline can be administered

Table II. Patients with minimal to mild endometriosis who conceived in both treatment groups.

Patients	Pentoxifylline group ($n = 47$)		Placebo group ($n = 51$)	
	No. cases	No. conception	No. cases	No. conception
No additional infertility factors[a]	37	8 (21%)	39	4 (10%)
Corrected additional infertility factors[b]	10	5 (50%)	12	3 (25%)
Total[c]	47	13 (28%)	51	7 (14%)

There were no significant differences between the groups by the Chi-squared test: [a]$P = 0.2$ (95% CI, −0.27 to 0.04); [b]$P = 0.3$ (95% CI, −0.64 to 0.14); [c]$P = 0.1$ (95% CI, −2 to 30).

Downloaded from https://academic.oup.com/humrep/article/23/8/1910/2914066 by ANKARA UNIVERSITESI user on 11 December 2021

throughout the time period of attempting conception. Finally, previous work by us (Balasch *et al*., 1997) and the current investigation support the notion that pentoxifylline therapy may play a role in the future (Nothnick and D'Hooghe, 2003; Olive *et al*., 2004) when used alone or after laparoscopic surgery to improve fertility in patients with stages I–II endometriosis. However, several features deserve comment in this regard.

First and most important, our two clinical trials were undertaken as preliminary studies and the number of patients recruited was small from a biometric point of view. However, the sample size required to test the efficacy of most interventions purported to significantly improve pregnancy rates is often prohibitively large (Daya, 2003, 2006). This is well exemplified by the current study. Meta-analysis of the two randomized trials investigating the usefulness of laparoscopic surgery for subfertility associated with endometriosis showed that the pregnancy rate in treated patients (26%) was significantly higher than among control women (18%) (Jacobson *et al*., 2002; ESHRE Capri Workshop Group, 2004). Thus, when planning the study, we could assume a control event rate (i.e. expected pregnancy rate in patients treated with laparoscopic surgery and placebo) of ~25%. In infertility research, any experimental intervention (e.g. pentoxifylline therapy after laparoscopic surgery) that can produce a treatment difference of at least 5% is considered as having clinical value (Daya, 2003, 2006). Detection of this magnitude of difference in clinical pregnancy rates (i.e. 25 and 30% in placebo and pentoxifylline treatment groups, respectively) would require a sample size of 2500 using a two-tailed hypothesis test with probabilities for types I and II error set at 0.05 and 0.2, respectively. This number is far greater than we were capable of generating in our single center study in a reasonable time period. However, in this era of meta-analysis, it is useful to provide the results of well-designed studies, even those that have low power. This is noteworthy considering that the use of pentoxifylline for treatment of endometriosis should be still considered 'experimental'. A procedure for the treatment of infertility is defined 'experimental' until there is scientific evidence indicating safety and efficacy (i.e. that the treatment is associated with a higher pregnancy rate than non-treatment of an existing condition) based on at least two appropriately designed studies (The Practice Committee of the American Society for Reproductive Medicine, 2004). This study is intended to stimulate future larger, adequately powered, probably multicenter trials or other investigators to address this issue and provide a larger basis for eventual meta-analysis of small randomized trials in order to help clarify the value of this approach.

Although we included a limited number of patients, our sample size was still higher than the number of cases included in the only five randomized controlled trials on hormone therapy for endometriosis-associated infertility having no treatment or a placebo as a randomly allocated option in one arm of the study (Olive, 2003; Evers, 2004). Thus, the results were not statistically significant but they are intriguing nonetheless, considering that we previously reported nearly a doubling (31 versus 18.5%) of pregnancy rates in women with endometriosis treated with pentoxifylline versus placebo (Balasch *et al*., 1997) and an absolute difference of 14% in the cumulative probability of pregnancy in the 6 months after laparoscopic surgery in patients receiving pentoxifylline versus placebo post-operatively (this study). This means that a potential beneficial effect of pentoxifylline is attained irrespective of being preceded by laparoscopic treatment of endometriosis or not.

Our results are in disagreement with a recent randomized clinical trial concluding that pentoxifylline therapy after laparoscopic surgery of endometriosis is not useful to improve treatment of infertility (Alborzi *et al*., 2007). It should be noted, however, that there were some important methodological differences between the current investigation and that previous study (Alborzi *et al*., 2007). Remarkably, we included only infertile patients with early-stage endometriosis in our study, while in that previous report (Alborzi *et al*., 2007) as many as 72% of 43 patients treated with pentoxifylline and 78% of 45 controls had stages III–IV endometriosis; most of them complained of pelvic pain, and thus surgical treatment was the recommended and indicated approach in the vast majority of the whole study population (Kennedy *et al*., 2005; The Practice Committee of the American Society for Reproductive Medicine, 2006). The need to differentiate patients with minimal or mild endometriosis from those with moderate or severe forms of the disease as well as patients with endometriosis-associated pelvic pain from those with endometriosis-associated infertility, when analysing the efficacy of medical and surgical treatment of infertile patients with endometriosis, has been emphasized (Donnez *et al*., 2003; The Practice Committee of the American Society for Reproductive Medicine, 2006). Furthermore, as in our previous report (Balasch *et al*., 1997) and as previously recommended (ESHRE Capri Workshop Group, 2004; Evers, 2004), we included only infertile but otherwise healthy women having stages I–II endometriosis but no adhesions, in order to specifically address whether it is surgical (and/or medical) treatment of endometriosis (and endometriosis only and not adhesiolysis or removal of adhesions) that improves fertility. In contrast, in the study by Alborzi *et al*. (2007), an unspecified number of patients had endometriomas that were treated by cystectomy and sutured or fulgurated and coagulated. Finally, we included only patients with primary infertility while in that previous report (Alborzi *et al*., 2007), 22% of patients had secondary infertility. Therefore, overall, this study included a much more homogeneous study population which, in addition, was more suitable for immunomodulation therapy.

In summary, this study and previous work from our group (Balasch *et al*., 1997) suggest that immunomodulatory therapy with pentoxifylline alone or after laparoscopic surgery may be a potentially useful treatment in early-stage endometriosis-associated infertility. We generated single-center trials showing higher, albeit not statistically different, pregnancy rates with pentoxifylline treatment versus placebo. Our studies had low power and thus, well-designed multicenter trials are warranted to confirm or refute our results. Considering the difference in pregnancy rates between the two treatment arms obtained in the current study, a sample size of 141 patients per group would be

Downloaded from https://academic.oup.com/humrep/article/23/8/1910/2914066 by ANKARA UNIVERSITESI user on 11 December 2021

necessary in order to provide 80% statistical power of avoiding a type II error, and a 5% chance of making a type I error. This is in agreement with the number of patients reported in the only randomized clinical trial indicating that surgical treatment may increase the likelihood of pregnancy in subfertile endometriosis patients (Marcoux *et al*., 1997). For an absolute treatment difference of 10%, the total sample size required would be 476 subjects. Our findings, however, provide preliminary clinical evidence supporting the notion that the design of new experimental treatment approaches, toward endometriosis that are based on immunomodulation, deserve further attention (Evers, 1993; Gleicher, 1995; Nothnick, 2001; Olive *et al*., 2004). The differential effect of immunomodulation on fertility on one hand, and on the progression and deterioration of endometriosis lesions on the other, should be one of the focus points of future research in this direction. Finally, it should be noted that there are no well controlled teratogenicity studies in pregnant women receiving pentoxifylline in the early stages of pregnancy. However, reproduction studies in rats and rabbits at oral doses up to 4.2 and 3.5 times the maximum recommended human daily dose have revealed no evidence of teratogenicity and in fact, profertility effects of pentoxifylline have been reported in rats (Ramey *et al*., 1994; Kurtoglu *et al*., 2007). In the clinical setting, pentoxifylline is being used in dermatology as an alternative to teratogenic drugs such as thalidomide (de Carsalade *et al*., 2003; Sales *et al*., 2007), and preliminary studies in infertile and IVF patients by us (Balasch *et al*., 1997) and others (Rizk *et al*., 1995; Lédée-Bataille *et al*., 2002; Letur-Konirsch and Delanian, 2003; Alborzi *et al*., 2007) are reassuring.

Acknowledgement

This work was supported in part by grant from the Comissionat per a Universitat i Recerca-Generalitat de Catalunya (2005SGR 00573) to J.B.

References

Alborzi S, Ghotbi S, Parsanezhad ME, Dehbashi S, Alborzi S, Alborzi M. Pentoxifylline therapy after laparoscopic surgery for different stages of endometriosis: a prospective, double-blind, randomized, placebo-controlled study. *J Minim Invasive Gynecol* 2007;**14**:54–58.

American Fertility Society. Revised American Fertility Society classification of endometriosis 1985. *Fertil Steril* 1985;**43**:351–352.

Badawy SZ, Etman A, Cuenca V, Montante A, Kaufman L. Effect of interferon alpha-2b on endometrioma cells in vitro. *Obstet Gynecol* 2001;**98**:417–420.

Balasch J, Creus M, Fábregues F, Carmona F, Ordi J, Martinez-Roman S, Vanrell JA. Visible and non-visible endometriosis at laparoscopy in fertile and infertile women and in patients with chronic pelvic pain: a prospective study. *Hum Reprod* 1996;**11**:387–391.

Balasch J, Creus M, Fábregues F, Carmona F, Martinez-Román S, Manau D, Vanrell JA. Pentoxifylline versus placebo in the treatment of infertility associated with minimal or mild endometriosis: a pilot randomized clinical trial. *Hum Reprod* 1997;**12**:2046–2050.

Brosens I, Donnez J, Benagiano G. Improving the classification of endometriosis. *Hum Reprod* 1993;**8**:1792–1795.

Daya S. Pitfalls in the design and analysis of efficacy trials in subfertility. *Hum Reprod* 2003;**18**:1005–1009.

Daya S. Methodological issues in infertility research. *Best Pract Res Clin Obstet Gynaecol* 2006;**20**:779–797.

de Carsalade GY, Achirafi A, Flageul B. Pentoxifylline in the treatment of erythema nodosum leprosum: results of an open study. *Acta Leprol* 2003;**12**:117–122.

Donnez J, Pirard C, Smets M, Jadoul P, Squifflet J. Pre- and post-surgical management of endometriosis. *Sem Reprod Med* 2003;**21**:235–241.

ESHRE Capri Workshop Group. Diagnosis and management of the infertile couple: missing information. *Hum Reprod Update* 2004;**10**:295–307.

Evers JLH. How to treat endometriosis-associated subfertility. Or difference in pregnancy rates between the two treatment arms should we? *Focus Reprod* 1993;**III**:9–15.

Evers JLH. Evidence-based reproductive surgery: endometriosis. In: Daya S, Harrison RF, Kempers RD (eds). *Advances in Fertility and Reproductive Medicine*. Amsterdam, The Netherlands: Elsevier BV, 2004,90–95.

Gleicher N. Immune dysfunction - a potential target for treatment in endometriosis. *Br J Obstet Gynecol* 1995;**102**(Suppl 12):4–7.

Guidice LC, Kao LC. Endometriosis. *Lancet* 2004;**64**:1789–1799.

Jacobson TZ, Barlow DH, Koninckx PR, Olive D, Farquhar C. Laparoscopic surgery for subfertility associated with endometriosis. *Cochrane Database Syst Rev* 2002; Art. No.: CD001398. DOI: 10.1002/14651858.CD001398.

Keenan JA, Williams-Boyce PK, Massey PJ, Chen TT, Caudle MR, Bukovsky A. Regression of endometrial explants in a rat model of endometriosis treated with the immune modulators loxoribine and levamisole. *Fertil Steril* 1999;**72**:135–141.

Kennedy S, Bergqvist A, Chapron C, D'Hooghe T, Dunselman G, Greb R, Hummelshoj L, Prentice A, Saridogan E on behalf of the ESHRE Special Interest Group for Endometriosis and Endometrium Guideline Development Group. ESHRE guideline for the diagnosis and treatment of endometriosis. *Hum Reprod* 2005;**20**:2698–2704.

Kurtoglu S, Gunes T, Koklu E, Bastug O, Canoz O, Kula M, Bastug F, Gunes I. Influence of maternal nicotine exposure on neonatal rate bone: protective effect of pentoxifylline. *Exp Biol Med* 2007;**232**:398–405.

Lédée-Bataille N, Olivennes F, Lefaix JL, Chaouat G, Frydman R, Delanian S. Combined treatment by pentoxifylline and tocopherol for recipient women with a thin endometrium enrolled in an oocyte donation programme. *Hum Reprod* 2002;**17**:1249–1253.

Letur-Konirsch H, Delanian S. Successful pregnancies after combined pentoxifylline-tocopherol treatment in women with premature ovarian failure who are resistant to hormone replacement therapy. *Fertil Steril* 2003;**79**:439–441.

Marcoux S, Maheux R, Berube Sand the Canadian Collaborative Group of Endometriosis. Laparoscopic surgery in infertile women with minimal or mild endometriosis. *N Engl J Med* 1997;**337**:217–222.

Nezhat C, Littman ED, Lathi RB, Berker B, Westphal LM, Giudice LC, Milki AA. The dilemma of endometriosis: is consensus possible with an enigma? *Fertil Steril* 2005;**84**:1587–1588.

Nothnick WB. Treating endometriosis as an autoimmune disease. *Fertil Steril* 2001;**76**:223–231.

Nothnick WB, D'Hooghe TM. Medical management of endometriosis: novel targets and approaches towards the development of future treatment regimes. *Gynecol Obstet Invest* 2003;**55**:189–198.

Nothnick WB, Currry TE, Vernon MW. Immunomodulation of rat endometriotic implant growth and protein production. *Am J Reprod Immunol* 1994; **31**:151–162.

Olive DL. Medical therapy of endometriosis. *Sem Reprod Med* 2003;**21**: 209–221.

Olive DL, Lindheim SR, Pritts EA. New medical treatments for endometriosis. *Best Pract Res Clin Obstet Gynaecol* 2004;**18**:319–328.

Parazzini F. Ablation of lesions or no treatment in minimal-mild endometriosis in infertile women: a randomized trial. Gruppo Italiano per lo Studio delÍEndometriosi. *Hum Reprod* 1999;**14**:1332–1334.

Ramey JW, Starke ME, Gibbons WE, Archer DF. The influence of pentoxifylline (Trental) on the antifertility effect of intrauterine devices in rats. *Fertil Steril* 1994;**62**:181–185.

Rizk B, Fountain S, Avery S, Palmer C, Blayney M, Macnamee M, Mills C, Brinsden B. Successful use of pentoxifylline in male-factor infertility and previous failure of in vitro fertilization: a prospective randomized study. J Assist. *Reprod Genet* 1995;**12**:710–714.

Sales AM, de Matos HJ, Nery JAC, Duppre NC, Sampaio EP, Sarno EN. Double-blind trial of the efficacy of pentoxifylline vs thalidomide for the treatment of type II reaction in leprosy. *Braz J Med Biol Res* 2007;**40**:243–248.

Seli E, Arici A. Endometriosis: Interaction of immune and endocrine systems. *Sem Reprod Med* 2003;**21**:135–144.

Silverberg KM. Combination therapy for endometriosis. *Infertil Reprod Med Clin N Am* 1992;**3**:683–695.

Steinleitner A, Lambert H, Roy S. Immunomodulation with pentoxifylline abrogates macrophage-mediated infertility in an in vivo model: a paradigm

Downloaded from https://academic.oup.com/humrep/article/23/8/1910/2914066 by ANKARA UNIVERSITESI user on 11 December 2021

for a novel approach to the treatment of endometriosis-associated subfertility. *Fertil Steril* 1991a;**55**:26–31.

Steinleitner A, Lambert H, Suarez M, Serpa N, Roy S. Immunomodulation in the treatment of endometriosis-associated subfertility: use of pentoxifylline to reverse the inhibition of fertilization by surgically induced endometriosis in a rodent model. *Fertil Steril* 1991b;**56**:975–979.

Steinleitner A, Lambert H, Suarez M, Serpa N, Robin B, Cantor B. Periovulatory calcium channel blockade enhances reproductive performance in an animal model for endometriosis-associated subfertility. *Am J Obstet Gynecol* 1991c;**164**:949–952.

The Practice Committee of the American Society for Reproductive Medicine. Definition of "experimental". *Fertil Steril* 2004;**82**(Suppl 1):S207.

The Practice Committee of the Amercian Society for Reproductive Medicine. Endometriosis and infertility. *Fertil Steril* 2006;**86**(Suppl 4):S156–S160.

Winkel CA. Combined medical and surgical treatment of women with endometriosis. *Clin Obstet Gynecol* 1999;**42**:645–663.

Submitted on November 24, 2007; resubmitted on March 17, 2008; accepted on April 8, 2008

Downloaded from https://academic.oup.com/humrep/article/23/8/1910/2914066 by ANKARA UNIVERSITESI user on 11 December 2021