European Journal of Therapeutics
pISSN: 2564-7784
eISSN: 2564-7040

Eur J Ther. 2024.
https://doi.org/10.58600/eurjther2227

Original Research

Efficacy of Triple Shoulder Injection with Steroids and Ozone in the Treatment of Chronic Shoulder Pain and Range of Motion Limitation

Derya Bayram [1], İbrahim Aşık [2]

[1] Pain Clinic, Mardin Training and Research Hospital, Artuklu, Mardin, Türkiye
[2] Department of Pain Medicine, Ankara University Faculty of Medicine Ibni Sina Hospital, Ankara, Türkiye

Received: 2024-06-07 **Accepted:** 2024-08-05 **Published Online:** 2024-08-07

Corresponding Author
Derya Bayram, MD
Address: Mardin Training and Research Hospital, Pain Clinic, Artuklu, Mardin, Türkiye
E-mail: deryak_30@hotmail.com

ABSTRACT

Objective: This study aimed to evaluate and compare the therapeutic effects of fluoroscopy-guided triple shoulder injections with steroids and, a combination of steroids and ozone.

Methods: Data were retrospectively collected from the files of 70 patients diagnosed with non-specific chronic shoulder pain and received triple shoulder injections. The patients were divided into two groups. One group included triple shoulder injections with steroids under fluoroscopic guidance, while the other group included combination of steroids and ozone. Pain intensity was evaluated with the Visual Analog Scale (VAS), the patient's quality of life and functionality were assessed using the Shoulder Pain and Disability Index (SPADI), and the active range of motion (ROM) of shoulder abduction, external rotation, and flexion were measured by goniometry. Beck Depression Inventory (BDI) was used to measure the severity of depression before the procedure. All measurements were recorded at baseline and 1, 3, and 6 months after the procedure.

Results: Baseline characteristics were similar in both groups. There was no statistical difference in VAS scores between the two groups at baseline, 1st, and 3rd months. However, in the 6th months, the VAS scores of patients treated with steroids plus ozone were significantly lower than those of patients treated with steroids ($P<0.001$). Both groups showed significant improvements in SPADI pain, disability, and total subscores compared to pre-treatment values ($P < 0.001$). There was a significant improvement in the ROM of the shoulder joint in both groups ($p<0.001$). However, patients who received ozone and steroid treatments showed a significantly greater increase in SPADI and ROM of shoulder joints in the 6th months ($p<0.001$). There was a positive correlation between BDI score and pain duration, and the severity of depression had no statistically significant effect on VAS scores.

Conclusion: Results of this study revealed that triple shoulder injection with steroids or a combination of steroids and ozone proved to be an effective therapeutic approach for patients suffering from shoulder pain and limited mobility. The combination of ozone with steroids may lead to better results than using steroids alone. Furthermore, a long duration of pain increases the risk of chronic depression in patients.

Keywords: Shoulder pain, Shoulder joint, Ozone treatment, Lumbar epidural steroid

© 2024, European Journal of Therapeutics, Gaziantep University School of Medicine.

This work is licensed under a Creative Commons Attribution-NonCommercial 4.0 International License.

INTRODUCTION

Shoulder pain, often caused by repetitive or excessive activities, is a common musculoskeletal disorder with a lifetime prevalence of 61% [1]. It's often associated with a decreased range of motion. [2]. Common causes of shoulder pain are osteoarthritis of the glenohumeral or acromioclavicular joint, adhesive capsulitis, tendinitis, bursitis, synovial impingement, and rotator cuff tears [3]. Treatments aim to restore shoulder movements, reduce the patient's pain, and usually require a multimodal approach. Initial treatment includes analgesics, anti-inflammatory drugs, and physical therapy. If pain relief is inadequate, other minimally invasive treatments are used. Fluoroscopy-guided triple joint injection is a shoulder intervention technique that includes injection of steroid and local analgesic mixture into the glenohumeral joint, subacromial-subdeltoid bursa, and acromioclavicular joint in a single session by entering from the AC joint [4]. Steroid injection could be effective even in advanced patients. The disadvantage is that the steroid has a relatively short duration of therapeutic action and is often not reproducible due to the potential risk of osteoporosis, osteonecrosis, and infection [5,6].

In recent years, ozone therapy has started to be used in the treatment of musculoskeletal disorders, low back pain, lumbar disc herniation, and osteoarthritis especially in the knee. Ozone provides controlled activation of antioxidant systems, increases blood flow, and thus increases oxygenation and the release of growth factors and cytokines. Intra-articular ozone injection has emerged as an alternative to steroids since it is effective, well-tolerated, and without serious side effects [7-9].

The primary objective of this study was to compare the efficacy of triple shoulder injection with steroid alone and the combination of steroid and ozone in patients with shoulder pain and limitation of movement. The secondary aim was also to observe how it affects pain and disability after treatment by analysing the severity of depression.

Main Points

- It has been found that triple shoulder steroid injections with or without ozone showed significant efficacy on shoulder pain and disability, however, treatment outcomes were better in combination therapy.
- This study demonstrates the potential benefits of ozone therapy as an adjunct treatment for improved outcomes.

MATERIALS AND METHODS

The study was performed in accordance with the Helsinki Declaration criteria, after the approval of the ethics committee (decision dated 13.01.2022, No: İ01-01-22) in the Ankara University Faculty of Medicine. Patients' records collected between January and June 2021 were analyzed retrospectively. After reviewing 108 patient files, 38 were excluded due to missing information. Seventy patients, with shoulder pain and range of motion limitation secondary to subacromial-subdeltoid bursitis, glenohumeral, and acromioclavicular joint degeneration, biceps/rotator cuff tears, tendinopathy, glenoid labrum injuries demonstrated on shoulder magnetic resonance image (MRI), were included in the study. In addition, patients whose psychological status was evaluated with the Beck Depression Inventory (BDI) were considered.

Inclusion criteria were patients aged between 30-80 years, body mass index (BMI)<40 kg/m^2, positive shoulder abnormal passive range of motion (ROM), Visual Analog Scale (VAS)>4 shoulder pain for at least 3 months, no causes such as dislocation, subluxation, fracture on the direct radiograph (acute shoulder pain causes) and exclusion criteria were patients younger 30 and older 80 years, coagulation disorder, oral anticoagulant use, pain of cervical origin (excluded by routine cervical MRI and physical examination findings), glucose 6-phosphate dehydrogenase deficiency, and pregnancy.

The same experienced pain medicine specialist performed all injections. Age, gender, BMI, affected side, symptom duration, and smoking of all patients were recorded.

Patients were divided into two treatment groups; steroid (40 mg triamcinolone, 1 ml) in 4 ml saline and steroid plus 15 cc ozone injection at a concentration of 15 µg/ml. In our clinic, the combination of steroids and ozone has been used as a routine treatment for patients experiencing long-term pain and presenting with multiple coexisting MRI findings in patients with chronic nonspecific shoulder pain. Given the recommendation and utilization of intra-articular 5-20 ml ozone injections at a concentration of 5-20 µg/ml in studies, our clinic has preferred 15 cc ozone injection at a concentration of 15 µg/ml.

The procedures were performed in a supine position on the fluoroscopy table. The glenohumeral joint and acromioclavicular joint were visualized in the Anterior-Posterior (A-P) position, and then the 10° oblique position. A 21 G needle spinal needle reached the glenohumeral joint through the acromioclavicular joint and subacromial-subdeltoid bursa, after confirming the needle position with contrast medium (iohexol), injections were performed respectively. Ozone gas was obtained from the ozone generator (Dr J. Hänsler Ozonosan, Iffezheim, Germany) in our clinic. Figure 1 demonstrated the triple shoulder injection during procedure. One group received 3 mL of a mixture of Triamcinolone acetonide and saline into the glenohumeral joint. In addition to the first group, 7 cc ozone was injected into the glenohumeral joint in the other group. Then the needle was withdrawn into the subacromial bursa. It was confirmed by administering 2 mL of contrast medium that the needle was in the subacromial bursa and 1 ml of a mixture of steroid and saline was administered. The other patients received 5cc ozone additionally. The needle tip was withdrawn into the acromioclavicular joint and 1 mL of steroid and saline mixture was injected into the joint. The other patients received 3 cc of ozone into the acromioclavicular joint. For all patients, daily physical therapy was suggested after intervention.

Shoulder pain intensity was assessed using the VAS score. Quality of life and the functional assessment of the patients were evaluated using the Shoulder Pain and Disability Index [SPADI] [10]. These measures were taken from all patients before injection and at 1st, 3rd and 6th months after procedure. VAS scores were also recorded at the 24th hours. Furthermore, BDI [11] was used to assess the severity of depression before the procedure. The study also examined the impact of depression levels on the VAS score and the disability experienced by the participants after six months.

Patients' recorded goniometric measurements of shoulder active ROM of flexion, abduction, and external rotation were also analyzed.

The VAS score for the assessment of pain ranges between 0-10 (min-max pain degree). The SPADI includes a total of 13 questions, related pain severity (5 items) and disability (8 items). The items in the BDI are mainly based on behaviors and symptoms specific to depression and are described in a series of sentences, and each sentence is numbered from 0 to 3.

The primary and secondary outcomes were compared with the baseline and between the two groups.

Statistical Analysis

Data were presented as mean ± standard deviation (SD) and minimum-maximum or number and percentage (n, %) as appropriate. Normality analysis was performed using the Shapiro-Wilk test, skewness-curvature, and histograms. Normally distributed variables are presented as mean and SD Numerical dependent variables were compared between groups using independent samples T-test and Mann-Whitney U test. The Mann–Whitney U test was used to assess nonparametric continuous variables. Categorical variables were compared using the Chi-squared test. Repeated measures were analyzed

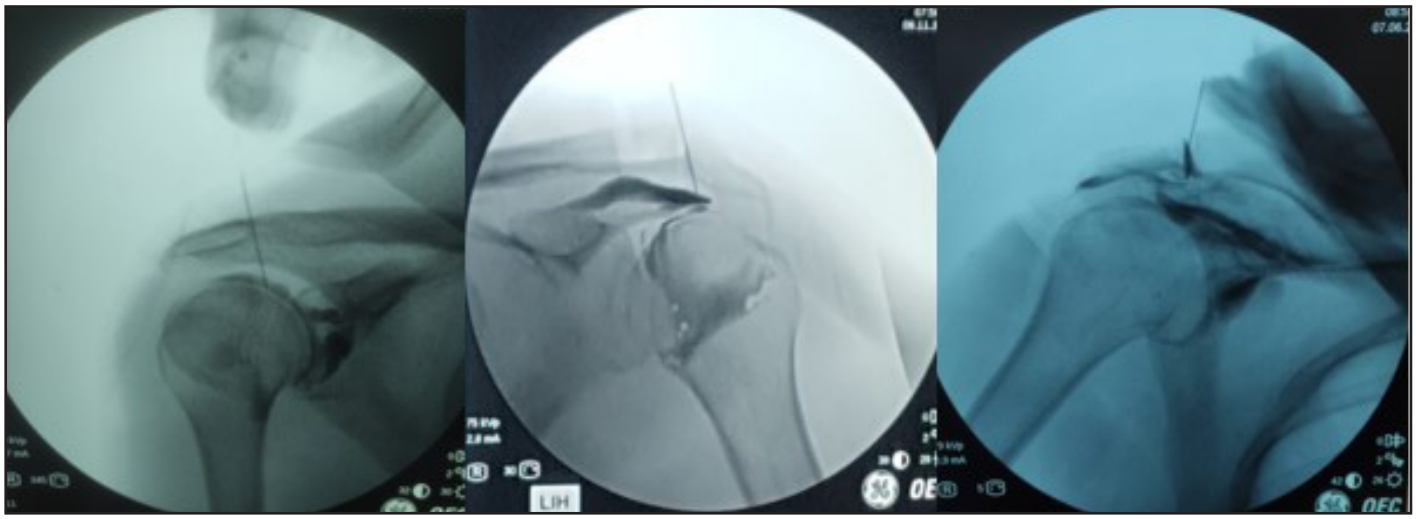

Figure 1. Fluoroscopy-guided Triple Shoulder Injection

using Friedman and Wilcoxon tests. Changes over time were compared using the Bonferroni correction. The Jamovi project (2022, Jamovi version 2.3, computer software) was used for statistical analysis, and $p<0.05$ was considered statistically significant.

RESULTS

The study involved 70 patients who received triple shoulder injections with triamcinolone or combination of triamcinolone and ozone. There was no difference between the patients in age, gender, BMI, smoking status, pain duration, baseline VAS, SPADI total, and BDI scores. Detailed demographic and clinical characteristics of the patients in each group were presented in Table 1.

There was no correlation between VAS values at all times and age, gender, BMI, smoking status, pain duration, and BDI scores.

There was a positive, moderate correlation between pain duration and BDI score (Pearson correlation $r=0.602$, $p<0.001$).

Table 2 showed the distribution of patients according to MRI findings and Table 3 showed changes in baseline VAS and SPADI subscores at 1, 3, and 6 months. Although multiple MRI findings coexisted in most patients, not all findings in one patient were symptomatic.

No difference was found in the patients' VAS scores between the two groups at 1 and 3 months. After 6 months of treatment, it was observed that the patients who received ozone in addition to steroids showed significantly lower VAS scores than the group receiving only steroids ($p<0.001$). However, both groups showed significant improvement in their VAS scores in six months (both $p<0.001$).

Although the decrease in SPADI pain, disability, and total subscores in both groups over time was statistically significant ($p<0.001$), there were statistically significant changes in favour of the patients who received ozone and steroid injection in the 3rd and 6th months as shown in Table 3.

The active ROM values of both groups showed a statistically significant increase compared with the baseline for all time points, however, this improvement was especially greater in the group receiving combined treatment at the 6th months. The detailed changes in the shoulder range of motion after treatment are shown in Table 4.

No significant complications reported in the patients, while 5 patients receiving combination therapy had a short-term feeling of pressure in the shoulder.

Table 1. Clinical Characteristics of the Patients

		Ozone+Steroid Injection	Only Steroid Injection	P value
		n=35	n=35	
Age (year±STD)		58.71±11.91	59.8±12.25	0.708[a]
Gender (n)	Female	21	20	1.000[b]
	Male	14	15	
BMI		26.08(18.3-35.1)	25(16.9-36.6)	0.332[a]
Smoking Status	(+)	10	13	0.611[b]
	(-)	25	22	
Pain duration (Month)		13(3-72)	11(3-36)	0.729[c]
VAS basal		8(5-10)	8(6-10)	0.966[c]
VAS 24h.		5(1-9)	4(3-7)	0.214[c]
SPADI Total score basal		79.33±8.66	82.19±6.23	0.119[a]
BDI Score		14.34±7.15	15.86±7.22	0.382[a]

STD: Standart Deviation, BMI: Body Mass Index, VAS: Visual Analog Scale, SPADI: Shoulder pain and disability index, BDI: Beck's Depression Inventory, a: Independent Samples T-test, b: Chi-Square test, c: Mann-Whitney U test, d: Wilcoxon signed ranks test

Table 2. Baseline MRI findings

	Steroid and Ozone Injection		Only steroid Injection	
	(n=35)	%	(n=35)	%
Side				
Right	23	65,71	21	60
Left	12	34,28	14	40
AC-joint osteoarthritis	10	28,6	10	28,6
Mild	3	8,6	2	5,7
Moderate	7	20	7	20
Severe	0	0	1	2,85
SA/SD bursitis	13	37,14	15	42,85
Mild	3	8,6	4	11,42
Moderate	6	17,14	7	20
Severe	4	11,42	4	11,42
Partial thickness tear in RC	4	11,42	5	14,3
Full-thickness tear in RC	5	14,3	8	22,85
Tendinosis in RC	2	5,7	2	5,7
Partial thickness tear with/without tendinosis in the long head of the biceps	12	34,3	8	22,85
Full-thickness tear in the long head of the biceps	1	2,85	6	17,14
GH-joint osteoarthritis	18	51,42	15	42,85
Mild	3	8,6	1	2,85
Moderate	12	34,3	10	28,6
Severe	3	8,6	4	11,42
Tear in glenoid labrum	7	20	6	17,14
Small tear	6	17,14	6	17,14
Large tear	1	2,85	0	0

AC acromioclavicular, SA subacromial, SD subdeltoid, RC rotator cuf, GH glenohumeral

Table 3. The changes in baseline VAS and SPADI subscores at 1, 3, and 6 months

	Steroid and Ozone Injection	Steroid Injection	p*
	median(min-max)/mean rank	median(min-max)/mean rank	
VAS basal	8(5-10)/4	8(6-10)/4	0.966
VAS 1m	4(2-8)/1.8	4(3-6)/1.46	0.499
VAS 3m	4(2-7)/1.84	4(3-6)/1.67	0.067
VAS 6m	4(3-7)/2.36	6(4-7)/2.87	**<0.001**
p**	**<0.001**	**<0.001**	
S.Pain score basal	80(60-90)/4	78(66-92)/3.81	0.773
S.Pain score 1m	44(28-74)/1.6	46(32-58)/1.4	0.110
S.Pain score 3m	48(22-70)/1.87	54(32-78)/1.9	**0.041**
S.Pain score 6m	54(28-70)/2.53	70(40-82)/2.89	**0.004**

p**	**<0.001**	**<0.001**	
S.Disab. score basal	82.5(55-97)/4	85(67.5-93-7)/4	0.091
S.Disab. score 1m	42.5(18.7-80)/1.8	43.7(26.2-56.2)/1.34	0.529
S.Disab. score 3m	43.7(28.7-72.5)/1.8	48.7(25-5-68.7)/2.06	**0.004**
S.Disab. score 6m	47.5(37.5-72.5)/2.36	55(41.2-81.2)/2.6	**<0.001**
p**	**<0.001**	**<0.001**	
S.Total score basal	81.5(59.9-93)/4	81.5(68.4-93)/4	0.264
S.Total score 1m	42.2(23-77.6)/1.67	43.8/33-56.1)/1.37	0.210
S.Total score 3m	44.6(26.1-71.5)/1.8	49.2(37.6-71.5)/1.9	**0.011**
S.Total score 6m	49.2(38.4-71.5)/2.53	59.9(40.7-80.7)/2.73	**<0.001**
p**	**<0.001**	**<0.001**	

p*: Mann-Whitney U Test, p**: Friedmann Test

Table 4. The Changes in the Range of Motion of the Joint over Time and Between the Groups

	Ozone+Steroid Injection	**Only Steroid Injection**	**p***
	median(min-max)/mean rank	**median(min-max)/mean rank**	
Flexion at basal	110(78-176)/1	115(78-168)/1.03	0.557
Flexion at 1. month	155(95-180)/2.14	145(111-175)/2.43	0.284
Flexion at 3. months	165(118-180)/3.16	157(120-173)/3.54	**0.035**
Flexion at 6. Months	168(124-180)/3.70	152(120-172)/3	**<0.001**
p**	<0.001	<0.001	
External rotation at basal	65(36-90)/1.06	58(35-81)/1.10	0.659
External rotation at 1. Month	75(43-90)/2.29	66(45-88)/2.73	**0.010**
External rotation at 3. Months	78(45-90)/3.04	68(49-88)/3.3	**0.001**
External rotation at 6. Months	80(45-90)/3.61	70(42-88)/2.87	**<0.001**
p**	<0.001	<0.001	
Abduction at basal	120(75-170)/1.14	105(162-77)/1.17	0.100
Abduction at 1. Month	137(102-172)/2.04	137(107-164)/2.61	0.545
Abduction at 3. Months	150(110-175)/3.01	148(110-170)/3.56	0.359
Abduction at 6. Months	158(110-180)/3.8	143(102-168)/2.65	**<0.001**
p**	<0.001	<0.001	

p*: Mann-Whitney U Test, p**: Friedmann Test

DISCUSSION

The results of the present study showed that patients who were treated with fluoroscopy-guided triple shoulder injection either with triamcinolone alone or triamcinolone plus ozone demonstrated significant improvement in their VAS scores, SPADI subscores, and active ROM in all three intervals. However, patients who received additionally the ozone injection showed greater improvement. In addition, patients' level of depression did not affect their pain severity and disability.

The healing process of chronic shoulder pain can take a long time to heal especially in untreated patients. Steroid injections are commonly used to reduce pain and facilitate exercise in patients with shoulder pain to increase range of motion. It is

important to know that steroid injections may have local side effects such as infection, cartilage injury, aseptic bone necrosis, tendon rupture, tissue atrophy, fat necrosis, calcification, and depigmentation. Additionally, there are systemic side effects that can occur with the local application of corticosteroids, including impaired glucose tolerance, immunosuppression, osteoporosis, and exacerbation of psychosis [12]. It's important to remember that every medication comes with potential risks but no major side effects related to steroid use were demonstrated during this study.

Ozone, which has no major side effects, is effective in treating inflammatory and degenerative disorders of the musculoskeletal system. It has anti-inflammatory and analgesic effects in the short and long term. Studies have reported the effects of ozone on various conditions including lumbar facet joint syndrome, subacromial bursitis, carpal tunnel syndrome, hip bursitis, shoulder adhesive capsulitis, herniated disc, and temporomandibular joint disorder [13]. Only five patients in the present study reported a temporary sensation of pressure in their shoulders. This indicated that the procedure was generally well-tolerated and safe.

Ozone has multiple benefits for joint health. It reduces oxidative stress, promotes joint repair, increases oxygenation, releases growth factors and cytokines, and inhibits pro-inflammatory cytokines like interferon alpha, TNF-alpha, and ILs [3]. After reviewing the available literature on the use of ozone in treating shoulder disorders, it is evident that most studies have shown the effectiveness of ozone therapy either alone or in combination with steroids. Although there have been limited studies on the shoulder joint, many studies have been conducted on the effects of ozone on knee osteoarthritis [14]. The literature on shoulder pain indicates that ozone therapy has proven to be beneficial for subacromial bursitis, calcific tendinitis, capsulitis, and partial rotator cuff tears [15]. Moreover, some studies have demonstrated the positive effects of ozone therapy on musculoskeletal disorders, both in the short and long term with a single intervention [16]. In our study, we performed the triple shoulder injection technique in a single session and observed long-term treatment efficacy in both treatment groups. While our study did not include patients receiving ozone therapy alone, it might be a promising alternative for patients who cannot receive steroid treatment due to contraindications or intolerable side effects. Furthermore, unlike steroids, ozone therapy is a reproducible treatment with additional advantages.

In a recent study on adhesive capsulitis treatment, Foula et al [17] included three groups of patients who received intra-articular ozone, steroid, and pulse radiofrequency (PRF) injections. The study found that steroid injection showed greater pain relief at rest compared to ozone and PRF, starting from week one after the intervention. However, the ozone and PRF groups had a delayed effect but better VAS scores at week 8 post-intervention. All three intervention modalities showed significant improvement in SPADI, with no significant difference in pain and disability components. In a study conducted by Benvenuti [18], it was reported that a patient suffering from limited joint range of motion and pain was given 10 ml of intra-articular ozone at a concentration of 15 μg/ml. Additionally, 0.5 to 1 ml was injected into the subacromial bursa and the long head of the biceps muscle. This led to a reduction in overall pain and recovery of shoulder function. As in our study, the severity of patients' pain decreased with ozone treatment. However, we did not intend to inject into the bicipital sulcus as was done in the previous study, this indicated that ozone was capable of diffusing throughout the tissue, providing relief beyond the site of injection.

Ghazani et al [6] suggested that although corticosteroids had short-term benefits, they lost their effect in the long term, while ozone had a longer therapeutic effect and improved pain and disability in the longer term. They reported a study of 30 patients with impingement syndrome and found that after injecting a combination of ozone and steroids into the bursa (with or without intra-articular injection), both VAS and SPADI scores improved after 2 weeks and 2 months. There was no significant difference between the range of motion and ultrasound measurements. The corticosteroid was more effective in improving pain and disability scores than a single injection of ozone. After following the patients for 6 months, we observed that both treatment methods showed improvement in the patients' VAS, SPADI, and ROM values. However, patients who received a combination of ozone and steroid injections showed better improvements compared to patients who received steroid alone injections.

To maintain treatment efficacy and ensure long-term clinical improvement, Kara and Gürçay [19] suggested that injections should be repeated one to three times per week. In some studies, patients were given a higher number of injections than in the current study. For instance, Moretti et al [20] evaluated ozone's effectiveness in treating shoulder tendinopathies, and their patients received 10 ml ozone (6-10 μg) at the site of maximum pain and 10 to 15 ml ozone (15-20 μg) for joints. These injections

were given twice a week for a total of 6 sessions for shoulder osteoarthritis. The study also had a control group consisting of 40 patients who were treated with anti-inflammatory mesotherapy. The patients who received ozone injections experienced a greater reduction in the VAS (from 9.4 to 2.9), while in the mesotherapy group, the reduction was from 9 to 6. The study found that ozone treatment was significantly better than anti-inflammatory mesotherapy in improving painful shoulders. In a study conducted by Scarchilli [21], 14 individuals who were suffering from shoulder pain received an injection of ozone into their shoulder joint and subacromial bursa. Patient's pain decreased from 8.5 to 3, and further improved to 1.5 after two months. Furthermore, five weekly injections into the posterior intra-articular or lateral access improved their 2-month mean constant score by approximately 85%.

Corticosteroid injections were found to be effective in treating tendinopathies in the short term, but not in the long term according to Coombs et al [22]. In addition, it has been found that ozone injection was an effective treatment for acute or chronic tendinitis, even in cases where calcium deposits are present [23]. A study by Gjonovich et al [24] used a larger dose of ozone (35 ml) at a concentration of 12-15 μg/ml to treat a painful shoulder complicated by rotator cuff lesions. The study reported 67% positive results with good pain control and excellent recovery of joint function.

In the management of chronic musculoskeletal pain, it is important to consider a psychological approach in addition to pain control. Recent studies have shown that depression, anxiety, and sleep problems are common among individuals with chronic musculoskeletal pain [25]. In contrast, the association between depressive symptoms and functional and symptomatic disability in patients with chronic shoulder pain was poorly understood [26]. In a study of 130 patients (96 with rotator cuff disease, 24 with adhesive capsulitis, and 10 with calcific tendinitis), Cho et al [25] reported a high prevalence of depression, anxiety, and sleep disturbance in patients with shoulder pain for 3 months or longer compared with healthy subjects. The authors suggested that chronic shoulder pain puts patients at risk of developing depression and anxiety. Furthermore, in their study of 76 patients with frozen shoulders, Toprak et al [27]. found a high prevalence and close association between pain, anxiety, and sleep disturbance. The VAS and Beck Anxiety Inventory were significantly higher in the patients with frozen shoulders than in the controls ($p<0.001$). However, there was no significant difference between patients and controls Beck Depression Inventory scores ($p=0.067$). The current study revealed that the BDI scores of patients increased as the duration of pain increased and the level of depression have no impact on the pain and disability. In order to achieve complete treatment, it is crucial to consider the patient's psychological well-being and plan a multimodal treatment approach

It is important to note that structural changes such as degenerative joint changes, subacromial-subdeltoid bursitis, biceps and rotator cuff tendon disorders, and tears, which are demonstrated by shoulder MRI, are prevalent in both symptomatic and asymptomatic patients [3]. It is crucial to keep in mind that a considerable number of patients might experience multiple co-existing disorders concurrently. This means a complex challenge to their diagnosis and treatment.

Limitations

The main limitation of this study was retrospective nature and the small sample size. Additionally, the lack of long-term follow-up (longer than 6 months) of the patients was another limitation. In this study, triple shoulder injections were administered in a single session, were not repeated. There was also no control group that received sham or ozone alone injections in the study. However, the lack of research on the combination of steroid and ozone injections into the shoulder joint, along with the assessment of psychological factors, makes this study special.

CONCLUSION

The results of the study suggested that fluoroscopy-guided triple shoulder injection with both treatments improved patient's VAS, SPADI, and ROM of shoulder joint outcomes at the 6-months follow-up. However, results were in favour of patients treated with combination therapy. This highlights the potential benefits of ozone therapy as an adjunct treatment for improved outcomes and ozone could be an alternative treatment option for patients with shoulder pain. Additionally, the effect of a depressive state on the severity of pain could not be shown at any time. Shortening the duration of pain in patients might also reduce the tendency to depression. Further studies with larger sample sizes and randomized controlled trials with longer follow-ups would be needed to make a definitive decision about the efficacy of triple shoulder injection with steroids plus ozone for short- and long-term pain relief.

Acknowledgment: During the preparation of this work the authors used a program to check grammar mistakes and translate parts of the manuscript. After using this tool/service, the authors reviewed and edited the content as needed and took full responsibility for the content of the publication.

Conflict of interest: None

Funding: This research received no external funding.

Ethical Approval: Ethics Committee of Ankara University Faculty of Medicine [decision dated 13.01.2022, No: İ01-01-22]

Author Contributions: Conception: DB - Design: DB- Supervision: DB,İA - Fundings: -Materials:DB, İA - Data Collection and/or Processing: DB, İA - Analysis and/or Interpretation: DB, İA – Literature Review: DB, İA - Writing: DB,İA - Critical Review: DB, İA

REFERENCES

[1] Carroll MB, Motley SA, Smith B, Ramsey BC, Baggett AS (2018) Comparing corticosteroid preparation and dose in the improvement of shoulder function and pain: a randomized, single-blind pilot study. Am J Phys Med Rehabil. 97:450–455. http://dx.doi.org/10.1097/phm.0000000000000758

[2] Lee SW, Tiu T, Roberts J, Lee B, Bartels MN, Oh-Park M (2018) Point-of-care ultrasonography findings and care use among patients undergoing ultrasound-guided shoulder injections. Am J Phys Med Rehabil. 97:56–61. http://dx.doi.org/10.1097/phm.0000000000000807

[3] Cuce I, Sencan, S, Demir FU, Koc A, Çalış M (2019) Efficacy of fluoroscopy-guided triple shoulder injection for older patients with nonspecific shoulder pain. Eur Geriatr Med 10: 595–602. https://doi.org/10.1007/s41999-018-00159-9

[4] Erdine S (2011) Üçlü omuz bloğu. In: Erdine S (eds), Algolojide Girişimsel Yöntemler. İstanbul, Nobel kitabevi, pp 195-198.

[5] Gaujoux-Viala C, Dougados M, Gossec L (2009) Efficacy and safety of steroid injections for shoulder and elbow tendonitis: a meta-analysis of randomized controlled trials. Ann Rheum Dis. 68:1843–1849. http://dx.doi.org/10.1136/ard.2008.099572

[6] Babaei-Ghazani A, Fadavi HR, Eftekharsadat B, Ebadi S, Ahadi T, Ghazaei F, Khabbaz MS (2019). A Randomized Control Trial of Comparing Ultrasound-Guided Ozone (O2-O3) vs Corticosteroid Injection in Patients With Shoulder Impingement. Am J Phys Med Rehabil. November. 98(11):1018-1025. http://dx.doi.org/10.1097/phm.0000000000001240

[7] Bocci VA (2006) Scientific and medical aspects of ozone therapy. State of the art. Arch Med Res 37:425–435. https://doi.org/10.1016/j.arcmed.2005.08.006

[8] Shanta H, Amruta S (2017). Ozone Therapy: An Excellent Treatment for Various Diseases International. Journal of Pharmacy and pharmaceutical research 10(3), 303-311.

[9] Babaei-Ghazani A, Najarzadeh S, Mansoori K, Forogh B, Madani SP, Ebadi S, Fadavi HR, Eftekharsadat B (2018) The effects of ultrasound-guided corticosteroid injection compared to oxygen–ozone (O 2–O 3) injection in patients with knee osteoarthritis: a randomized controlled trial. Clin Rheumatol. 37:2517–2527. https://doi.org/10.1007/s10067-018-4147-6

[10] Bumin G, Tüzün EH, Tonga E (2008). The Shoulder Pain and Disability Index (SPADI): Cross-cultural adaptation, reliability, and validity of the Turkish version. J Back Musculoskelet Rehabil. 21(1): 57-62. http://dx.doi.org/10.3233/bmr-2008-21108

[11] Kapci EG, Uslu R, Turkcapar H, Karaoglan A (2008). Beck Depression Inventory-II: evaluation of the psychometric properties and cut-off points in a Turkish adult population. Depress Anxiety, 25(10), E104-E110. https://doi.org/10.1002/da.20371

[12] Kamel, SI, Rosas HG, Gorbachova T (2023) Local and Systemic Side Effects of Corticosteroid Injections for Musculoskeletal Indications. Am J Roentgenol. 1-12. https://doi.org/10.2214/AJR.23.30458

[13] Seyam O, Smith NL, Reid I, Gandhi J, Jiang W, Khan SA (2018) Clinical utility of ozone therapy for musculoskeletal disorders. Med Gas Res. Sep 25;8(3):103-110. http://dx.doi.org/10.4103/2045-9912.241075

[14] Atar MÖ, Korkmaz N, Aslan SG, Tezen Ö, Köylü Sinem Uyar, Demir Yasin, Kesikburun S (2023) Comparison of ultrasound-guided subacromial corticosteroid and ozone

(O2-O3) injections in the treatment of chronic rotator cuff tendinopathy: a randomized clinical trial. Korean J Pain 36(1):128-136 http://dx.doi.org/10.3344/kjp.22221

[15] Gurger M, Once G, Yilmaz E, Demir Ş, Calik I, Say Y, Kavakli A, Key S, Gurbuz MU, Bingollu O (2021) The effect of the platelet-rich plasma and ozone therapy on tendon-to-bone healing in the rabbit rotator cuff repair model. J Orthop Surg Res 16(1): 1-9 https://doi.org/10.1186/s13018-021-02320-w

[16] Giurazza F, Guarnieri G, Murphy KJ, Muto M (2017) Intradiscal O2O3: rationale, injection technique,short-and long-term outcomes for the treatment of low back pain due to disc herniation. Can Assoc Radiol J 68:171–177. https://doi.org/10.1016/j.carj.2016.12.007

[17] Foula AS, Sabry LS, Elmulla AF, Kamel MA, Hozien AI (2023) Ultrasound-guided Shoulder Intraarticular Ozone Injection Versus Pulsed Radiofrequency Application for Shoulder Adhesive Capsulitis: A Randomized Controlled Trial. Pain Physician. Jul;26(4):E329-E340. PMID: 37535775.

[18] Benvenuti P (2006) Oxygen-ozone treatment of the knee, shoulder, and hip: A personal experience. Rivista Italiana di Ossigeno-Ozonoterapia 5:135-144. https://sid.ir/paper/655510/en

[19] Kara M, Gürçay E (2020) A Single-Dose Injection of Ozone Is Not an Alternative of Corticosteroid Injection in Shoulder Impingement Syndrome. Am J Phys Med Rehabil. 99(7):e89. http://dx.doi.org/10.1097/phm.0000000000001303

[20] Moretti B, Lanzisera R, Sisti GL, Moretti L, Patella V, Simone C (2005) O2-O3 therapy in tendinopathies and entrapment syndromes. Rivista Italiana di Ossigenoozonoterapia. 4(1):20-29.

[21] Scarchilli A (2008) Indications and limits of intra-articular oxygen-ozone therapy for rotator cuff tendinopathy. Int J Ozone Ther. 7:49–52

[22] Coombes BK, Bisset L, Vicenzino B (2010) Efficacy and safety of corticosteroid injections and other injections for management of tendinopathy: a systematic review of randomized controlled trials. Lancet. 376:1751–1767. http://dx.doi.org/10.1016/s0140-6736(10)61160-9

[23] Ikonomidis S, Iliakis E, Eleftheriadou A, Bratanis D, Thomaidis R (2003) Conservative treatment of acute or chronic tendinitis with oxygen-ozone mixture. A double-blind clinical trial. Rivista Italiana di Ossigeno-Ozonoterapia. 2: 67–71.

[24] Gjonovich A, Girotto L, GF Sattin (2002) L'Ossigeno-Ozonoterapia nella spalla dolorosa. (Article in Italian) Esperienza clinica. Riv Ital Ossigeno- Ozonoterapia 1: 37-40.

[25] Cho CH, Jung SW, Park JY, Song KW, Yu KI (2013) Is shoulder pain for three months or longer correlated with depression, anxiety, and sleep disturbance? J Shoulder Elbow Surg. 22(2): 222-228. https://doi.org/10.1016/j.jse.2012.04.001

[26] Roh YH., Lee BK, Noh JH, Oh JH, Gong HS, Baek GH (2012) Effect of depressive symptoms on perceived disability in patients with chronic shoulder pain. Arch Orthop Trauma Surg 132: 1251–1257. https://doi.org/10.1007/s00402-012-1545-0

[27] Toprak M, Erden M (2019) 'Sleep Quality, Pain, Anxiety, Depression and Quality of Life in Patients with Frozen Shoulder'. J Back Musculoskelet Rehabil. 32(2);287 – 291. http://dx.doi.org/10.3233/bmr-171010

How to Cite;

Bayram D, Asik I (2024) Efficacy of Triple Shoulder Injection with Steroids and Ozone in the Treatment of Chronic Shoulder Pain and Range of Motion Limitation. Eur J Ther. https://doi.org/10.58600/eurjther2227