Bitlis Eren Üniversitesi Fen Bilimleri Dergisi
BİTLİS EREN UNIVERSITY JOURNAL OF SCIENCE
ISSN: 2147-3129/e-ISSN: 2147-3188
VOLUME: 11 NO: 9 PAGE: 1102-1111 YEAR: 2022
DOI: 10.17798/bitlisfen.1179758

Histological Evaluation of Spleen and Thymus of Acomys cilicicus

Hatice MUTLU EYİSON[1*], Seda KIRALP[2], Nesrin ÖZSOY ERDAŞ[1], Suna CEBESOY[1]

[1]*Ankara University/Faculty of Science*
[2]*Girne American University/Faculty of Health Sciences*
(ORCID: 0000-0002-4637-5268) (ORCID: 0000-0002-9431-9180) (ORCID: 0000-0002-0470-3745) (ORCID: 0000-0001-7484-2882)

Keywords: *Acomys cilicicus*, Thymus, Spleen, Histology

Abstract

Acomys cilicicus (Turkish Spiny Mouse), a species of the genus *Acomys*, which is the first mammal to have regeneration ability and attracts attention with its spiny-like structure, is only found in a small area near Silifke in Turkey. In recent years, species in the genus *Acomys* have been examined histologically due to their regeneration abilities. Although there are studies on the taxonomy of that species, there are not enough studies on the histology of its tissues. The overall goal of this study is to evaluate the available histomorphological data and document the normal microscopic features of the spleen and thymus tissues in *A. cilicicus*. In this study, adult spiny mice (n=3, 2 males and one female) were examined. All tissues obtained from those samples were fixed in 10% formalin and embedded in paraffin. Periodic Acid Schiff (PAS), Masson's trichrome, Gomori's silver impregnation, and Hematoxylin and Eosin (H&E) were used for staining the sections. Histological examination was carried out using light microscopy. Histological data of the spleen and thymus tissues of *A.cilicicus* were reported in detail.

1. Introduction

The genus *Acomys* is distributed in Africa, the Middle East, and southwest Asia. The number of species belonging to the genus *Acomys* has changed due to taxonomic studies. The genus has 21 species according to the IUCN Red List of Threatened Species (2022-1 version) which provides a comprehensive description of the habitat and geographic range of the genus *Acomys*, *(A. airensis, A. cahirinus, A. cilicicus, A. cineraceus, A. dimidiatus, A. ignitus, A. johannis, A. kempi, A. minous, A. mullah, A. nesiotes, A. percivali, A. russatus, A. seurati, A. spinosissimus, A. wilsoni, A. louisae, A. subspinosus, A. ngurui, A. selousi, A.muzei)* [1]. However, taxonomic research regarding the genus is still problematic [2]-[6].

The genus *Acomys*, which has the ability of regeneration within the mammalian class, has been utilized to analyze a number of topics such as physiology (especially adaptations to desert habitats), behavior, ecology, evolution, and metabolism [7]. These studies have led to the use of this genus as a model organism for the treatment of some human diseases. Recent studies have mostly focused on the study of diabetes, menstrual cycle, prenatal development, and regeneration [8]-[12].

The cells that are able to develop into a variety of cells are stem cells, and these cells form the immune system. In order for these cells to become immunologically active, they must first differentiate and develop in the primary lymphoid organs. After completing their development, B and T lymphocytes are directed to specific locations in the secondary lymphoid organs. As effector cells, these cells interact with the antigen and produce humoral and cellular immune responses [13].

The thymus, the primary lymphoid organ, develops in rodents from the endoderm of the third and fourth pharyngeal pouches and is surrounded by

*Corresponding author: hmutlu@science.ankara.edu.tr
Received: 24.09.2022, Accepted: 08.11.2022

the mesenchyme [14]. Immediately after birth, it grows significantly as a response to postnatal antigen stimulation and the requirement for large numbers of mature T cells. Both the rate and age of onset of thymus dependent immunological function are affected by genetic factors. Also, the same factors influence the size of the thymus. In rats and mice, the thymus reaches its largest magnitude by sexual maturity and then involutes gradually [15]. Thymus has an important role in the immune response against infections [16]. Efficient functioning of the thymus is critical for establishing and maintaining effective adaptive immunity [17].

The spleen is a secondary peripheral lymphoid organ that is located in the left-upper part of the abdominal cavity between the diaphragm and the fundus of the stomach. It is also located below the 9th and11^{th} costae under the left side of the diaphragm and is characterized by its dark red-blue-black color [18]. The spleen is one of the major organs responsible for vital functions in the systemic circulation, especially in the breakdown of erythrocytes and the recirculation of lymphocytes. Therefore, it is a lack of afferent lymphatic vessels. Functionally and morphologically, it consists of two parts, red pulp and white pulp. Both damaged erythrocytes and foreign materials are filtered from blood by the red pulp. Besides, platelets, erythrocytes, and iron are stored in the red pulp. The spleen is not only an area of hematopoiesis in rodents, especially in the fetal and neonatal period but also it includes about one-fourth of the body's lymphocytes and starts immune responses to blood-borne antigens. The white pulp contains T and B cells. It is located around the central arterioles [19]-[22].

Even though research on the immune system of spiny mice was limited [23], studies on this subject increased after the discovery of their regeneration ability. Besides, how the immune response to injury contributes to tissue regeneration is not well understood [24]-[26]. The aim of this study is to evaluate the available histomorphological data and document the normal microscopic features of the spleen and thymus tissues in *A. cilicicus*. Also, the thymus and spleen of the species were analyzed histologically in detail for the first time.

2. Material and Method

The spiny mouse specimens were obtained from the project that was titled "Taxonomy, Biology and Distribution of Spiny Mouse" (Project number: 2003 07 05 074 and funded by the Scientific Research Project Coordination Unit of Ankara University). In total, three adult lab grown specimens (2 male and one female) were used. Animals were fed a diet of assorted seeds, supplemented with fresh apples, corn, or carrots weekly. These specimens were kept on a 13/11 h light/dark cycle and under standard laboratory conditions.

Histological analysis: Samples were processed using routine histological protocols. Spleen and thymus tissue samples were dissected from specimens and then fixed in neutralized buffered formaldehyde solution (10%), dehydrated in alcohol, and embedded in paraffin wax, and transverse sections (5 µm thick) were prepared and mounted on slides. The slides were stained with Gomori's silver impregnation, Masson's Trichrome, Periodic Acid Schiff (PAS) and Hematoxylin and Eosin (H&E). The stained slides were examined using a light microscope (Leica DM LS2) and photographed (Leica DFC320).

3. Results and Discussion

According to the histological analysis of the thymus with H&E staining, the thymus is surrounded by a fibro-adipose tissue containing fibroblasts and adipocytes, and its two lobes are attached to each other by this fibro-adipose tissue. Each lobule contains a thin capsule and septa that reach the inner space between lobules inside the capsule. Each lobule is formed by the cortex, which is seen as a dark-colored area, and the medulla, which is seen as a light-colored area at the inner side (Figure 1A). There are plenty of tightly bound lymphocytes and a few epithelial cells dispersed in the cortex. However, it is found that there are more epithelial cells in the medulla than in the cortex. There are vascular structures of various diameters, enclosed with endothelial, and containing blood tissue in their lumen (Figure 1B).

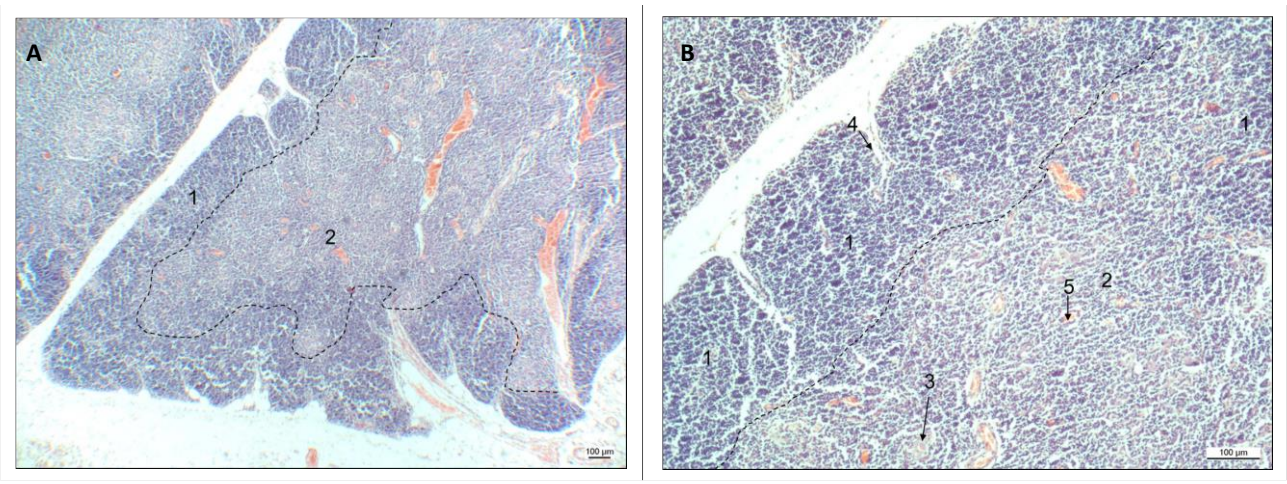

Figure 1 (**A**). Photomicrograph of H&E-stained thymus section to show the general structure of organ, 1- cortex, 2-medulla (**B).** 1- cortex 2-medulla 3- Hassall's corpuscles, 4-septum, 5- venule

In the medulla, although the number of lymphocytes is low compared to the cortex, their size and appearance are similar to those in the cortex. Epithelial reticular cells are high in number compared to the cortex, but their histological characteristics are similar. The medulla contains Hassall's corpuscles of various shapes and numbers, and their colors are varied from light to dark purple (Figure 2).

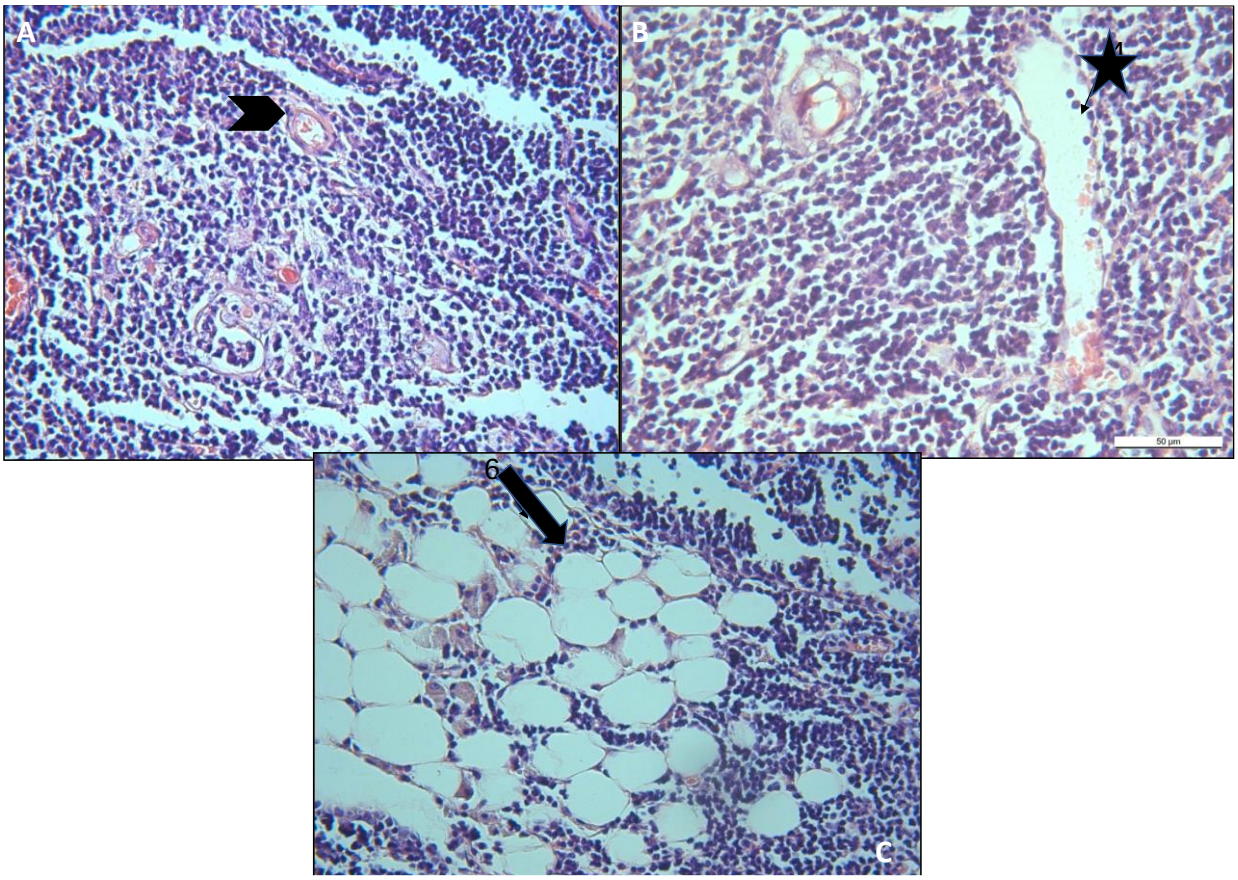

Figure 2. Thymus stained with H&E, Hassall's corpuscles (A), septum (B), adipocytes (C) (Bar indicates 50 µm)

The difference between the cortex and the medulla is observed by using Masson's Trichrome staining. Both of them are pink, but the modular area is lighter colored. It is also observed that fibrous connective tissue, septa, and vein walls are light blue (Figure 3)

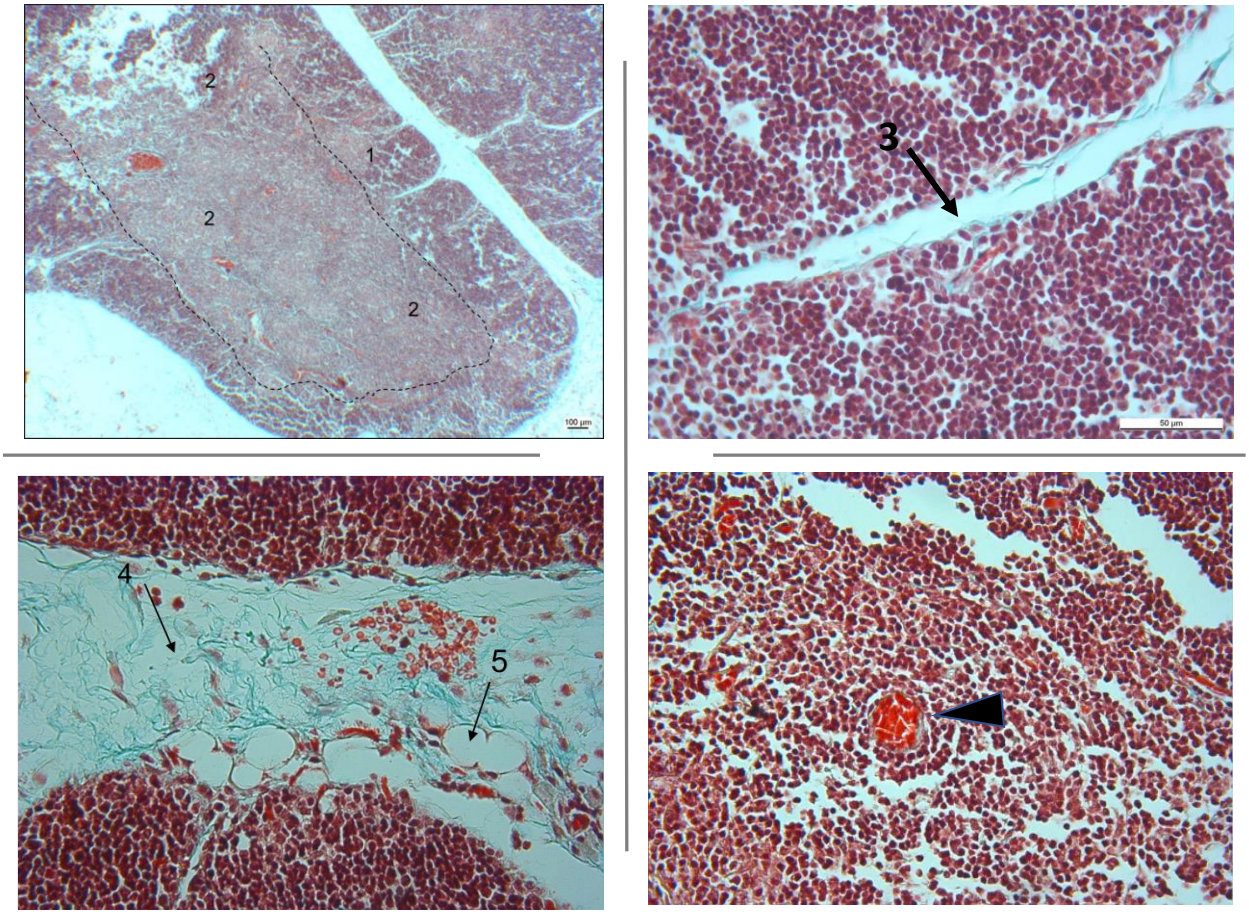

Figure 3. Thymus stained with Masson's Trichrome 1-Cortex, 2-Medulla, 3-septum, 4- fibrous connective tissue, 5-adipocyte, arrow- blood vessel

Cortex and medulla are differentiated from each other using PAS, where cortex is dark blue colored and medulla is light blue colored. Dark pink-colored PAS (+) plasmacytoid cells are seen loosely in the medulla and cortex (Figure 4)

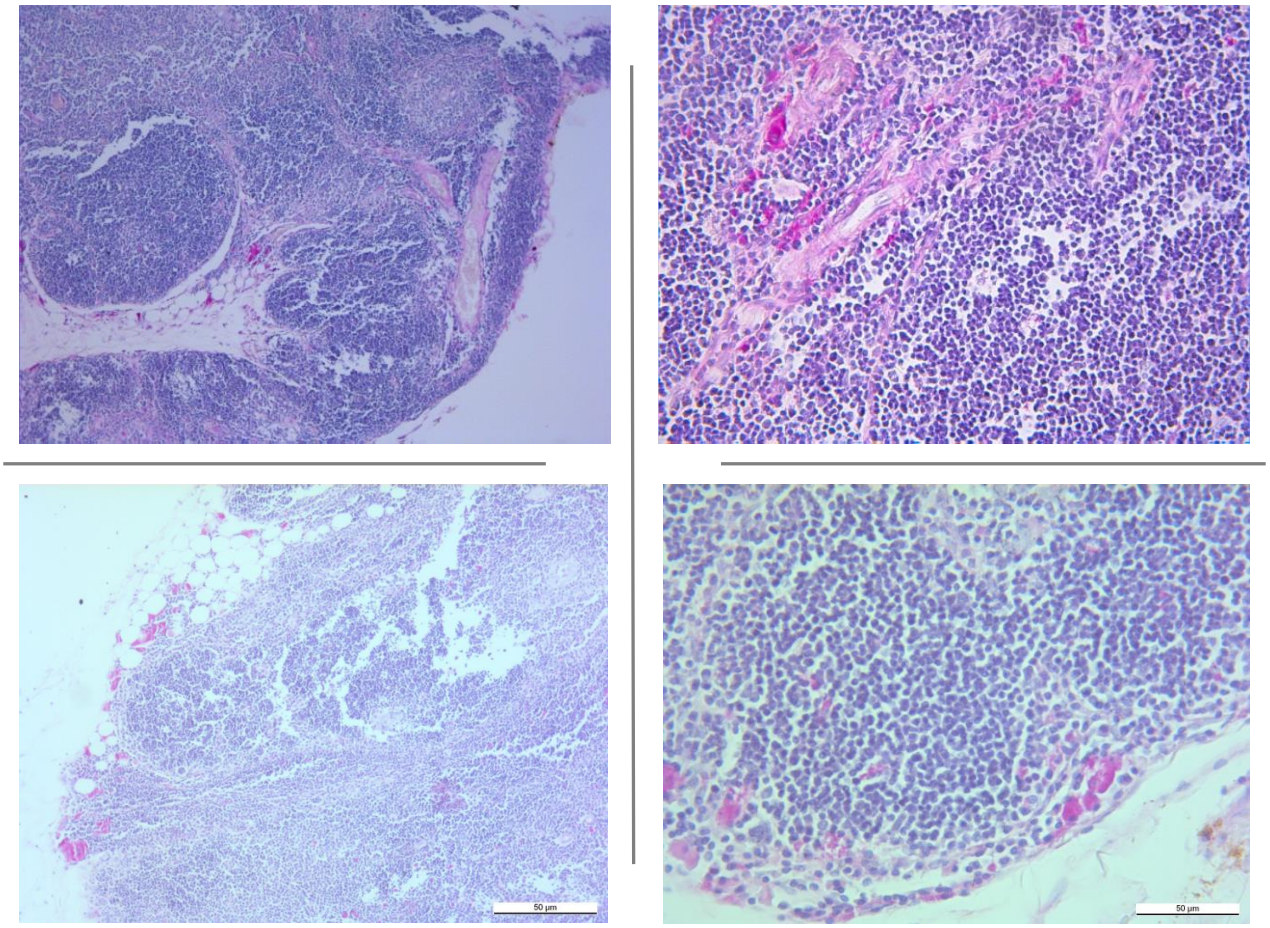

Figure 4. Photomicrograph of PAS-stained thymus section to show the general structure of organ

Gomori's silver impregnation staining gives a result like dark brown cortex and a light brown medulla. Epithelial reticular cells are observed as grey cells with indistinguishable cytoplasmic borders. Extensions of reticular cells are long thin black fibrils which are more in the medulla than in the cortex. Fibrous connective tissue capsule enclosing the organ and septa is observed as dark brown fibrils (Figure 5).

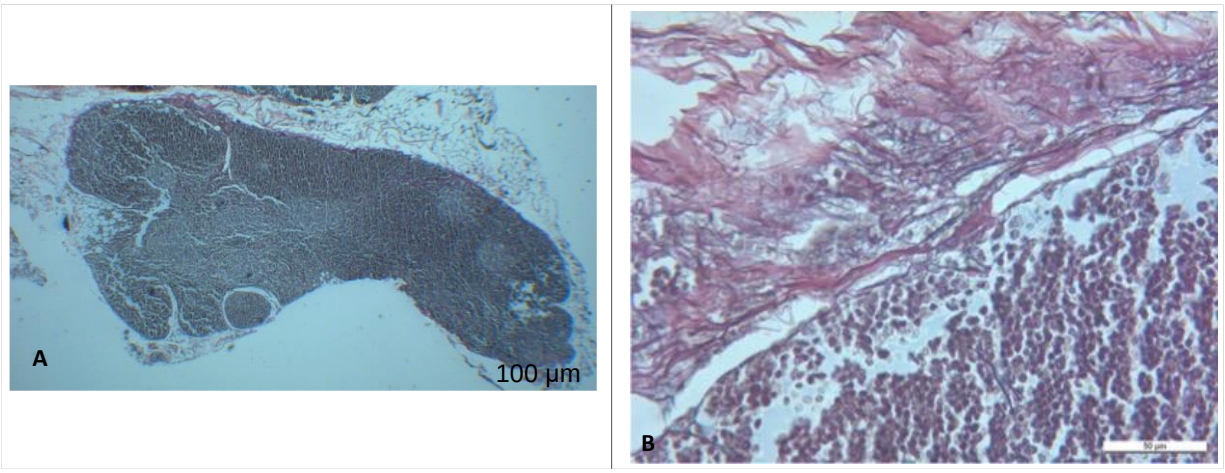

Figure 5. (A) Photomicrograph of Gomori's silver impregnation stained thymus section to show the general structure of organ, (B) reticular fibrils

The spleen's H&E staining revealed that it was surrounded by a capsule composed of connective tissue and the trabeculae gradually thinned into the spleen (Figure 6). White pulp is surrounded by the red pulp in the spleen tissue, and sinuses and trabeculae can be seen between the cells. White and red pulps are separated from each other by the marginal zone (Figure 7). The micrographs, stained with PAS, Masson's Trichrome, and Gomori's silver impregnation, revealed the general structure of the organ (Figure 8). Trabeculae are located between cells in the red pulp. PAS staining of the trabecular arteries of the cell wallsresulted in PAS (+) reaction. The connective tissue of the trabeculae was stained blue with Masson's Trichrome (Figure 9). Reticular fibers are stained with PAS (+) and silver due to their glycoprotein content. In this study, it was found that reticular fibers were quite common in tissues stained with Gomori's silver impregnation (Figure 10).

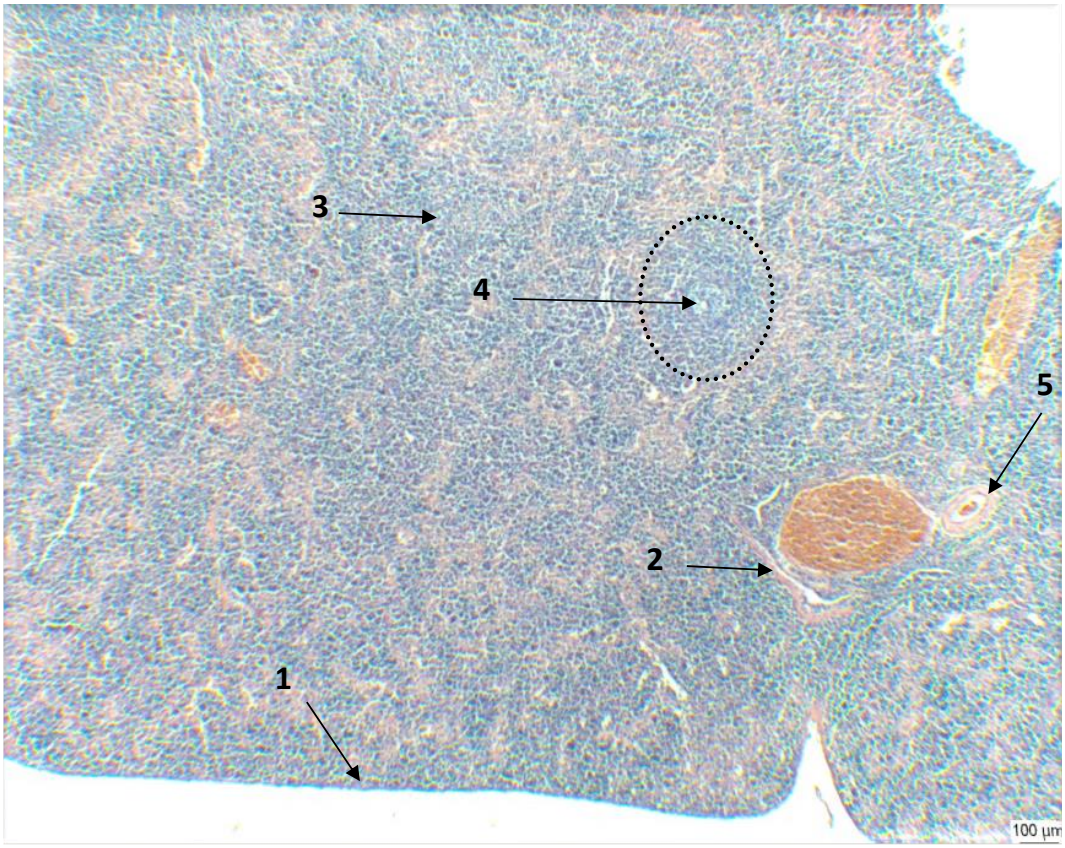

Figure 6. Photomicrograph of H&E-stained spleen section to show the general structure of the organ. 1-capsule, 2-trabeculae (connective tissue), 3-red pulp, 4-lymphoid follicle (white pulp), 5- central arteriole

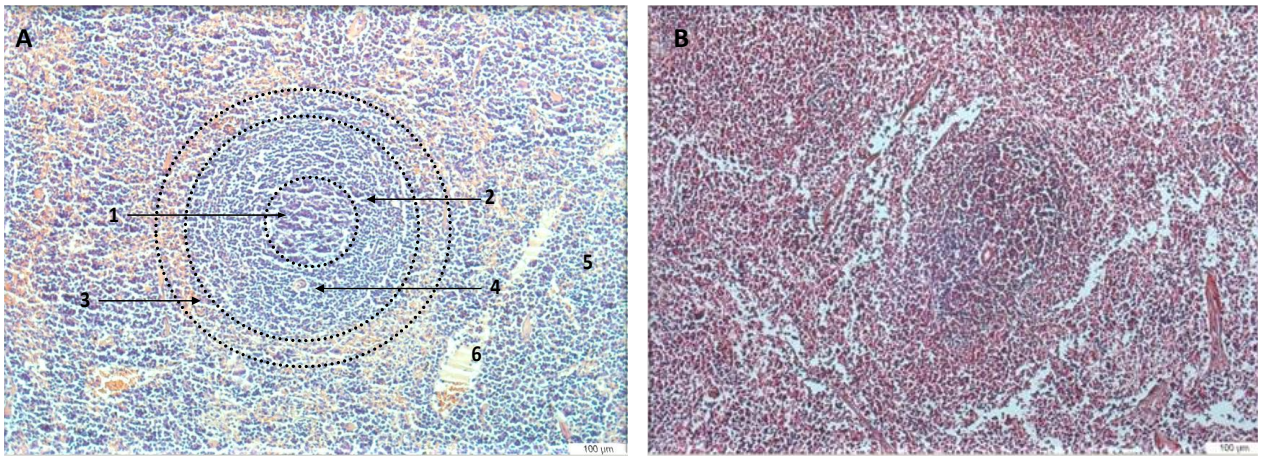

Figure 7. Photomicrograph of the spleen, showing a white pulp surrounded by a red pulp. (A) H&E stained. Bar=100µm. 1-germinal center of the follicle, 2-mantle zone of the follicle, 3-marginal zone of the follicle, 4-central arteriole, 5-red pulp, 6-trabeculae; (B) Masson's Trichrome stained

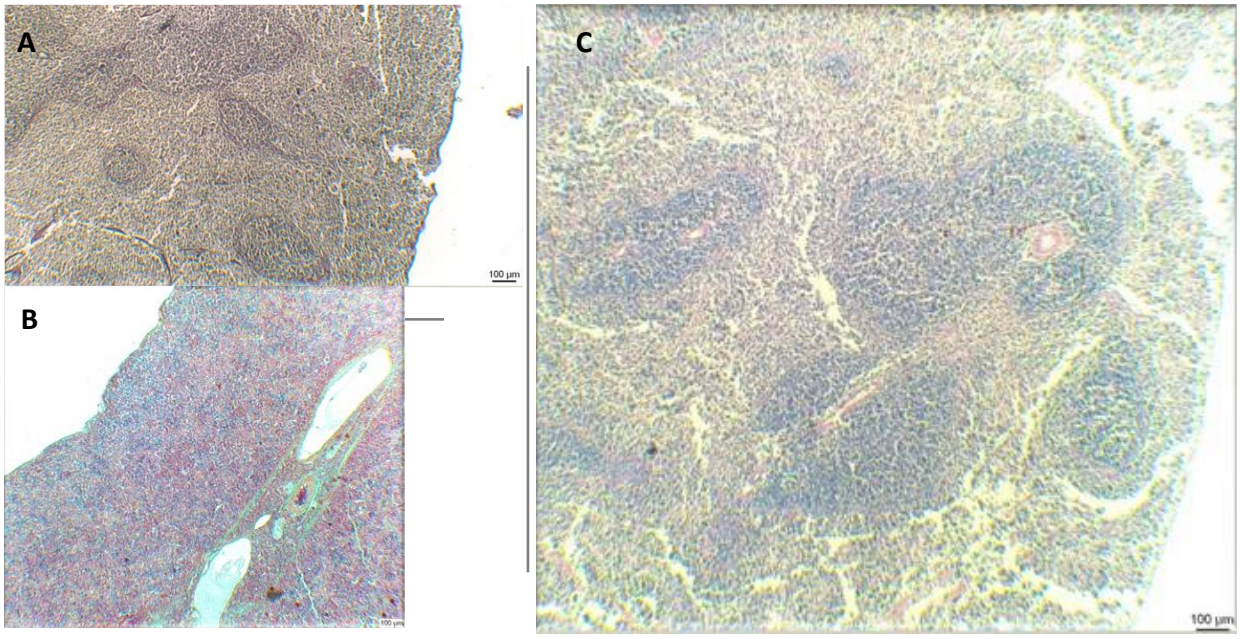

Figure 8. General structure of the white and red pulp in the spleen with different staining. (A) Gomori's silver impregnation, (B) Masson's Trichrome and (C) Periodic Acid Schiff (PAS)

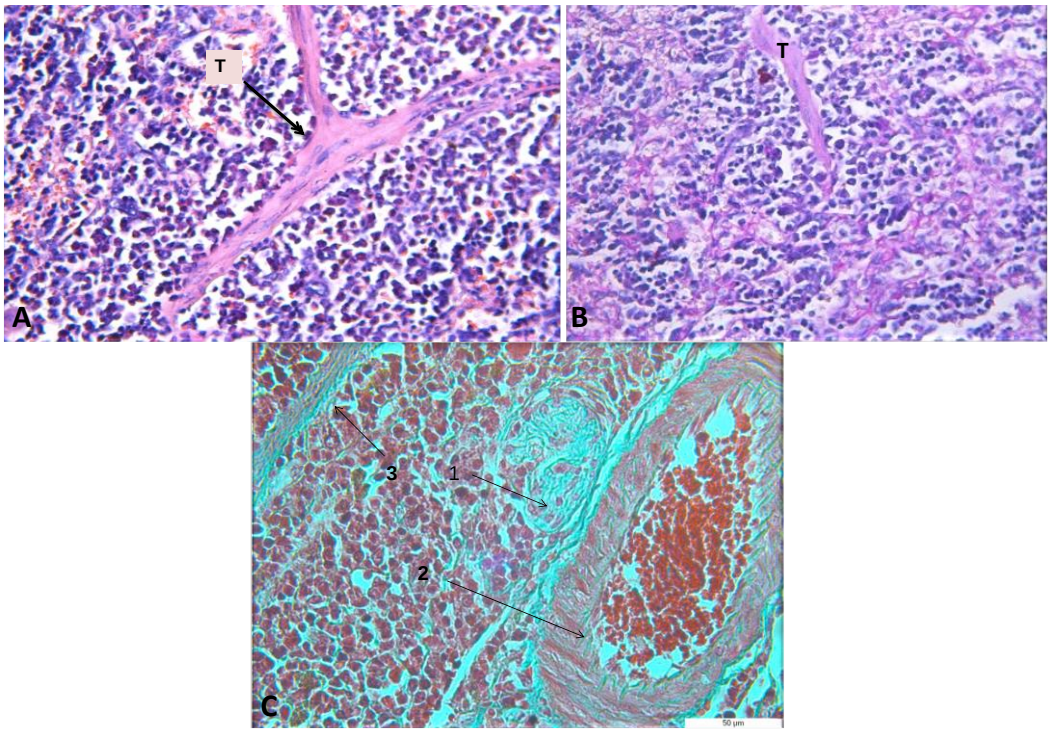

Figure 9. Photomicrograph of splenic trabeculae of spleen with different stains, A: H&E-(x400); B: PAS; C: Masson's Trichrome and 1- central arteriole, 2- vein, 3- trabecula. Bar indicates 50 µm

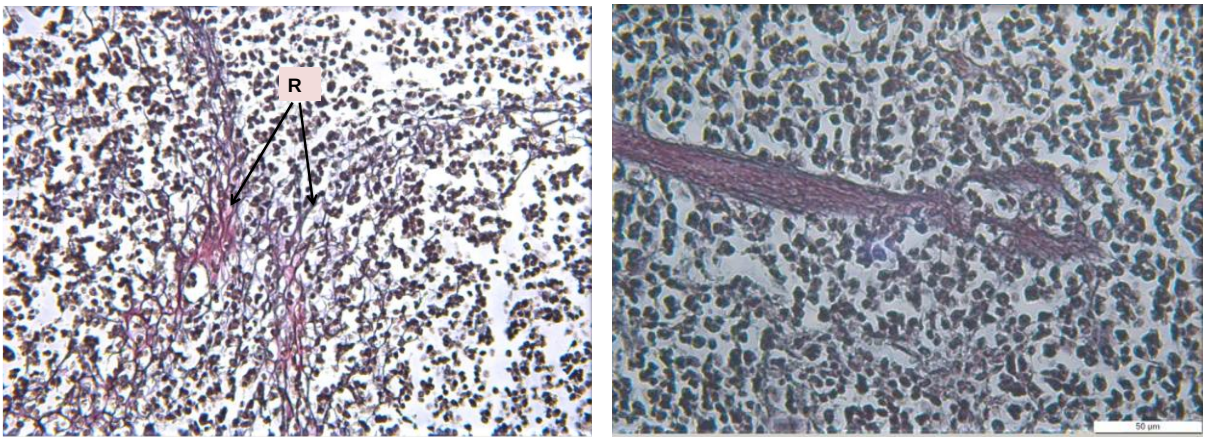

Figure 10. Photomicrograph of the network of splenic reticular fibers (R-reticular fibers x400). Gomori's silver impregnation-stained section

3.4. The Conclusion and Suggestions

Despite not being a laboratory animal, *Acomys* species have been used in numerous studies on physiology, ecology, evolution, behavior, and metabolism. They have also recently gained attention for their remarkable abilities in organ and tissue regeneration. These studies have led to the use of *Acomys* species as a model organism in the treatment of various human diseases. In order to understand the mechanisms that regulate regeneration, there are studies on the thymus and spleen cells of *Acomys* [23]- [26]. However, there are no histological studies on these organs of *Acomys*. *Acomys cilicicus* distributes only in a small area, which is formed with sparse limestone rock blocks, near Silifke in Turkey.

Although *Acomys cilicicus* is in the DD category in the "IUCN Red List" evaluation, this species is now considered to be endangered due to the destruction of its habitat, [27],[28].

In this study, the histomorphological structures of the thymus and spleen tissues, which play an important role in the immune system of the species, were examined using different histological stains. This study is important in terms of revealing the first histological data of the species.

Acknowledgment

We thank to Prof. Dr. Erkut Kıvanç for supplying the *Acomys cilicicus* samples for this study.

Contributions of the Authors

Conceptualization and supervision: HME, SK, NÖE, and SC. Methodology: NÖE. Investigation: HME, SK, NÖE, and SC. Writing—original draft: HME and SK. Writing—review & editing: HME and SC. Visualization: HME. All authors contributed to the article and approved the submitted version.

Conflict of Interest Statement

There is no conflict of interest between the authors. This Article was presented in part as a poster at the 34th FEBS Congress Life's Molecular Interactions, “Histological Analysis of Spleen of *Acomys cilicicus*” and “Histological Analysis of Thymus of *Acomys cilicicus*” Prague, Czech Republic, 4-9 July 2009.

Statement of Research and Publication Ethics

The study is complied with research and publication ethics. The samples of this article obtained from the project that was titled as “Taxonomy, Biology and Distribution of Spiny Mouse” (Project number: 2003 07 05 074) and funded by Scientific Research Project Coordination Unit of Ankara University. No additional animals were killed for this study

References

[1] The IUCN Red List Threatened Species, (September 2022 online: https://www.iucnredlist.org/search?query=acomys&searchType=species)

[2] P. O., Barome, V., Volobouev, M., Monnerot, J. K., Mfune, W., Chitaukali, J. C., Gautun and C Denys, "Phylogeny of *Acomys spinosissimus* (Rodentia, Muridae) from north Malawi and Tanzania: evidence from morphological and molecular analysis." Biological Journal of the Linnean Society vol. 73 (3), pp. 321-340, 2001.

[3] S. J., Steppan, R. M., Adkins, P. Q., Spinks and C., Hale, "Multigene phylogeny of the Old World mice, Murinae, reveals distinct geographic lineages and the declining utility of mitochondrial genes compared to nuclear genes." Molecular phylogenetics and evolution vol. 37(2), pp. 370-388, 2005.

[4] D., Frynta, K., Palupčíková, E., Bellinvia, P., Benda, H., Skarlantova, L., Schwarzova and D., Modrý, "Phylogenetic relationships within the cahirinus-dimidiatus group of the genus *Acomys* (Rodentia: Muridae): new mitochondrial lineages from Sahara, Iran and the Arabian Peninsula." Zootaxa vol. 2660 (1), pp. 46-56, 2010.

[5] P. H., Fabre, L., Hautier, D., Dimitrov and E. J., Douzery, "A glimpse on the pattern of rodent diversification: a phylogenetic approach." BMC evolutionary biology vol.12 (1), pp. 1-19, 2012.

[6] S., Renaud, E. A., Hardouin, P., Chevret, K., Papayiannis, P., Lymberakis, F., Matur,... and G. P., Mitsainas, "Morphometrics and genetics highlight the complex history of Eastern Mediterranean spiny mice." Biological Journal of the Linnean Society vol.130 (3), pp. 599-614, 2020.

[7] G., Pinheiro, D. F., Prata, I. M., Araújo and G., Tiscornia, "The African spiny mouse (*Acomys* spp.) as an emerging model for development and regeneration." Laboratory animals vol. 52(6), pp. 565-576, 2018.

[8] A. E., Gonet, W., Stauffacher, R., Pictet and A. E., Renold, "Obesity and diabetes mellitus with striking congenital hyperplasia of the islets of Langerhans in spiny mice (*Acomys cahirinus*)." Diabetologia vol. 1(3), pp.162-171, 1966.

[9] E., Shafrir, Z., Ehud and K. Rony "Nutritionally induced diabetes in desert rodents as models of type 2 diabetes: *Acomys cahirinus* (spiny mice) and Psammomys obesus (desert gerbil)." ILAR journal vol. 47(3), pp. 212-224, 2006.

[10] B. A., O'Connell, K. M., Moritz, D. W., Walker and H., Dickinson, "Sexually dimorphic placental development throughout gestation in the spiny mouse (*Acomys cahirinus*)." Placenta vol. 34(2), pp. 119-126, 2013.
[11] N., Bellofiore, S. J., Ellery, J., Mamrot, D. W., Walker, P., Temple-Smith and H., Dickinson, "First evidence of a menstruating rodent: the spiny mouse (*Acomys cahirinus*)." American journal of obstetrics and gynecology vol. 216(1), pp. 40-51, 2017.
[12] M., Maden, and J. A. Varholick. "Model systems for regeneration: the spiny mouse, *Acomys cahirinus*." Development vol. 147(4), dev167718, 2020.
[13] H.-Ü., Lüleyap. *Moleküler genetiğin esasları*. Nobel Kitabevi, 2008.
[14] C.-D., Dijkstra, and T., Sminia. "Normal anatomy, histology, immunohistology, ultrastructure, rat." Hemopoietic System. Springer, Berlin, Heidelberg, pp.249-256, 1990.
[15] G., Pearse. "Normal structure, function and histology of the thymus." Toxicologic pathology vol. 34(5), pp. 504-514, 2006.
[16] P., Thapa, and D. L., Farber. "The role of the thymus in the immune response." Thoracic surgery clinics vol. 29(2), pp. 123-131, 2019.
[17] J.-F., Miller. "The function of the thymus and its impact on modern medicine." Science vol. 369 (6503), eaba2429, 2020.
[18] P., Losco. "Normal development, growth and aging of the spleen." Pathobiology of the aging rat, pp. 75-93, 1992.
[19] C. F., Kuper, C., Ruehl-Fehlert, S. A., Elmore and G. A., Parker, "Immune system." Haschek and Rousseaux's handbook of toxicologic pathology. Academic Press, pp.1795-1862, 2013.
[20] P., Balogh, G., Horváth, and A. K., Szakal. "Immunoarchitecture of distinct reticular fibroblastic domains in the white pulp of mouse spleen." Journal of histochemistry & cytochemistry vol. 52(10), pp. 1287-1298, 2004.
[21] M. A., Nolte, R., Arens, M., Kraus, M. H., van Oers, G., Kraal, R. A., van Lier and E. R., Mebius, "B cells are crucial for both development and maintenance of the splenic marginal zone." The Journal of Immunology vol.172(6), pp. 3620-3627, 2004.
[22] M.-F., Cesta. "Normal structure, function, and histology of the spleen." Toxicologic pathology vol. 34(5), pp. 455-465, 2006.
[23] A., Pennello, J., Taylor, R., Matlack, J., Karp and J., Riggs, "Spiny mice (*Acomys cahirinus*) do not respond to thymus-independent type 2 antigens." Developmental & Comparative Immunology vol. 30(12), pp. 1181-1190, 2006.
[24] J., Simkin, T. R., Gawriluk, J. C., Gensel and A. W., Seifert,"Macrophages are necessary for epimorphic regeneration in African spiny mice." Elife vol. 6, e24623, 2017.
[25] J. O., Brant, J. H., Yoon, T., Polvadore, W. B., Barbazuk and M., Maden, "Cellular events during scar-free skin regeneration in the spiny mouse, *Acomys.*" Wound repair and regeneration vol. 24(1), pp. 75-88, 2016.
[26] T. R., Gawriluk, J., Simkin, C. K., Hacker, J. M., Kimani, S. G., Kiama, V. O., Ezenwa and A. W., Seifert, "Complex tissue regeneration in mammals is associated with reduced inflammatory cytokines and an influx of T cells." Frontiers in immunology vol.11, pp. 1695, 2020.
[27] E., Kivanc, H. M., Eyison and S., Kiralp. "The distribution, habitat and conservation status of the Turkish spiny mouse, *Acomys cilicicus* Spitzenberger, 1978." Journal of Entomology and Zoology Studies, vol. 5(2), pp. 1443-1447, 2017.
[28] B. K., Özdemirel, O., Çetintaş, M., Sözen, M., Çoğal and F., Matur, "Modelling Distribution of Asia Minor Spiny Mouse (*Acomys Cilicicus*) Using Maximum Entropy." International Journal of Environment and Geoinformatics vol.9(3), pp. 118-125, 2022.