ResearchGate

See discussions, stats, and author profiles for this publication at: https://www.researchgate.net/publication/372550702

Morphological Aspects on Heart and Main Blood Vessels of Black Sea Turbot (Psetta maxima) -Corrosion Cast and Morphological Studies

Article *in* Acta morphologica et anthropologica · July 2023

DOI: 10.7546/AMA.30.1-2.2023.06

CITATIONS
0

READS
56

6 authors, including:

Caner Bakıcı
Ankara University
34 PUBLICATIONS **50** CITATIONS

SEE PROFILE

Çiğdem Ürkü
Istanbul University
48 PUBLICATIONS **120** CITATIONS

SEE PROFILE

Alex Atanasoff
Trakia University
55 PUBLICATIONS **137** CITATIONS

SEE PROFILE

Elitsa Petrova Petrova-Pavlova
Agricultural Academy - Bulgaria Institute of Fish Resources - Varna
39 PUBLICATIONS **211** CITATIONS

SEE PROFILE

All content following this page was uploaded by Caner Bakıcı on 24 July 2023.

The user has requested enhancement of the downloaded file.

Institute of Experimental Morphology, Pathology and Anthropology with Museum
Bulgarian Anatomical Society

Acta Morphologica et Anthropologica, 30 (1-2)
Sofia ● 2023

Morphological Aspects on Heart and Main Blood Vessels of Black Sea Turbot (Psetta maxima) – Corrosion Cast and Morphological Studies

Nikolay Tsandev[1], Caner Bakici[2], Cigdem Urku[3], Alexander Afanasoff[1], Elitsa Petrova-Pavlova[4], Angel Vodenicharov[1]

[1] *Faculty of Veterinary medicine, Trakia University, Stara Zagora, Bulgaria*
[2] *Faculty of Veterinary medicine, Ankara University, Ankara, Turkiye*
[3] *Faculty of Aquatic Science, Istanbul University, Istanbul, Turkiye*
[4] *Insititute of Fish Resources, Varna, Bulgaria*

*Corresponding author e-mail: drcandev@abv.bg

Abstract

The turbot (*Psetta maxima*) is one the most valuable and economically important species for the Black Sea countries. The purpose of the current study was to investigate the cardiovascular system of this species with both corrosion cast and routine histology methods on 12 sacrificed turbots (6 males and 6 females) obtained from a hauls. After that fish were sacrificed and the blood vessels were filled through the heart with self-curing castable resin Duracryl® Plus U. Apart, materials from some parts of vasculary system for histology examination were taken and fixed in 10% neutral formalin solution. Based on the corrosion cast and histological techniques we described luminal structure and size of the aorta in turbot.

Key words: Black Sea Turbot, Cardiovascular system, Corrosion cast, Histology

Introduction

In the Black Sea, the major target demersal fish species with commercial importance are – turbot (*Psetta maxima*) and gobies (*Gobiidae*) with by-catch of thornback ray [9]. The turbot is intended mainly for human consumption and the scientific value of this species increased during the last decade [3]. Annual turbot stock assessments for scientific aims are made at the Bulgarian Black Sea coast [6,10]. Despite the increased

scientific interest there is still missing information about anatomy and morphology of turbot, except for one report about eye structure [4] and morphological of tongue [5].

The lack of data on the detailed morphological structure of the cardiovascular system of turbot gave us reason to undertake the present study in order to describe its cardiovascular system using a corrosion technique and hematoxylin-eosin histological method.

Material and methods

Sample collection

According to the Directive 2010/63/EU and respective the national program for data collection in the field of fisheries and aquaculture, especially assessment of the stock of turbot in the Bulgarian waters of the Black Sea twelve sexually mature turbot (6 males and 6 females) with body weight 2900-3200 g were captured by gillnets in the period from mid-March to late April. The main fishing areas covered the shelf area at depths from 15 to 90 m.

Corrosion cast

The blood vessels were washed with distilled water until leakage of the residual blood via the heart chamber. Two syringes were mounted on the heart chamber for the introduction of 100 ml of Duracryl® Plus U cold-curing resin (Spofa Dental, Czech Republic) solution (proportion powder : liquid, 1:3) using a special device described previously [8]. After that, the filled specimens were left at room temperature for 24 hours to complete the resin polymerization. Then the fish were placed into 5% Potassium hydroxide for 10 days at 45°C for removing the soft tissue. Finally, the corrosion specimens were washed with slow running water with some detergent to remove the remaining fat.

Histological examination

Tissue piesces from the ventral aortic wall were fixed by immersion in 10% buffered neutral formalin for 24 hours at room temperature and processed for paraffin embedding. Sections of 4-5 µm thick were stained with haematoxylin and eosin (H&E) and examined by light microscopy, using a describet method in specialized literature [1].

Result and Discussion

For the first time the replicas from turbot's heart chamber and initial vessels – aorta and its branches and histological structure of the aorta as well as, are described The corrosion castings of the gill arches showed an extremely accurate three-dimensional image (**Fig. 1**).

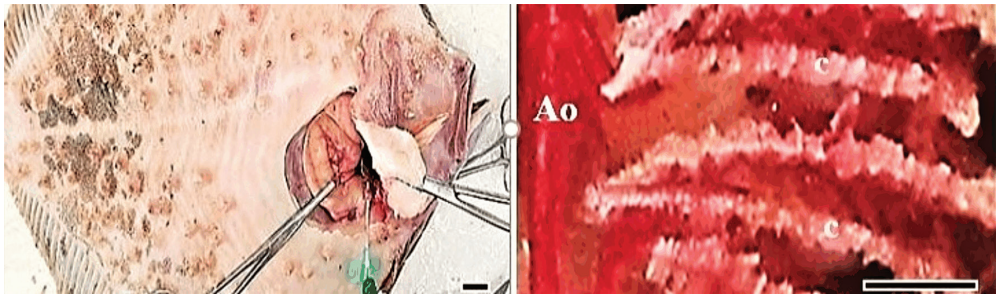

Fig. 1. Fulfillment of the circulatory system through the heart chamber (left). Corrosion cast from a gill arch on a turbot (right). **Ao –** Aorta, **c** – capillaries. Bar = 2 cm.

For notice is that, the weakly left-right asymmetry of the gills was found. The blood vessels, which came from the branchiostegal rays, were located in the distal part of the light elongated bones – ceratobranchial, as mentioned [11]. These findings gave reason to presume that the blood circulation in turbot is similar to other fish species and consists of a single circuit, as the deoxygenated blood from the heart is carried through the ventral aorta to the gills. Oxygenation process takes place in the lamellae and from them through dorsal aorta and secondary arteries distributed to the whole body of fish. The size of the middle segment of the aorta shows higher values of the lumen (caliber) in females (×= 0.90 mm) compared to males (×= 0.79 mm) (**Table 1)**. Relationship of the gender with size of aorta was also tracked with respect to depth but no significant correlation was detected.

Table 1. The lumen size of the middle segment of aorta in both gender of Black Sea turbot

	15-20 m	**50-60 m**	**80-90 m**
Male turbot, mm	0.72	0.84	0.79
Female turbot, mm	0.97	0.93	0.86

It was also found that the histological structure of turbot vessels was similar to vertebrates. The results of histological analyses exhibited that in the Black Sea turbot (*Psetta maxima*) three layers of the vessel wall were differentiated (**Fig. 2**). The results of the study were consistent with previous studies that described the same histological organization of blood vessel walls in fish [7], but they are in little contrast to data of [2] according to which the media of ventral aorta consists mainly of elastic fibers, as smooth muscle cells were also observed in its middle shell.

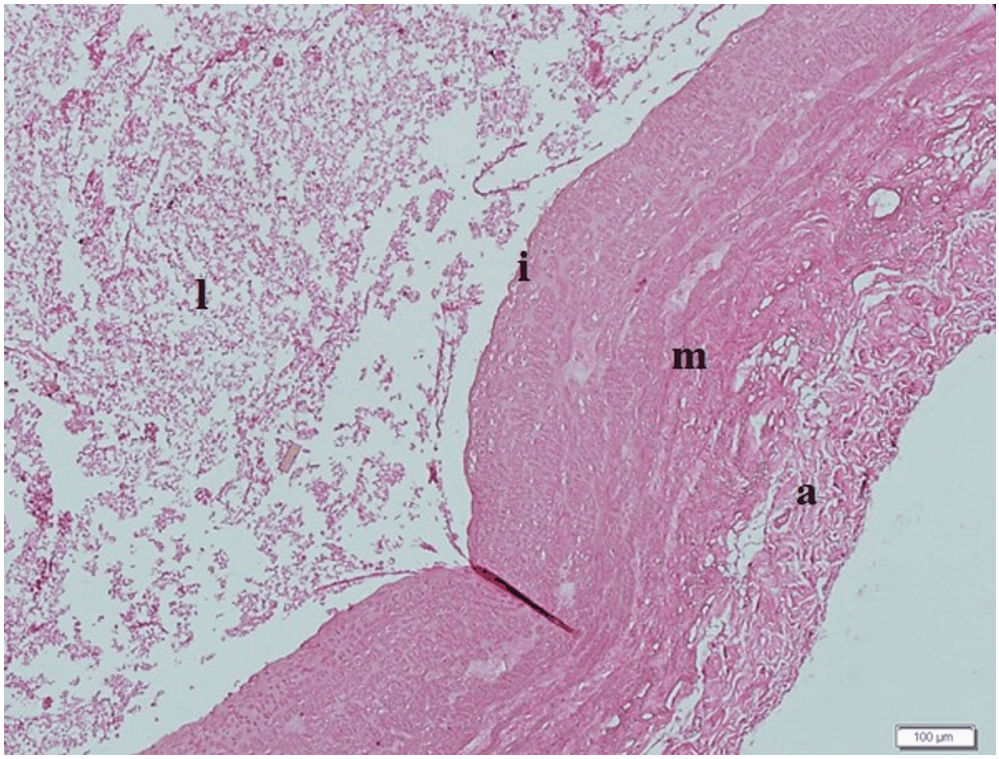

Fig. 2. Histological section of wall's segment of ventral aorta: **i** – intima, **m** – media, **a** – adventitia; **l** – lumen. Bar = 100 µm

Conclusion

As far as we know this is the first study which described the circulatory system of Black Sea turbot by the corrosion method. The data obtained add the knowledge about fish morphology for cardiovascular system in Black sea inhabitants and they could be useful for further morphological and pathological studies.

Acknowledgements: This work has been supported by Bulgarian Agriculture Academy, Research Board Grant (J-159/2020).

Reference

1. **Bullock, A.M.** *Laboratory methods in fish pathology* (Ed. R.J. Roberts) London, Bailliere Tindall, , 1978, 235-267.
2. **Genten, F., E. Terwinghe, A. Danguy**. Atlas of fish histology. Cardiovascular system and blood. Science Publisher, Enfield, NH, USA, 2009, 47.
3. **Ivanova, P., N. Dzhembekova, I. Atanassov, K. Rusanov, V. Raykov, I. Zlateva, M. Yankova, Y. Raev, G. Nikolov.** Genetic diversity and morphological characterisation of

three turbot (*Scophthalmus maximus* L., 1758) populations along the Bulgarian Black Sea coast. – *Nature Conservation* **43**, 2021, 123-146.
4. **Onuk, B., B. Yardımcı, S. Selviler-Sizer, M. Kabak**. Morphology of the tongue dorsal surface of turbot (*Scophthalmus maximus*). – *Microsc. Res. Tech*., **85**, 2022, 2795-2800.
5. **Onuk, B., O.Y. Pehlivan, B. Yardimci**. The fine structure of the turbot eye (*Scophtalmus maximus*): A macro-anatomical, light and scanning electron microscopical study. – *Microsc. Res. Tech*., **84**, 2021, 1163-1171.
6. **Petrova, E., F. Tserkova, V. Mihneva, S. Stoykov, S. Valchev, P. Penchev**. Fish bycatch rate by Rapana venosa fishery in the Bulgarian Black Sea waters, with a special emphasis on the bycatch of turbot *Scophthalmus maximus* (L., 1758). – *Acta Zool. Bulg., Supplement*, 2020, 165-172.
7. **Satchell, G. H.** *Physiology and form of fish circulation*. Cambridge University Press, 1991
8. **Tsandev, N., C. Bakıcı, A. Vodenicharov**. Evaluation of the compatibility between corrosion casts and 3D reconstruction of pig head arterial system on cone beam computed tomography. – *Ankara Üniversitesi Veteriner Fakültesi Dergisi*, **69**, 2022, 419-424.
9. **Tserkova, F., D. Petrova, E. Petrova-Pavlova, S. Stoykov, V. Mihneva, S. Valchev, D. Gerdzhikov, V. Maximov, G. Radu**. Abundance of turbot (*Psetta maxima* L.) along the Bulgarian Black Sea coast in autumn 2014. – *Proceedings of MEDCOAST*, 2015, 419-430.
10. **Tserkova, F., E. Petrova-Pavlova, S. Stoykov, V. Mihneva, S. Valchev, D. Klisarova, D. Gerdzhikov, V. Maximov, G. Radu.** Stock assessment of *Scophtalmus maximus* in Bulgarian Black Sea zone during autumn 2015. – *Proceedings of the Institute of Fish Resources*, **28**, 2015, 25-33.
11. **Yelnikov, D. V., A. V. Khanaychenko**. Morphological features of cephalic skeleton of the adult Black Sea turbot (Kalkan) *Scophthalmus maximus* var. maeotica (Pleuronectiformes, Scophthalmidae). – *Vestnik zoologii*, **47**, 2013, 42-51.

View publication stats