Nephrol Dial Transplant (2001) 16: 859–860

Nephrology
Dialysis
Transplantation

Nephroquiz for the Beginner
(Section Editor: M. G. Zeier)

Supported by an educational grant from AMGEN

Cystic infection of the liver in a maintenance haemodialysis patient

Case

A 54-year-old patient was admitted to our hospital suffering from recently appeared fever and loss of appetite. The patient had been on maintenance haemodialysis three times a week since 1986 and the aetiology of his chronic renal failure was chronic pyelonephritis. The patient has known to have hepatitis C antibody for 2 years. He had a history of geophagia for 1 year. On examination, blood pressure was 110/70 mmHg, pulse 110/min, and temperature 39.6°C. The liver was palpable 2 cm below the right subcostal margin. Other systems were normal. Laboratory tests were as follows: WBC 26 000/mm^3, platelet 256 000/mm^3, haematocrit 31.6%, erythrocyte sedimentation rate 105 mm/h, leukocytes differential count revealed polymorphonuclear leukocytes 75%, lymphocytes 5%, monocytes 4%, eosinophils 16%. Blood chemistry revealed elevation in liver enzymes, AST 52 IU/l, ALT 58 IU/l, ALP 288 IU/l, GGT 112 IU/l, LDH 211 IU/L, total bilirubin 0.5 mg/dl, and direct bilirubin 0.1 mg/dl. Serum immunoglobulin and complement levels were normal. Anti-nuclear antibody and rheumatoid factor were negative. C-reactive protein was 112 mg/l. Cryoglobulin and serum paraprotein were absent. Serological tests were as follows: hepatitis B surface antigen (−), anti-HBs (−), anti-HCV (+), HCV-RNA (−) and anti-HIV (−), CMV-IgM (−), IgG (+), EBV-IgM (−), IgG (+). Brucella and Salmonella agglutination tests were negative. Gastroscopy, chest plain film, and thorax tomography were normal. Repeated blood cultures were negative, bone-marrow biopsy was normal. Abdominal ultrasonography revealed multiple cystic lesions in the liver varying from 12 to 6 mm in size, and abdominal tomography showed multiple cystic lesions on the posterior right lobe of the liver (Figure 1). Empirical antibiotic treatment (imipenem/cilastatin) was started, but after 6 days there was no response.

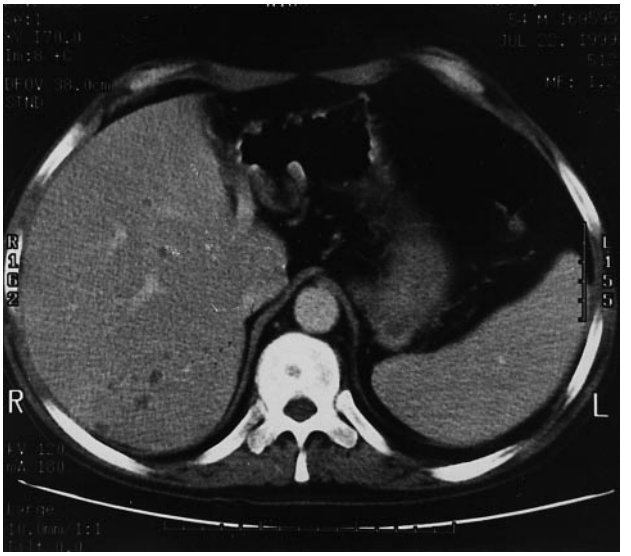

Fig. 1. Multiple cystic lesions in the liver.

Questions

What is the aetiology of the cystic infection of the liver? What procedure is needed for the diagnosis? What is the treatment of choice?

© 2001 European Renal Association–European Dialysis and Transplant Association

Answers to quiz on preceding page

This patient presented with fever, leukocytosis with eosinophilia, and multiple hepatic cystic lesions. The patient underwent ultrasonographic guided aspiration biopsy from the lesions. The cytological examination showed numerous barrel-shaped eggs including double-layered shells, which are typical of *Capillaria hepatica*. In culture, no micro-organisms or fungi were detected. The empirical treatment was discontinued and mebendazole 200 mg twice daily was started. Two days later, the fever disappeared and the patient remained afebrile. His appetite improved. One month later, laboratory findings were as follows: WBC 7300/mm^3, in differential count eosinophil ratio was 2%. C-reactive protein 12 mg/l, erythrocyte sedimentation rate 31 mm/h, haematocrit 36%, liver enzymes returned to normal levels, AST 16 IU/l, ALT 15 IU/l, GGT 61 IU/l, ALP 136 IU/l, LDH 125 IU/l. Abdominal ultrasonography and tomography showed no lesions in the liver. After 2 months treatment, mebendazole was discontinued. Nine months later, the patient had no symptoms and had gained 4 kg.

Capillaria hepatica is a very rarely reported parasitic infestation in human. Its primary host is usually the rat [1,2]. The adult form of C. *hepatica* lives in the host liver and produces a large number of eggs. When the host rodent carrying these parasites dies, the cycle starts. The eggs may be released into the soil or other carnivorous animals may eat the rodent and if so, they discharge undigested eggs into the environment *via* faeces. The eggs are embryonated in appropriate circumstances within a month. Only embryonated eggs have an infectious capability, unembryonated eggs are discharged in constant form. When the embryonated eggs are ingested via soil or contaminated foods, the larvae pass through the intestinal wall and reach the liver, and they may also may migrate to other organs including the lungs and kidneys. The larvae become mature in the liver and female worms release thousands of eggs, which remain in the liver until the death of the host. Then, both worms die and the life cycle is completed.

In reported cases, most human hosts were children under five years of age [3–6]. Therefore it is presumed that the transmission can be caused by dirt-eating habits or other soil–hand–mouth contact. In this case the patient had a history of geophagia, which is most probably the cause of this infestation. Clinical findings depend on severity and the extent of the infestation. The eggs induce an inflammatory reaction and extensive fibrosis in the liver that can lead to cirrhosis. Hepatomegaly, anaemia, hypereosinophilia, and fever are the general findings in reported cases. The diagnosis is based on fine-needle aspiration biopsy of the liver and demonstration of typical eggs of *C. hepatica*. Some cases have been diagnosed incidentally with extrahepatic findings, including pulmonary and gastrointestinal systems.

Among *C. hepatica* survival cases, thiabendazole, albendazole, antimony, dithiazanine iodide, diethycarbamazine, disophenol, and pyrantel tartrate were the agents used against the infestation [3,4]. Although there is not a great deal of experience and consensus about the treatment of *C. hepatica*, thiabendazole seems to be an efficient drug for the elimination of adult forms of *C. hepatica* from the liver. However, thiabendazole and albendazole seem to be ineffective in clearing eggs from the liver. This may be explained by the fibrous tissue around the eggs and the egg shells that could protect the eggs from the effects of drugs. In this case, after 2 months of treatment with mebendazole, significant clinical and laboratory improvement was observed. To the best of our knowledge, this is the first report of the effective treatment of *C. hepatica* with mebendazole.

Suggested reading

1. Bancroft L. On the whip-worm of the rat's liver. *J Proc R Soc New S Wales* 1893; 27: 86–90
2. Seo BS, Rim HJ, Lee CW, Yoon JS. Studies on the parasitic helminths of Korea. II. Parasites of the rat, *Rattus norvegicus Erxl.* in Seoul, with the description of *Capillaria hepatica* (Bancroft, 1893) (Travassos, 1915). *Korean J Parasitol* 1964; 2: 55–62
3. Choe G, Lee HS, Seo JK *et al.* Hepatic capillariasis: First case report in the republic of Korea. *Am J Trop Med Hyg* 1993; 48: 610–625
4. Berger T, Degrémont A, Gebbers JO, Tönz O. Hepatic capillariasis in a 1-year-old child. *Eur J Pediatr* 1990; 149: 333–336
5. Attah EB, Nagarajan S, Obineche EN, Gera SC. Hepatic capillariasis. *Am J Clin Pathol* 1982; 79: 127–130
6. McQuown AL. Capillaria hepatica: report of genuine and spurious cases. *Am J Trop Med* 1950; 30: 761–767

Kenan Keven
J. Sedef Bengisun
Fevzi Altuntaş
Harun Akar
Gökhan Nergizoğlu
Sim Kutlay
Neval Duman
Bülent Erbay
Department of Nephrology
İbn-i Sina Hospital
Ankara, Turkey