Neuroradiology
https://doi.org/10.1007/s00234-026-04080-y

RESEARCH

Anterior cerebral artery variants and their influence on endovascular outcomes: a propensity score matched analysis from the CRETA registry

Arturo Consoli[1,2] · Raffaele Tortora[3] · Frédéric Clarençon[4,5] · Adam A. Dmytriw[6,7] · Eimad Shotar[4] · Pascal Jabbour[8] · Marios Psychogios[9] · Peter Sporns[10] · Ajit S. Puri[11] · Ameer E Hassan[12] · Oktay Algin[13] · Markus A. Möhlenbruch[14] · Riccardo Russo[15] · Oded Goren[16] · Gregoire Boulouis[17] · Takeshi Morimoto[18] · Raoul Pop[19] · Joanna WK Ho[20] · Virginia Pujol Lereis[21] · Jared Cooper[22] · Giancarlo Salsano[23] · Alessandro Sgreccia[1] · Eytan Raz[24] · Julien Burel[25] · Khawaja Muhammad Baqir Hassan[26] · Zhe Ji[27] · Riitta Rautio[28] · Maria Ruggiero[29] · Valerio Da Ros[30] · Joseph Domenico Gabrieli[31] · Michael Levitt[32] · Antonio Armando Caragliano[33] · Christophe Cognard[34] · Gaultier Marnat[35] · Nicola Limbucci[36] · Mariangela Piano[37] · Alexis Guedon[38] · Andrea Romi[39] · Fortunato Di Caterino[40] · Vyval Mykola[41] · Ocílio Ribeiro Gonçalves[42] · Adrien Guenego[43] · Mohamad Abdalkader[44] · Thanh Nguyen[44] · Vitor M. Pereira[6] · Erwah Kalsoum[45] · Aldobrando Broccolini[46,47] · Alessandro Pedicelli[47,48] · Luca Scarcia[45] · Andrea M. Alexandre[48]

Received: 21 April 2026 / Accepted: 13 June 2026
© The Author(s) 2026, modified publication 2026

Abstract

Background Anatomical variants of the anterior cerebral artery (ACA) may increase technical complexity during endovascular treatment of distal ACA aneurysms (DACA). However, their impact on treatment outcomes remains unclear. This study evaluated whether ACA variants influence angiographic and clinical outcomes following endovascular treatment.

Methods A retrospective multicenter analysis was conducted using data from the CRETA Registry, including patients with ruptured and unruptured DACA treated endovascularly. Patients were grouped according to ACA anatomy (variant vs. conventional). Outcomes were compared after propensity score matching (PSM) to adjust for confounders including age, aneurysm rupture status, dome-to-neck ratio, branch origin, and treatment type. The primary outcome was aneurysm occlusion at last follow-up based on the Raymond–Roy classification. Secondary outcomes included ischemic and hemorrhagic complications, vasospasm, and clinical outcome measured by the modified Rankin Scale (mRS).

Results After PSM, 128 patients were included (64 per group). Among patients with available imaging follow-up (54 in the conventional group and 55 in the variant group), adequate occlusion rates were comparable between the variant and conventional ACA groups (81.5% vs. 85.5%; $p=0.600$). No significant differences were observed in ischemic or hemorrhagic complications, vasospasm, or long-term clinical outcomes. Sensitivity analyses confirmed the robustness of the findings.

Conclusions ACA anatomical variants do not adversely affect the safety or efficacy of endovascular treatment for DACA. With appropriate anatomical assessment and treatment selection, endovascular therapy remains effective even in the presence of complex ACA configurations.

Keywords Aneursym · Anterior cerebral artery · Distal anterior cerebral artery · DACA endovascular treatment

Introduction

The endovascular management of ruptured and unruptured intracranial aneurysms has evolved during the last decades, being considered as a first-line treatment also in complex cases [1, 2]. This has been due in part to the evolution of the techniques that allow the treatment of both the aneurysmal sac and the vessel wall [3]. However, the treatment of distal intracranial aneurysms can be challenging, because of the small caliber of the parent artery, the distal location and the presence of anatomical variations, which potentially may increase the procedural risk and technical demands [4,

Extended author information available on the last page of the article

Published online: 06 July 2026

5]. Currently, no studies in the literature have investigated whether the presence of anatomical variations may represent an additional factor influencing the outcome of the endovascular treatment. The aim of this study was to assess whether the presence of anatomical variants of the anterior cerebral artery (ACA) may impact the outcome of different endovascular techniques for the treatment of distal anterior cerebral artery aneurysms (DACA), by analyzing data from the CRETA registry (Clinical and Radiological Evaluation of Endovascular Treatment of Distal Anterior Cerebral Artery Aneurysms) a multicenter, retrospective database that collects data on the endovascular management of DACA [6].

Methods

Patients and treatment

This is a retrospective, multicenter, observational study that included patients with ruptured and unruptured DACA aneurysms who underwent different endovascular treatments, analyzed as part of the CRETA Consortium study [6] (Fig. 1). DACA aneurysms were defined as those located on the A2–A5 segments of the anterior cerebral artery, excluding aneurysms of the A1 segment and the anterior communicating artery (AComA). Data were collected on patient demographics, aneurysm characteristics, procedural details, complications, and clinical and radiographic outcomes. Irregular morphology was defined as the presence of a bleb, lobulation, or microlobe on 3D rotational angiography. Endovascular treatments comprised simple coiling, balloon-assisted coiling, stent-assisted coiling, flow diverter stents (standalone or with coiling), and intrasaccular devices.

We identified two study subgroups according to the presence ("ACA variant anatomy" subgroup) or absence of an anatomical variant of the ACA (ACA conventional anatomy). Anatomical variants of the ACA, specifically the azygos ACA and bihemispheric ACA subtypes, are uncommon but clinically significant configurations that require careful evaluation when planning endovascular treatment. According to Lasjaunias [7] the Azygos-type ACA is characterized by a single, unpaired artery arising from both the A1 segments throughout the ACA course and supplying both medial hemispheric surfaces. Despite the notion of

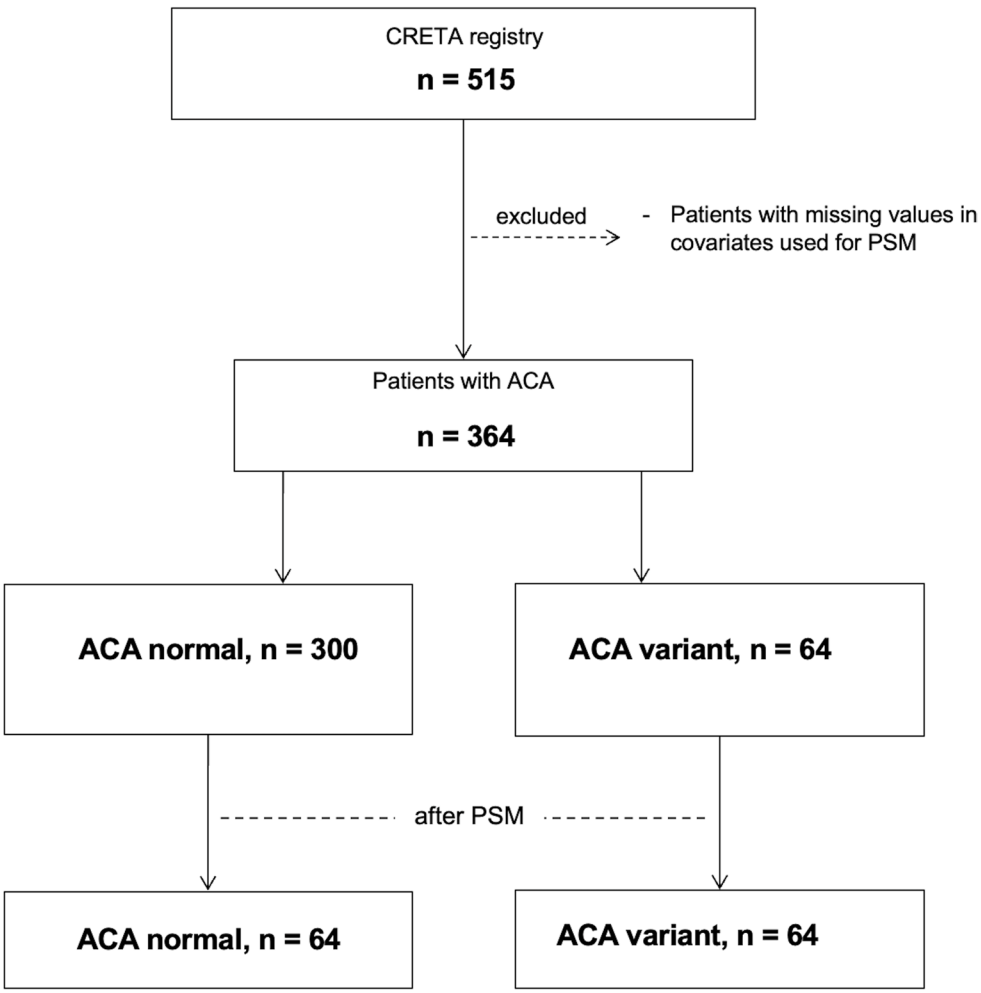

Fig. 1 Flow chart illustrating patient selection from the CRETA registry, following identification of covariates for PSM, leading to the final study population

an ACA variant according to these definition was available in the CRETA Registry, the subtype of the variant was not specified.

The study adhered to the Strengthening the Reporting of Observational Studies in Epidemiology (STROBE) guidelines and was conducted under a nonprofit research protocol approved by the ethics committee of the coordinating center (Fondazione Policlinico Universitario A.Gemelli IRCCS, protocol ID 3583).

Measures of outcome

The primary outcome measure was aneurysm occlusion at last imaging follow-up assessed using digital subtraction angiography (DSA), magnetic resonance angiography (MRA), or computed tomography angiography (CTA), and graded according to the Raymond-Roy Occlusion Classification (RROC) scale [8]. RR classes I and II were merged into a single variable indicating complete/near-complete occlusion, while IIIa and IIIb were defined as incomplete occlusion. Secondary outcome measures included the occurrence of ischemic or hemorrhagic complications and of vasospasm and the long-term clinical outcome measured with the modified Rankin Scale (mRS). Specifically, ischemic complication: Any new hypodensity on post-procedural imaging or clinical deficit attributed to thromboembolism within 30 days; hemorrhagic complication: any new parenchymal, subarachnoid, or intraventricular hemorrhage on post-procedural imaging within 30 days; vasospasm: angiographic or clinically suspected vasospasm requiring medical or endovascular treatment; periprocedural complications are defined as occurring within 30 days post-procedure or during the same hospitalization.

Statistical analysis

Descriptive statistics were used to summarize baseline characteristics. Continuous variables were expressed as means ± standard deviations (SD) or medians with interquartile ranges (IQR), while categorical variables were presented as counts and percentages. Fisher's exact test was used to compare categorical variables, and either the Welch two-sample t-test or the Mann-Whitney U test was applied to continuous variables, depending on their distribution. The Shapiro-Wilk test was used to assess the normality of continuous variables. Missing data were not imputed, and significance was set at $p < 0.05$.

We used propensity score matching (PSM) with the optimal algorithm to estimate the difference in outcome measures between patients with the conventional ACA anatomy and those carrying the variant one. Covariates used in the PSM model were those with a potential effect on measured outcomes (based on clinical plausibility and prior literature) and included age, unruptured aneurysm status, the dome-to-neck ratio, the branch artery origin (classified as from the sac, the neck or the artery, respectively) and type of treatment. Covariates balance was assessed by examining standardized mean differences (SMD), with values < 0.2 indicating acceptable balance. Odds ratio with 95% CI were calculated for each variable, with the variant ACA anatomy group serving as the reference (Supplementary Table 1 A). The Standardized Mean Differences (SMD) for all covariates before and after matching is reported in supplementary Table 1B. For missing clinical outcome data, a sensitivity analysis was conducted to evaluate the robustness of the results under three different scenarios: (1) the worst-case scenario (defined as the pro-variant ACA anatomy scenario: all missing cases with conventional ACA anatomy had the unfavorable angiographic outcome, all missing cases with the variant ACA anatomy had the favorable outcome), (2) the best-case scenario (defined as the pro-ACA normal anatomy: all missing cases with the conventional ACA anatomy had the favorable angiographic outcome, all missing cases carrying the variant ACA anatomy had the unfavorable outcome), and (3) the observed scenario (only cases with complete data). Odds ratios with 95% CI were calculated for each scenario (Supplementary Fig. 1). As a sensitivity analysis to address potential loss of statistical power after matching, we performed multivariable logistic regression in the full unmatched cohort ($N = 364$), adjusting for all covariates used in the propensity score model (age, rupture status, dome-to-neck ratio, branch origin, and treatment type). The results confirmed the absence of a significant association between ACA variant status and adequate occlusion (Supplementary Table 4). Significance threshold was set at $p < 0.05$. All analyses were performed using the R software v.4.3.2 with the *MatchIt* and *tidyverse* packages (https://www.r-project.org). No subgroup analysis was performed on the subtype of anatomical variation.

Results

We have analysed an initial cohort of 300 patients with conventional ACA anatomy and 64 patients harboring an ACA variant. After PSM, the final population included 128 patients, equally distributed between the two subgroups ACA normal anatomy and ACA variant anatomy. Detailed data according to each subgroup were summarized in Tables 1 and 2. We report here only the overall results. The majority were female (85/128, 66.4%) with a median age of 62 years (IQR 54–70). Hypertension was the most common risk factor, present in 79/126 (62.7%), followed by dyslipidemia in 30/126 (23.8%) and diabetes in 17/126 (13.5%).

Only 15/125 (12.0%) were current smokers. A family history of aneurysms was reported in 20/122 (16.4%). Previous SAH occurred in 13/127 (10.2%), due to the index aneurysm in 10/126 (7.9%) and to another aneurysm in 3/126 (2.4%). Ruptured aneurysms were observed in 62/128 (48.4%), with irregular morphology in 81/128 (63.3%). Branch artery origin involved the sac in 25/128 (19.5%), the neck in 61/128 (47.7%), and the artery in 42/128 (32.8%).

Transradial access was performed in 9/128 (7%) and in 79/125 (63%) cases a tri-axial system was used. The most frequently used techniques were standalone coiling in 57/128 cases (44.5%) and flow-diverter in 34/128 (26.6%) (Fig. 2). According to the CRETA registry the median radiological follow-up was 16.5 months (IQR 7–24) (6). Median imaging follow-up was similar between groups (conventional: 16 months, IQR 7–24; variant: 17 months, IQR 8–25; $p=0.500$), as shown in Table 2.

The clinical and procedural outcomes were summarized in Table 3. We did not observe any statistical difference concerning the adequate occlusion rate based on available imaging follow-up in 54 patients per group (81.5% vs. 85.5%, OR 1.3; 95% CI 0.5–3.7; $p=0.600$) and the intra-procedural complications (ischemic: 7.8% vs. 14.1%, $p=0.700$; hemorrhagic: 3.2% vs. 7.8%, $p=0.500$). Clinical outcomes did not significantly differ between two subgroups. The sensitivity analysis showed no significant modification of the primary and second endpoints (Supplementary Fig. 1). Missing imaging follow-up data were present in 15.6% of patients (20/128): 10 in the conventional group and 10 in the variant group. The sensitivity analysis for the primary outcome

Table 1 Univariate analysis of demographic, baseline clinical and imaging data, before and after propensity score matching

	before propensity score matching			after propensity score matching		
	ACA normal anatomy $N=300$	ACA variant anatomy $N=64$	p *	ACA normal anatomy $N=64$	ACA variant anatomy $N=64$	p *
Demographics						
sex (female), n/N (%)	218/300 (72.7)	39/64 (60.9)	0.100	46/64 (71.9)	39/64 (60.9)	0.200
age (years), median (IQR)	61 (53–68)	61 (53–69)	0.600	63 (54–70)	61 (53–69)	0.400
Baseline clinical features						
hypertension	180/299 (60.2)	41/63 (65.1)	0.500	38/63 (60.3)	41/63 (65.1)	0.600
dyslipidemia, n/N (%)	76/298 (25.5)	15/63 (23.8)	0.800	15/63 (23.8)	15/63 (23.8)	1.0
diabetes, n/N (%)	36/298 (12.1)	11/63 (17.5)	0.200	6/63 (9.5)	11/63 (17.5)	0.200
coronary artery disease, n/N (%)	30/296 (10.1)	5/63 (7.9)	0.600	5/62 (8.1)	5/63 (7.9)	0.900
Previous stroke, n/N (%)	27/299 (9.0)	5/63 (7.9)	0.800	4/63 (6.3)	5/63 (7.9)	0.700
baseline mRS score, median (IQR)	0 (0–0)	0 (0–0)	0.600	0 (0–0)	0 (0–0)	0.800
smoking habit			0.400			0.400
non-smoker	204/286 (71.3)	49/63 (77.7)		47/62 (75.8)	49/63 (77.7)	
prior smoker	44/286 (15.4)	5/63 (7.9)		9/62 (14.5)	5/63 (7.9)	
active smoker	38/286 (13.3)	9/63 (14.3)		6/62 (9.7)	9/63 (14.3)	
family history of aneurysm, n/N (%)			0.400			0.900
none	252/288 (87.5)	50/60 (83.3)		52/62 (83.9)	50/60 (83.3)	
yes	36/288 (12.5)	10/60 (16.7)		10/62 (16.1)	10/60 (16.7)	
previous SAH, n/N (%)			0.600			0.600
no	273/298 (91.6)	59/64 (92.2)		55/63 (87.3)	59/64 (92.2)	
yes, due to index aneurysm	14/298 (4.7)	4/64 (6.2)		6/63 (9.5)	4/64 (6.2)	
yes, due to another aneurysm	11/298 (3.7)	1/64 (1.6)		2/63 (3.2)	1/64 (1.6)	
Radiographic Features						
unruptured aneurysm	178/300 (59.3)	35/64 (54.7)	0.500	31/64 (48.4)	35/64 (54.7)	0.500
dome-to-neck ratio, median (IQR)	1.4 (1.1–1.9)	1.6 (1.2-2)	0.060	1.5 (1.1-2)	1.6 (1.2-2)	0.400
morphology			**0.005**			0.100
regular	147/300 (49.0)	19/64 (29.7)		28/64 (43.8)	19/64 (29.7)	
irregular	153/300 (51.0)	45/64 (70.3)		36/64 (56.2)	45/64 (70.3)	
branch artery origin			0.200			0.800
sac	33/300 (11.0)	12/64 (18.7)		13/64 (20.3)	12/64 (18.7)	
neck	151/300 (50.3)	30/64 (46.9)		31/64 (48.4)	30/64 (46.9)	
artery	116/300 (38.7)	22/64 (34.4)		20/64 (31.3)	22/64 (34.4)	
parent artery diameter in mm, median (IQR)	1.8 (1.6–2.1)	2 (1.6–2.4)	**0.030**	1.9 (1.6–2.2)	2 (1.6–2.4)	0.100

ACA, anterior cerebral artery; IQR, interquartile range; mRS, modified Rankin Scale; SAH, subarachnoid haemorrhage; * significance threshold set at $p<0.05$

Table 2 Univariate analysis of treatment and post-treatment data, before and after propensity score matching

	before propensity score matching			after propensity score matching		
	ACA normal anatomy *N* = 300	ACA variant anatomy *N* = 64	*p* *	ACA normal anatomy *N* = 64	ACA variant anatomy *N* = 64	*p* *
site of access, n/N (%)			0.500			0.300
femoral	279/300 (93.0)	58/64 (90.6)		61/64 (95.3)	58/64 (90.6)	
radial	21/300 (7.0)	6/64 (9.4)		3/64 (4.7)	6/64 (9.4)	
system, n/N (%)			0.500			0.100
coaxial	111/286 (38.1)	28/64 (43.7)		18/61 (29.5)	28/64 (43.7)	
triaxial	175/286 61.2)	36/64 (56.3)		43/61 (70.5)	36/64 (56.3)	
Treatment type, n/N (%)			0.800			0.900
unassisted coiling	124/300 (41.3)	27/64 (42.2)		30/64 (46.9)	27/64 (42.2)	
balloon-assisted coiling	23/300 (7.7)	7/64 (10.9)		7/64 (10.9)	7/64 (10.9)	
stent-assisted coiling	39/300 (13.0)	5/64 (7.8)		4/64 (6.3)	5/64 (7.8)	
flow-diverter	89/300 (29.6)	18/64 (28.1)		16/64 (25.0)	18/64 (28.1)	
flow-diverter plus coiling	8/300 (26.7)	2/64 (3.1)		2/64 (3.1)	2/64 (3.1)	
intrasaccular device	15/300 (5.0)	5/64 (7.8)		5/64 (7.8)	5/64 (7.8)	
parent artery occlusion	2/300 (0.6)	0/64		0/64	0/64	
Follow-up duration (months, IQR)	15 (6–23)	16 (7–24)	0.600	16 (7–24)	17 (8–25)	0.500

ACA, anterior cerebral artery; * significance threshold set at $p < 0.05$

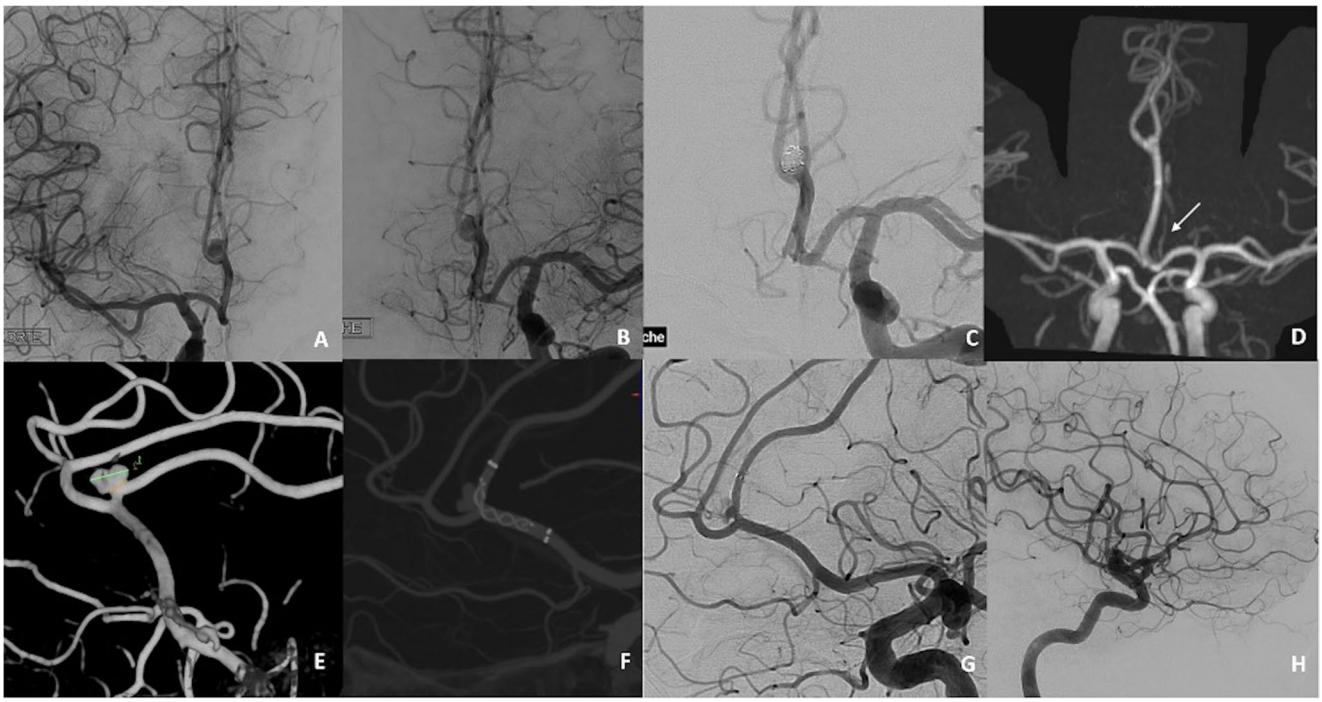

Fig. 2 Illustrative case 1 (**A**-**D**): The digital subtraction angiography with injection of both internal carotid arteries (**A**, **B**) shows a 6.2 × 3.7 mm, irregular, unruptured aneurysm located at the bifurcation of a bi-hemispheric anterior cerebral artery (ACA). The aneurysm was treated through unassisted coiling with complete occlusion of the sac (**C**). The 4-years MRI 3D-TOF follow-up shows the persistent and complete occlusion of the aneurysm. In the same picture it is possible to observe the left hypoplasic A2 segment (**D**, white arrow). Illustrative case 2 (**E**-**H**): 3D-Rotational angiography showing a 6 × 4 mm, irregular, unruptured, aneurysm at the origin of the left pericallosal artery (**E**) without any anatomical variant of the ACA. The aneurysm was treated using a Fred jr. 2.5 × 18 mm FD stent (**F**). The final angiogram at the end of the procedure shows the correct deployment of the stent and the reduction of the filling of the aneurysmal sac (**G**). The 1-year DSA follow-up shows the complete occlusion of the aneurysm, the patency of the stent and of the covered callosomarginal artery (**H**)

Table 3 Univariate analysis of outcome measures in the matched cohort

Outcome measure	ACA normal anatomy $N=64$	ACA variant anatomy $N=64$	OR (95% CI) #	p*
Raymond-Roy class I and class II at latest follow-up , n/N (%)	47/55 (85.5)	44/54 (81.5)	1.3 (0.5–3.7)	0.600
ischemic complications, n/N (%)				0.700
none	55/64 (85.9)	59/64 (92.2)		
thromboembolic asymptomatic	8/64 (12.5)	5/64 (7.8)		
thromboembolic symptomatic transient	1/64 (1.6)	0/64 (0.0)		
hemorrhagic complications, n/N (%)				0.500
none	59/64 (92.2)	62/64 (96.8)		
IPH	3/64 (4.7)	1/64 (1.6)		
SAH	2/64 (3.1)	1/64 (1.6)		
vasospasm, n/N (%)	5/64 (7.8)	7/64 (10.9)	1.4 (0.4–4.8)	0.500
long-term mRS score, median (IQR)	0 (0–1)	0 (0–1)		0.900

ACA, anterior cerebral artery; OR, odds ratio; CI, confidence interval; IPH, intraparenchymal hemorrhage; SAH, subarachnoid hemorrhage; mRS, modified Rankin Scale; IQR, interquartile range; #, OR was calculated with ACA variant anatomy serving as the reference; *, significance threshold set at $p<0.05$

showed consistent results across all three scenarios, with no scenario demonstrating a statistically significant association between ACA variant status and inadequate occlusion: pro-ACA variant anatomy: OR 0.7; 95% CI 0.2–2.2; $p=0.700$, pro-ACA normal anatomy: OR:3.3; 95% CI 0.9–11.1; $p=0.060$ (Supplementary Table 2). We performed an additional multivariable logistic regression analysis within the matched cohort adjusting for irregular morphology, which confirmed the absence of a significant association between ACA variant status and adequate occlusion (OR 1.2, 95% CI 0.5–3.1, $p=0.600$; Supplementary Table 5).

Angiographic outcomes of the covered vessel by Flow-Diverter (FD) stents at the last follow-up in the two study subgroups, before PSM, were reported in Supplementary Table 3. No ischemic complications related to the vessel covered by the FD stent were observed in both subgroups. Post-hoc power calculation confirmed adequate power for the primary outcome (80% to detect a 20% difference) but limited power for rare events. Multivariable analysis in the full unmatched cohort ($N=364$) confirmed the null finding for ACA variant status (OR 1.2, 95% CI 0.7–2.1, $p=0.500$; Supplementary Table 4).

To assess procedural complexity, we compared surrogate measures between groups. No significant differences were observed in procedure duration, fluoroscopy time, or device deployments, suggesting that ACA variants did not increase technical difficulty (Supplementary Table 6).

Discussion

Our statistical analysis showed no significant difference in terms of adequate occlusion (RR I-II) at the latest follow-up of the treated aneurysms in patients with and without an ACA variant. Furthermore, the complication rates were comparable in the two subgroups. These results indicate that the presence of an anatomical variant does not adversely affect the outcome of the endovascular treatment. Specifically, while local anatomy such as neck size and geometry remains a primary determinant of endovascular outcome, acknowledging the presence of ACA variants provides additional contextual information that may inform procedural planning without implying causation of poor results.

Effectiveness of EVT according to anatomical variations

The effectiveness of the endovascular treatment for distal anterior cerebral aneurysms has already been shown in previous studies. In particular, the meta-analysis by Vilardo et al. [9] concluded that the use of Flow-Diverter stents seems to be safe and effective in the treatment of distal aneurysms and that this is associated with high occlusion rates.

Although previous studies have reported similar rates of effectiveness of EVT in distal ACA aneurysms (DACA), none specifically accounted for the presence of anatomical variants. Cagnazzo et al. [10] reported an overall rate of adequate occlusion (OKM C–D) of 79% (19/24 aneurysm) in a series of 25 unruptured DACA treated with flow diverters. These results are in line with those reported in the same subgroup in a previous meta-analysis, focusing on the treatment of distal aneurysms of the anterior circulation [11].

In our cohort, the occlusion rates were similar or higher. However, in this study we have included different endovascular techniques, and our findings are not limited to the FD stents.

Porto et al. [12] reported high occlusion rates (>90%) at the end of the follow-up in a cohort of 84 patients with DACA treated in 5 institutions through primary coiling (60/84) or FD stents (24/84). Interestingly, in their series about 60% of the patients (61.9%, 52/84) had ruptured aneurysms and among them 11 were treated by FD stents. The effectiveness of flow diverters in the management of ruptured DACA aneurysms has also been supported by

Salsano et al. [13], who reported an adequate occlusion rate of 95.2% in an analysis of 21 ruptured DACA treated by FD stents.

Nevertheless, limited data are available concerning the impact of the ACA variants on the endovascular outcomes.

In our study, we reported comparable occlusion rates at the last follow-up in both the variant (81.5%) and non-variant (85.5%) sub-groups and these are in line with the aforementioned ones. These results underline the effectiveness of the different endovascular approaches even in case of potentially challenging anatomical conditions.

In our study no significant difference was observed in terms of arterial branches arising from the sac or the neck. Indeed, it had been previously shown that this factor may negatively affect the occlusion rates [14, 15] particularly when they originate from the aneurysm dome [16]. This mechanism has been supported by experimental evidence where neointimal growth effectively seals the aneurysm neck but spares the origin of the branch, since the efferent flow through the incorporated branch prevents the intra-aneurysmal stasis required for complete sac thrombosis [17]. This may be particularly relevant in the context of the treatment of DACA with FD stents in the setting of ACA variants, where the origin, vessel caliber, and distribution of leptomeningeal anastomoses may differ from the normal anatomical configuration.

In our study, within the group of patients with ACA variants, a branch originated from the aneurysm neck in 30 out of 64 cases (46.9%) and from the aneurysm sac in 12 out of 64 cases (18.7%). Despite the presence of a branch arising from the aneurysm in more than half of the cases, the endovascular outcome was not adversely affected. This finding had already been reported by Cagnazzo et al., probably related to the presence of collateral circulation in the frontal and orbitofrontal regions [10], and further confirmed in the analysis of the CRETA registry [6]. Finally, the size and the dome-to-neck ratio did not influence the occlusion rates in both variant and non-variant subgroups, although the mean size of the aneurysm was < 6 mm in this analysis.

Safety profile according to anatomical variations

In our series, the presence of an ACA anatomical variant was not associated with a higher rate of procedural complications. On the contrary, both ischemic and hemorrhagic complications occurred less frequently in the variant group compared to the non-variant group, although these differences did not reach statistical significance. These results are consistent with prior studies reporting overall treatment-related complication rates of approximately 5–7.5% for DACA aneurysms treated with flow diverters [6, 11, 18] and up to 13% for DACA treated with different endovascular devices [12].

Anatomical variants such as azygos or bihemispheric ACA may theoretically represent a higher thromboembolic risk due to the presence of a single dominant or unpaired arterial segment. However, in our cohort, ischemic complications occurred in only 5 patients within the ACA variant group, and all were asymptomatic. Although ACA variants may lead to a different disposition of the origin and caliber of the cortical branches arising from A2–A3 segments [19], no acute thromboembolic occlusion of these vessels was observed. This suggests that the presence of an anatomical variant does not increase the ischemic risk compared to the normal anatomy, particularly in case of usage of flow-diverter stents. As far as the rate of hemorrhagic complications is concerned, in the ACA variant subgroup this was lower than in the subgroup with conventional anatomy.

These results could be explained using different endovascular techniques, in particular unassisted coiling and intrasaccular devices, with the choice of respecting the vascular anatomy of the parent vessel when possible.

In our study, no ischemic complications related to covered side vessels from the FD stent were observed in either the normal ACA anatomy group or the ACA variant anatomy group. This finding is consistent with previous studies reporting a very low rate of symptomatic ischemic events associated with vessel occlusion [10, 20]. In the systematic review by Gunkan et al., 30/372 covered vessels were occluded, but only 3 cases were symptomatic [21]. Cagnazzo et al. attributed this phenomenon to the presence of collateral circulation in the frontal and orbitofrontal regions, which may account for asymptomatic occlusion or flow remodelling of the covered branches [10]. As we have shown with our results, this mechanism may also apply in the setting of ACA anatomical variants.

Overall, these findings support the assumption that ACA anatomical variants do not adversely impact the safety of the endovascular treatment for distal aneurysms and that the procedural risks remain comparable to those described in the literature for conventional ACA anatomy.

Anatomical considerations and procedural technical aspects

The hypothesis of this study focused on the potential role of anatomical variation of ACA in determining different outcomes of the endovascular treatment of DACA. The Azygos type is different from the Unpaired type of Anterior cerebral artery, where both A1 segments join at the midline and immediately divide into two main trunks at the level of the genu of the corpus callosum [22]. In the bihemispheric-type

ACA, a dominant A2 segment crosses the midline, perfusing both hemispheres, often in association with hypoplasia or aplasia of the contralateral A2 [7, 19, 22]. Despite these major anatomical differences, our study showed no statistically significant difference in the mean diameter of the parent vessel from which the aneurysm originated between the ACA variant group and the group with normal anatomy (2 mm [IQR 1.6–2.4]; 1.9 mm [IQR 1.6–2.2]; $p=0.100$). This finding is consistent with previously published data reporting an average vessel diameter of approximately 2 mm [10, 11, 18, 23], suggesting that standard stent sizing remains appropriate even in the presence of ACA anatomical variants.

Compared to the conventional ACA anatomical pattern, these variants present notable morphological differences, which have been correlated with an increased susceptibility to the development of aneurysmal formations [24], particularly at sites of altered hemodynamic stress and vessel wall weakness. This is further supported by our findings, which showed a statistically significant difference in aneurysm morphology after PSM: irregularly shaped aneurysms were more frequently observed in the ACA variant group compared to the normal anatomy group (45/64, 70.3% vs. 36/64, 56.2%; $p=0.100$). However, despite the association between ACA anatomical variants and an increased risk of irregular aneurysm morphology, we demonstrated that endovascular treatment remains both effective and safe in these cases.

Conversely, in the ACA variants, the dominant vessel may give rise to a greater number of cortical and perforating branches to supply both hemispheres compared to a standard A2 [7, 19], which may theoretically increase the complexity of stent placement, particularly in the context of flow diverter placement, compromising the perfusion of cortical arterial branches [25].

Moreover, although in ACA variants a single vessel supplies both hemispheres, this could raise concerns that procedural complications such as thromboembolism or in-stent thrombosis could result in more extensive neurological deficits. However, in our study such events were not observed.

Limitations

This study presented some limitations. First, its retrospective and multicenter design introduces potential heterogeneity due to differences in endovascular techniques and operator preferences across centers, which may have influenced the outcomes. In addition, there was no centralized imaging analysis for the definition of ACA variants, which may have introduced heterogeneity in variant classification across centers and in the CRETA registry the specific subtype of the variant was not specified, limiting the specificity of this analysis. Additionally, although anatomical variations of the anterior cerebral artery are relatively rare, the sample size of patients with these variants remains limited. Fourth, the high proportion of irregular aneurysms in our cohort, especially in the ACA variant group (70.3% vs. 56.2%), likely reflects a combination of true biological susceptibility due to altered hemodynamics in ACA variants and referral bias, as complex cases could be preferentially enrolled in the CRETA registry. Fifth, matching reduced statistical power for rare events (e.g., hemorrhagic complications ~ 3–5%). Although power was adequate for the primary outcome, larger studies are needed to exclude small differences in uncommon safety events. Sixth, ACA variant subtype (azygos vs. bihemispheric) was not specified in the registry and grouping them together may have masked subtype-specific differences. Seventh, despite matching, irregular morphology remained more frequent in the variant group (70.3% vs. 56.2%). Sensitivity analysis adjusting for morphology confirmed no material change in the results, though residual confounding cannot be fully excluded. Larger, prospective studies are therefore needed to confirm our findings and better define the impact of ACA anatomical variants on treatment outcomes.

Conclusion

Our results demonstrate that the presence of ACA variants did not adversely affect the efficacy and safety of the endovascular treatment of DACA. The comparable rates of adequate occlusion and procedural complications observed in patients with and without ACA variants suggest that, when meticulous anatomical assessment and appropriate device selection are performed, these variants do not constitute a further risk factor for unfavorable outcomes.

Supplementary Information The online version contains supplementary material available at https://doi.org/10.1007/s00234-026-04080-y.

Author contributions -Conceptualization: Arturo Consoli, Andrea Alexandre, Luca Scarcia. -Methodology: Arturo Consoli, Andrea Alexandre, Aldobrando Broccolini, Luca Scarcia, Raffele Tortora. -Data curation: All authors. -Writing- Original draft preparation: Arturo Consoli, Andrea Alexandre, Aldobrando Broccolini, Luca Scarcia, Raffele Tortora. -Investigation: All authors. -Supervision: Andrea Alexandre, Luca Scarcia, Alessandro Pedicelli. -Writing- Reviewing and Editing: All authors.

Funding Open access funding provided by Università Cattolica del Sacro Cuore within the CRUI-CARE Agreement. No funding was received for this research.

Data availability No datasets were generated or analysed during the current study.

Declarations

Ethics approval All procedures performed in the studies involving human participants were in accordance with the ethical standards of the institutional and/or national research committee and with the 1964 Helsinki Declaration and its later amendments or comparable ethical standards.

Informed consent Informed consent was waived in consideration of the retrospective nature of this study.

Competing interests LS: unrelated to the current study, Penumbra (paid lectures). FS: Outside the submitted work received lecturer's fee from Idorsia Pharmaceuticals for the past 36 months. OG: Outside the submitted work, MicroVention proctor for the WEB device, Stryker consultant, Route 92 consultant. ML: Unrestricted educational grants from Medtronic and Stryker; consulting agreement with Aeaean Advisers, Metis Innovative, Genomadix, AIDoc and Arsenal Medical; equity interest in Proprio, Stroke Diagnostics, Apertur, Stereotaxis, Fluid Biomed, Synchron and Hyperion Surgical; editorial board of Journal of NeuroInterventional Surgery; Data safety monitoring board of Arsenal Medical. AMA: educational grants from Medtronic, Stryker, Balt and Microvention/Terumo unrelated to the current study. AP: educational grants from Medtronic, Stryker, Balt and Microvention/Terumo unrelated to the current study. AEH: Consultant/Speaker: Medtronic, Microvention, Stryker, Penumbra, Cerenovus, Genentech, GE Healthcare, Scientia, Balt, Viz.ai, Insera therapeutics, Proximie, NeuroVasc, NovaSignal, Vesalio, Rapid Medical, Imperative Care, Galaxy Therapeutics, Route 92, Perfuze, CorTech, Shockwave, Toro and Xcath. Principal Investigator: COMPLETE study – Penumbra, LVO SYNCHRONISE – Viz.ai, MARRS - Perfuze, RESCUE - ICAD - Medtronic. Steering Committee/Publication committee member: SELECT, DAWN, SELECT 2, EXPEDITE II, EMBOLISE, CLEAR, ENVI, DELPHI, DISTALS. DSMB - COMAND trial. ML Unrestricted educational grants from Medtronic and Stryker; consulting agreement with Aeaean Advisers, Metis Innovative, Genomadix, AIDoc and Arsenal Medical; equity interest in Proprio, Stroke Diagnostics, Apertur, Stereotaxis, Fluid Biomed, Synchron and Hyperion Surgical; editorial board of Journal of NeuroInterventional Surgery; Data safety monitoring board of Arsenal Medical. FC reports conflicts of interest with Medtronic, Balt Extrusion (consultant), ClinSearch (core lab), Penumbra, Stryker (payment for reading) and Artedrone (Board) ; all not directly related to the present work. CC consultant for Medtronic, Microvention, Cerenovus, Stryker, Anaconda, unrelated to the current study.

Open Access This article is licensed under a Creative Commons Attribution 4.0 International License, which permits use, sharing, adaptation, distribution and reproduction in any medium or format, as long as you give appropriate credit to the original author(s) and the source, provide a link to the Creative Commons licence, and indicate if changes were made. The images or other third party material in this article are included in the article's Creative Commons licence, unless indicated otherwise in a credit line to the material. If material is not included in the article's Creative Commons licence and your intended use is not permitted by statutory regulation or exceeds the permitted use, you will need to obtain permission directly from the copyright holder. To view a copy of this licence, visit http://creativecommons.org/licenses/by/4.0/.

References

1. Hoh BL, Ko NU, Amin-Hanjani S, Hsiang-Yi Chou S, Cruz-Flores S, Dangayach NS et al (2023) Guideline for the Management of Patients With Aneurysmal Subarachnoid Hemorrhage: A Guideline From the American Heart Association/American Stroke Association. Stroke 54(7):E314–E370
2. Thompson BG, Brown RD, Amin-Hanjani S, Broderick JP, Cockroft KM, Connolly ES et al (2015) Guidelines for the Management of Patients With Unruptured Intracranial Aneurysms: A Guideline for Healthcare Professionals From the American Heart Association/American Stroke Association. Stroke 46(8):2368–2400
3. Pierot L, Wakhloo AK (2013) Endovascular treatment of intracranial aneurysms: Current status. Stroke 44(7):2046–2054
4. Atallah E, Saad H, Mouchtouris N, Bekelis K, Walker J, Chalouhi N et al (2019) Pipeline for distal cerebral circulation aneurysms. Clin Neurosurg 85(3):E477–E484
5. Ma C, Zhu H, Liang S, Liang F, Han J, Jia Z et al (2022) Pipeline for the treatment of distal cerebral circulation aneurysms: A multicenter study focusing on periprocedural Complications. Interventional Neuroradiol 28(6):708–718
6. Scarcia L, Clarençon F, Dmytriw AA, Shotar E, Premat K, Jabbour P et al (2024) Flow-diverting stents for the treatment of unruptured distal anterior cerebral artery aneurysms: analysis of the CRETA Registry. J Neurointerv Surg 17(12):1270–1276. https://doi.org/10.1136/jnis-2024-022315
7. Lasjaunias PBA, ter BKG (2001) Surgical Neuroangiography. Volume 1: Functional Anatomy of Craniofacial Arteries, vol 1, 2nd edn. Springer, Berlin
8. Mascitelli JR, Moyle H, Oermann EK, Polykarpou MF, Patel AA, Doshi AH et al (2015) An update to the Raymond–Roy Occlusion Classification of intracranial aneurysms treated with coil embolization. J Neurointerv Surg 7:496–502
9. Vilardo M, Günkan A, Dmytriw AA, Elek A, Scarramal JPL, Bocanegra-Becerra JE et al (2025) Efficacy and Safety of Flow Diversion for Distal Anterior Cerebral Aneurysms: A Systematic Review and Proportional Meta-Analysis. Am J Neuroradiol 47(1):66–72. https://doi.org/10.3174/ajnr.A8926
10. Cagnazzo F, Fanti A, Lefevre PH, Derraz I, Dargazanli C, Gascou G et al (2021) Distal anterior cerebral artery aneurysms treated with flow diversion: experience of a large-volume center and systematic review of the literature. J Neurointerv Surg 13(1):42–48
11. Cagnazzo F, Perrini P, Dargazanli C, Lefevre PH, Gascou G, Morganti R et al (2019) Treatment of Unruptured Distal Anterior Circulation Aneurysms with Flow-Diverter Stents: A Meta-Analysis. Am J Neuroradiol 40(4):687–693. https://doi.org/10.3174/ajnr.A6002
12. Porto GBF, Al Kasab S, Sattur MG, Almallouhi E, Lajthia O, Casey MA et al (2021) Endovascular Management of Distal Anterior Cerebral Artery Aneurysms: A Multicenter Retrospective Review. World Neurosurg Oct 154:e421–e427
13. Salsano G, Scarcia L, Clarençon F, Shotar E, Russo R, Bergui M et al (2025) Flow diverter stent for the treatment of ruptured distal anterior cerebral artery: A retrospective multicenter analysis from CRETA registry. Interventional Neuroradiol Aug 4:15910199251348514. https://doi.org/10.1177/15910199251348514
14. Cagnazzo F, Lefevre PH, Mantilla D, Rouchaud A, Morganti R, Perrini P et al (2019) Patency of the supraclinoid internal carotid artery branches after flow diversion treatment. A meta-analysis. J Neuroradiol Feb 46(1):9–14

15. Daou B, Valle-Giler EP, Chalouhi N, Starke RM, Tjoumakaris S, Hasan D et al (2017) Patency of the posterior communicating artery following treatment with the Pipeline Embolization Device. J Neurosurg Feb; 126(2):564–569
16. Dibas M, Vivanco-Suarez J, Galecio-Castillo M, Lopes DK, Hanel RA, Rodriguez-Calienes A et al (2024) Flow Diversion for Intracranial Aneurysms With Incorporated Branch: A Subanalysis From the SEASE International Registry. Stroke: Vascular Interventional Neurol Oct 25(6):e001448. https://doi.org/10.1161/SVIN.124.001448
17. Darsaut TE, Bing F, Salazkin I, Gevry G, Raymond J (2012) Flow Diverters Can Occlude Aneurysms and Preserve Arterial Branches: A New Experimental Model. Am J Neuroradiol Nov 33(10):2004–2009
18. Khanafer A, Henkes H, Cohen J, Albiña-Palmarola P, Gomori JM, Forsting M et al (2024) Endovascular treatment of distal anterior cerebral artery aneurysms using flow modulation devices: mid- and long-term results from a two-center study. Front Neurol Mar 11:15:1368612. https://doi.org/10.3389/fneur.2024.1368612
19. Cilliers K, Page BJ (2016) Detailed description of the anterior cerebral artery anomalies observed in a cadaver population. Annals Anat - Anatomischer Anzeiger Nov 208:1–8
20. Scarcia L, Clarençon F, Dmytriw AA, Shotar E, Jabbour P, Psychogios M et al (2025) Silk Vista Baby for the treatment of distal anterior cerebral artery aneurysms. Neuroradiol Aug 67(8):2167–2177. https://doi.org/10.1007/s00234-025-03678-y
21. Günkan A, Vilardo M, Scarramal JPL, Elek A, Bocanegra-Becerra JE, Cardoso LJC, Dmytriw AA, Alexandre AM, Consoli A, Pereira VM, Onal Y, Clarençon F, Scarcia L (2026) Flow diversion for distal cerebral aneurysms: a systematic review and meta analysis. J Neurointerv Surg 18(4):1033–1041. https://doi.org/10.1136/jnis-2025-023362
22. Baptista AG (1963) Studies on the arteries of the brain. Neurol Oct 13(10):825–825
23. Nossek E, Zumofen DW, Setton A, Potts MB, Raz E, Shapiro M et al (2017) Treatment of distal anterior cerebral artery aneurysms with the Pipeline Embolization Device. J Clin Neurosci Jan 35:133–138
24. Triantafyllou G, Paschopoulos I, Kamoutsis K, Papadopoulos-Manolarakis P, Valenzuela-Fuenzalida JJ, Sanchis-Gimeno J et al (2025) Morphological Variations of the Anterior Cerebral Artery: A Systematic Review with Meta-Analysis of 85,316 Patients. Diagnostics Jul 28(15):1893
25. Michelozzi C, Darcourt J, Guenego A, Januel AC, Tall P, Gawlitza M et al (2019) Flow diversion treatment of complex bifurcation aneurysms beyond the circle of Willis: complications, aneurysm sac occlusion, reabsorption, recurrence, and jailed branch modification at follow-up. J Neurosurg Dec; 131(6):1751–1762

Publisher's note Springer Nature remains neutral with regard to jurisdictional claims in published maps and institutional affiliations.

Authors and Affiliations

Arturo Consoli[1,2] · Raffaele Tortora[3] · Frédéric Clarençon[4,5] · Adam A. Dmytriw[6,7] · Eimad Shotar[4] · Pascal Jabbour[8] · Marios Psychogios[9] · Peter Sporns[10] · Ajit S. Puri[11] · Ameer E Hassan[12] · Oktay Algin[13] · Markus A. Möhlenbruch[14] · Riccardo Russo[15] · Oded Goren[16] · Gregoire Boulouis[17] · Takeshi Morimoto[18] · Raoul Pop[19] · Joanna WK Ho[20] · Virginia Pujol Lereis[21] · Jared Cooper[22] · Giancarlo Salsano[23] · Alessandro Sgreccia[1] · Eytan Raz[24] · Julien Burel[25] · Khawaja Muhammad Baqir Hassan[26] · Zhe Ji[27] · Riitta Rautio[28] · Maria Ruggiero[29] · Valerio Da Ros[30] · Joseph Domenico Gabrieli[31] · Michael Levitt[32] · Antonio Armando Caragliano[33] · Christophe Cognard[34] · Gaultier Marnat[35] · Nicola Limbucci[36] · Mariangela Piano[37] · Alexis Guedon[38] · Andrea Romi[39] · Fortunato Di Caterino[40] · Vyval Mykola[41] · Ocílio Ribeiro Gonçalves[42] · Adrien Guenego[43] · Mohamad Abdalkader[44] · Thanh Nguyen[44] · Vitor M. Pereira[6] · Erwah Kalsoum[45] · Aldobrando Broccolini[46,47] · Alessandro Pedicelli[47,48] · Luca Scarcia[45] · Andrea M. Alexandre[48]

✉ Andrea M. Alexandre
andrea.alexandre@policlinicogemelli.it

Arturo Consoli
a.consoli@hopital-foch.com

Raffaele Tortora
rtortora@unisa.it

Frédéric Clarençon
frederic.clarencon@aphp.fr

Adam A. Dmytriw
adam.dmytriw@gmail.com

Eimad Shotar
eimad.shotar@gmail.com

Pascal Jabbour
pascal.jabbour@jefferson.edu

Marios Psychogios
marios.psychogios@usb.ch

Peter Sporns
peter.sporns@hotmail.de

Ajit S. Puri
ajit.puri@umassmemorial.org

Ameer E Hassan
ameerehassan@gmail.com

Oktay Algin
oktay.algin@umram.bilkent.edu.tr

Markus A. Möhlenbruch
markus.moehlenbruch@med.uni-heidelberg.de

Riccardo Russo
russoriccardo18@gmail.com

Oded Goren
ogoren@geisinger.edu

Gregoire Boulouis
gregoireboulouis@gmail.com

Takeshi Morimoto
morimoto@kuhp.kyoto-u.ac.jp

Raoul Pop
pop.raoul@gmail.com

Joanna WK Ho
joannahwk@gmail.com

Virginia Pujol Lereis
vpujol@fleni.org.ar

Jared Cooper
Jared.blaine.cooper@gmail.com

Giancarlo Salsano
giancarlo.salsano@yahoo.it

Alessandro Sgreccia
a.sgreccia@hopital-foch.com

Eytan Raz
eytan.raz@gmail.com

Julien Burel
bureljulien@live.fr

Khawaja Muhammad Baqir Hassan
baqar78@hotmail.com

Zhe Ji
j469826689@126.com

Riitta Rautio
riitta.rautio@varha.fi

Maria Ruggiero
maria.ruggiero@auslromagna.it

Valerio Da Ros
darosvalerio@gmail.com

Joseph Domenico Gabrieli
josephdomenico.gabrieli@aopd.veneto.it

Michael Levitt
mlevitt@uw.edu

Antonio Armando Caragliano
caraglia1987@gmail.com

Christophe Cognard
cognard.c@chu-toulouse.fr

Gaultier Marnat
gaultier.marnat@chu-bordeaux.fr

Nicola Limbucci
nicolalimb@gmail.com

Mariangela Piano
mariangela.piano@ospedaleniguarda.it

Alexis Guedon
alexis.guedon@aphp.fr

Andrea Romi
andrearomimd@gmail.com

Fortunato Di Caterino
dr.fortunatodicaterino@gmail.com

Vyval Mykola
vyval_mykola@ukr.net

Ocílio Ribeiro Gonçalves
ocilio41@gmail.com

Adrien Guenego
adrienguenego@gmail.com

Mohamad Abdalkader
Mohamad.AbdalKader@bmc.org

Thanh Nguyen
Thanh.Nguyen@bmc.org

Vitor M. Pereira
vitor.pereira@unityhealth.to

Erwah Kalsoum
erwah.Kalsoum@aphp.fr

Aldobrando Broccolini
aldobrando.broccolini@policlinicogemelli.it

Alessandro Pedicelli
alessandro.pedicelli@policlinicogemelli.it

Luca Scarcia
lucascarcia@icloud.com

[1] Diagnostic and Interventional Neuroradiology Department, Foch Hospital, Suresnes, France

[2] University of Versailles, Saint Quentin-des-Yvelines, Versailles, France

[3] Interventional and Diagnostic Neuroradiology Unit - Azienda Ospedaliera Universitaria San Giovanni di Dio e Ruggi d'Aragona, Salerno, Italy

[4] Department of Neuroradiology, Pitié-Salpêtrière Hospital, Sorbonne University, APHP, 47, Bd de l'Hôpital, 75013 Paris, France

[5] Sorbonne University, Paris, France

[6] Neurovascular Centre, Divisions of Therapeutic Neuroradiology and Neurosurgery, St. Michael's Hospital, University of Toronto, Toronto, ON, Canada

[7] Department of Neuroradiology, Oxford University Hospitals NHS Foundation Trust, Nuffield Department of Surgical Sciences, Oxford, UK

[8] Department of Neurosurgery, Thomas Jefferson University Hospital, Philadelphia, USA

[9] Diagnostic and Interventional Neuroradiology, Universitätsspital Basel, Basel, Switzerland

[10] Department of Radiology and Neuroradiology, Stadtspital, Zurich, Switzerland

[11] Division of Neurointerventional Radiology, Department of Radiology, University of Massachusetts Medical Center, Worcester, USA

[12] Endovascular Surgical Neuroradiology, Valley Baptist Medical Center - Harlingen, Harlingen, USA

[13] Department of Radiology, Ankara University, Ankara, Turkey

[14] Interventional Neuroradiology, Department of Neuroradiology, Heidelberg University Hospital, Heidelberg, Germany

[15] Department of Neuroscience, Neuroradiological Unit, University of Turin, Azienda Ospedaliera Città della Salute e della Scienza Hospital, Turin, Italy

[16] Department of Neurosurgery, Geisinger Health System, Danville, Pennsylvania, USA

[17] Department of Interventional Neuroradiology, Tours University Hospital, Tours, France

[18] Department of Clinical Epidemiology, Hyogo Medical University, Nishinomiya, Japan

[19] Interventional Neuroradiology Department, Strasbourg University Hospitals, Strasbourg, France

[20] Department of Neurosurgery, Kwong Wah Hospital, Hong Kong, China

[21] Servicio de Neurología Vascular, Departamento de Neurología, Fleni, Argentina

[22] Department of Neurosurgery, Westchester Medical Center, New York, USA

[23] UOC Neuroradiologia, Ospedale San Martino, Genova, Italy

[24] Department of Radiology, NYU Langone Health, New York, New York, USA

[25] Department of Radiology, Rouen University Hospital, Rouen, Normandy, France

[26] Department of Neuroradiology, Lahore General Hospital, Lahore, Pakistan

[27] Department of Neurosurgery, Xuanwu Hospital, Capital Medical University, Beijing, China

[28] Department of Interventional Radiology, Turku University Hospital, Turku, Finland

[29] Neuroradiology Unit, AUSL Romagna, Cesena, Italy

[30] Department of Biomedicine and Prevention, University hospital of Rome "Tor Vergata", Rome, Italy

[31] Neuroradiology Unit, Policlinico Universitario di Padova, Padova, Italy

[32] Department of Neurological Surgery, University of Washington, Washington, USA

[33] Neuroradiology Unit, Biomedical Sciences and of Morphologic and Functional Images, AOU Policlinico G. Martino, Messina, Italy

[34] Service de Neuroradiologie Interventionnelle et Diagnostique, Hôpital Purpan– CHU Toulouse, Toulouse, France

[35] Neuroradiology Department, Bordeaux University Hospital, Bordeaux, France

[36] Interventional Neurovascular Unit, A.O.U. Careggi, Firenze, Italy

[37] Neuroradiology Unit, ASST Grande Ospedale Metropolitano Niguarda, Milano, Italy

[38] Department of Neuroradiology, AP-HP Nord, Hôpital Lariboisière, 75010, Paris, France

[39] Neuroradiology Unit, IRCCS Policlinico San Matteo, 27100 Pavia, Italy

[40] Department of Interventional Neuroradiology, University Hospital Centre Besancon, Besançon, France

[41] Research and Practical Centre for Endovascular Neuroradiology, the NAMS of Ukraine, Kyiv, Ukraine

[42] Federal University of Piauí, Teresina, Brazil

[43] Department of Diagnostic and Interventional Neuroradiology, Erasme University Hospital, Brussels, Belgium

[44] Department of Radiology, Boston University Chobanian and Avedisian School of Medicine, Boston, MA, USA

[45] Department of Neuroradiology, Henri Mondor Hospital, Créteil, France

[46] UOC Neurologia, Fondazione Policlinico Universitario A.Gemelli IRCCS Roma, Rome, Italy

[47] Università Cattolica del Sacro Cuore, Rome, Italy

[48] UOSD Neuroradiologia Interventistica, Fondazione Policlinico Universitario A.Gemelli IRCCS Roma, Rome, Italy