Nephrol Dial Transplant (1999) 14: 2019–2021

Nephrology
Dialysis
Transplantation

Case Report

Tuberculosis of the skull in a patient on maintenance haemodialysis

Gökhan Nergizoğlu[1], Neval Duman[1], Şehsuvar Ertürk[1], Kenan Keven[1], Kenan Ateş[1], Harun Akar[1], Gülşah Bademci[2], Çağlar Berk[2], Selim Erekul[3], Bülent Erbay[1], Oktay Karatan[1] and A. Ergün Ertuğ[1]

Departments of [1]Nephrology, [2]Neurosurgery and [3]Pathology, Ankara University Medical School, Ibni Sina Hospital, Ankara, Turkey

Key words: haemodialysis; skull; tuberculosis

Introduction

The incidence of tuberculosis (TB) is increased in chronic haemodialysis (HD) patients, especially in areas where the disease is endemic in the general population [1–3]. Impairment of cellular immune function in chronic renal failure may have a role in the pathogenesis. Extrapulmonary manifestations such as lymph nodes and skeletal involvement seem to be more frequent in HD patients [4,5]. Skeletal TB accounts for 1% of all tuberculosis infections. Primary TB of the skull is very rare [6,7].

Case

A 38-year-old man was admitted to the hospital because of progressive painless right frontal swelling. He had been diagnosed with end-stage renal disease of unknown aetiology, and had been on maintenance HD treatment for 2 years. The patient did not have a history of diabetes or alcohol consumption. There was no history of TB in either his past or his family.

On physical examination, the blood pressure was 110/70 mmHg, pulse was 78/min, and the body temperature was 36.7°C. On the right frontal region, there was a soft, painless swelling of 3×5 cm in diameter. No erythema or sinus was noticed on the lesion. Other systems were normal and no abnormal findings were found on neurological assessment. Laboratory tests revealed the following: white blood cell count 12 300/mm^3, platelet count 278 000/mm^3, haematocrit level 29%, erythrocyte sedimentation rate 126 mm/h. Chest X-ray, computerized tomography (CT), and abdominal ultrasonography were normal. Urine and sputum cultures were negative for *Mycobacterium tuberculosis*. A slight increase in α_2-globulin was found on protein electrophoresis. The X-ray of the skull showed a well-circumscribed solitary osteolytic bone defect in the frontal bone (Figure 1). Cranial CT scan confirmed the bony defect and documented the presence of a sequestrum in the right frontal region (Figure 2). Fine-needle aspiration of the lesion yielded purulent material. Microbiological culture including for anaerobes and fungi, Gram staining, and acid-resistant bacilli screenings were all negative.

The patient underwent surgery. The lesion was

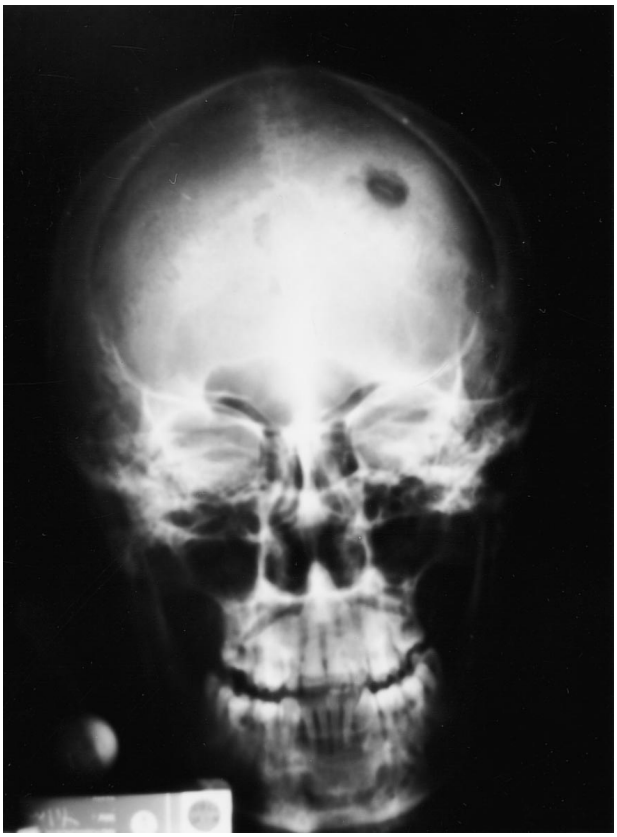

Fig. 1. A-P skull X-ray shows a left frontal lytic lesion.

Correspondence and offprint requests to: Gökhan Nergizoğlu, Şehit Cemalettin Cad., 117/7, Aydnlkevler, Ankara, 06130, Turkey.

© 1999 European Renal Association–European Dialysis and Transplant Association

Downloaded from https://academic.oup.com/ndt/article/14/8/2019/1808544 by ANKARA UNIVERSITY user on 11 December 2021



Fig. 2. CT revealed a well-circumscribed lytic lesion located in the frontal bone with reactive hyperostosis.

excised totally by frontal craniectomy. Bone removal was extended until the margins were composed of visually healthy bone. Samples were taken for microbiological investigation. Neither acid-resistant bacilli nor other micro-organisms were found. PAS staining did not show fungal infection. Histological examination of the excised bone and granulation tissue revealed heavy fibrovascular connective tissue with foci of necrosis and diffuse lymphocytic infiltration. Granulomatous areas with multinuclear giant cells were prominent. These features of chronic granulomatous inflammation are thought to be consistent with TB. Indeed, a polymerase chain reaction (PCR) assay for the identification of *M. tuberculosis*, based on amplification of a 123 base pair region of IS6110 insertion sequences in paraffin-embedded tissue [8], was found to be positive. The postoperative course was uneventful and antituberculous treatment was started immediately and continued for 12 months. Partial healing on the lytic lesion was noted. At the last follow-up there was no evidence of recurrence.

Discussion

There are several reports on a high frequency of TB in patients on maintenance HD in different countries [3,9–12]. Common presentations were low-grade fever, anorexia, weight loss, and generalized weakness. The most common localizations were lymph nodes and lung, and occasionally skeleton. In one study, 18 of 23 patients with TB on maintenance HD treatment presented with extrapulmonary lesions, mostly lymphadenitis [2].

Primary TB of the skull has been observed in the last century [13], but is rare even in endemic areas. Skull TB is found in approximately 1/10 000 of all TB cases, and about 0.2–1.37% of TB cases affecting the skeletal system [6,7]. In our case, no foci of TB were found in the lungs or urinary tract by CT scan or sputum and urine cultures for *M. tuberculosis*. Skull TB usually presents as painless swelling caused by circumscribed lysis. Lesions may be single or multiple, and cold abscesses are quite common [14,15]. Radiology is not diagnostic, and the diagnosis must be established by microbiological and histological studies [14,15]. Although a definitive diagnosis requires biopsy material with granulomas and/or caseation complemented by acid-fast staining and culture, PCR detection of mycobacterial DNA in paraffin-embedded tissue has been used successfully in recent publications [16,17]. In our patient, whilst the above microbiological investigations for TB were negative, the PCR assay for *M. tuberculosis* in paraffin-embedded operative specimens was positive, and histopathological findings were typical of TB.

Treatment for skull TB includes surgery and antituberculous therapy. Reports before antituberculous chemotherapy showed good results with surgical treatment alone [13]. Although there are some reports that favour antituberculous therapy alone [7,14], recent studies indicate that combination treatment is more appropriate, as extensive areas of diseased bone may be foci of tuberculous bacilli unless surgically removed [18,19].

References

1. Freeman RM, Newhouse CE, Lawton RL. Absence of tuberculosis in dialysis patients (letter). *J Am Med Assoc* 1975; 233: 1356
2. Hussein MM, Bakir N, Roujouleh H. Tuberculosis in patients undergoing maintenance dialysis. *Nephrol Dial Transplant* 1990; 5: 584–587
3. Cengiz K. Increased incidence of tuberculosis in patients undergoing hemodialysis. *Nephron* 1996; 73: 421–424
4. Mitwalli A. Tuberculosis in patients on maintenance dialysis. *Am J Kidney Dis* 1991; 5: 579–582
5. Leventhal Z, Gafter U, Zevin D, Turani H, Levi J. Tuberculosis in patients on hemodialysis. *Isr J Med Sci* 1982; 18: 245–247
6. Davidson PT, Horowitz I. Skeletal tuberculosis. *Am J Med* 1970; 48: 77–84
7. Prinsloo JG, Kirsten GF. Tuberculosis of the skull vault. *S Afr Med J* 1977; 51: 248–250
8. Eisenach KD, Cave MD, Bathes JH, Crafford JT. Polymerase chain reaction amplification of a repetitive DNA sequence for *Mycobacterium tuberculosis*. *J Clin Microbiol* 1990; 161: 977–981
9. Papadimitriou M, Memmos D, Metaxas P. Tuberculosis in patients on regular hemodialysis. *Nephron* 1979; 24: 53–57
10. Sasaki S, Akiba T, Suenaga N. Ten years' survey of dialysis-associated tuberculosis. *Nephron* 1979; 24: 141–145
11. Jones RH, Weston MJ, Bewick M, Parsons V. The management of tuberculosis occurring in patients with chronic renal failure requiring renal dialysis therapy or transplantation (Abstr). *14th Congress of the European Dialysis and Transplant Association*, Helsinki, 1977, 41
12. Pradhan RP, Katz LA, Nidus BD, Matalon R, Eisinger RP. Tuberculosis in dialyzed patients. *J Am Med Assoc* 1974; 229: 798–802
13. Strauss DC. Tuberculosis of the flat bones of the vault of the skull. *Surg Gynecol Obstet* 1933; 57: 384–398
14. LeRoux PD, Griffin GE, Marsh HT, Winn HR. Tuberculosis of the skull—A rare condition: case report and review of the literature. *Neurosurgery* 1990; 26: 851–855
15. Gupta PK, Kolluri VRS, Chandramouli BA, Venkataramana NK, Das BS. Calvarial tuberculosis: a report of two cases. *Neurosurgery* 1989; 25: 830–833
16. Hardman WJ, Benian GM, Howard P, McGowan JE, Metchock B, Murthag JJ. Rapid detection of Mycobacteria in inflammatory necrotizing granulomas from formalin-fixed, paraffin-embedded tissue by PCR in clinically high-risk patients

Downloaded from https://academic.oup.com/ndt/article/14/8/2019/1808544 by ANKARA UNIVERSITY user on 11 December 2021

with acid-fast stain and culture-negative tissue biopsies. *Am J Clin Pathol* 1996; 106: 384–389
17. Salian NV, Rish JA, Eisenach KD, Cave MD, Bates JH. Polymerase chain reaction to detect *Mycobacterium tuberculosis* in histologic specimens. *Am J Respir Crit Care Med* 1998; 158: 1150–1155
18. Mohanty S, Rao CJ, Mukherjee KC. Tuberculosis of the skull. *Int Surg* 1981; 66: 81–83
19. Ip M, Tsui E, Wong KL, Jones B, Pung CF, Ngan H. Disseminated skletal tuberculosis with skull involvement. *Tuberc Lung Dis* 1993; 74: 211–214

Received for publication: 14.8.98
Accepted in revised form: 1.4.99

Downloaded from https://academic.oup.com/ndt/article/14/8/2019/1808544 by ANKARA UNIVERSITY user on 11 December 2021