Rev Esp Med Nucl Imagen Mol. 2020;xxx(xx):xxx–xxx

Interesting images

Diffuse increased uptake in intrahepatic biliary ducts on ^{18}F-FDG PET/CT in a case with primary sclerosing cholangitis☆

Aumento difuso de la captación en los conductos biliares intrahepáticos en ^{18}F-FDGPET/TC en un caso de colangitis esclerosante primaria

Mine Araz*, Pınar Akkuş, Muhammet Halil Baltacioglu, Cigdem Soydal, K. Metin Kır

Ankara University, Medical School Nuclear Medicine Department, Turkey

We represent a 46 years old female candidate for liver transplantation with primary sclerosing cholangitis. On preoperative diagnostic contrast enhanced abdominal CT, multiple lymphadenopathies in the portal area were detected. ^{18}F-FDG PET/CT was ordered to rule out malignant disease. No focal area of a significantly increased metabolic activity suggestive of malignant disease was detected. Diffuse increased ^{18}F-FDG uptake was seen along the intrahepatic bile ducts, demonstrating the disseminated inflammatory process (Fig. 1).

Primary sclerosing cholangitis is a progressive cholestatic disease and frequently ends up with liver failure. It is characterized by inflammation, fibrosis and strictures of intra-extrahepatic biliary ducts. Although etiology is still not exactly known, the most accepted theory is the autoimmune mechanism and inflammatory response to accumulated bacteria and bile salts precipitating due to cholestasis.[1] ^{18}F-FDG is the most commonly used radiopharmaceutical in nuclear oncology. Nonspecific uptake mechanism of ^{18}F-FDG by tumor cells is also possible by inflammatory cells with increased metabolic activity. Thus, its role in detection, follow up and therapy response assessment of benign conditions like systemic inflammatory diseases has also been reported. Radiological imaging modalities like USG, CT and MRI are most frequently used in follow up of PSC. Secondary malignancies like hepatobiliary cancer and colon cancer may develop in advanced disease. ^{18}F-FDG PET/CT is indicated to rule out secondary malignancies and for screening before transplantation. Some authors have also reported that it can be beneficial in follow up of strictures in PSC.[2,3] However, these studies are focused on the intensity of the tracer uptake (mostly represented with SUV) in order to detect carcinoma. However, the distribution pattern has not been considered before.

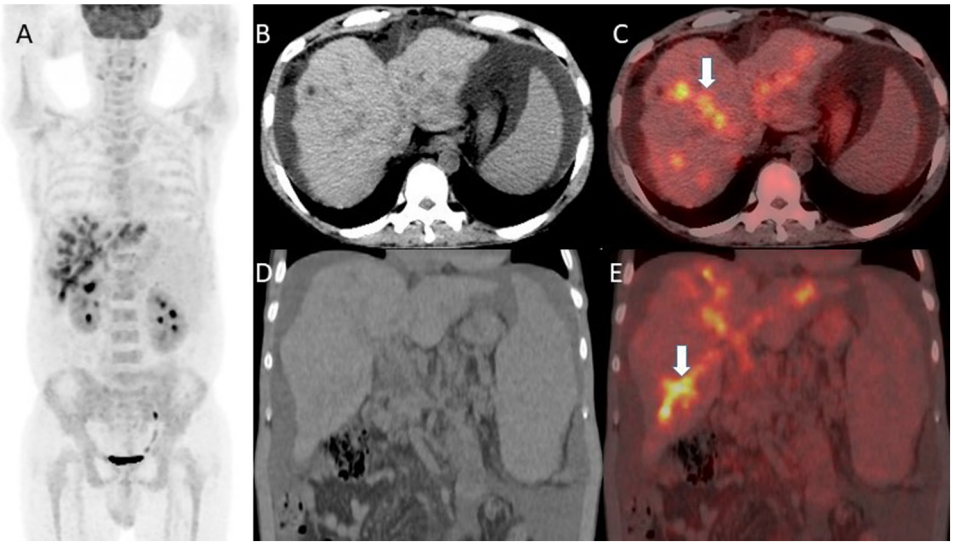

Fig. 1. Whole body maximum intensity projection (MIP) (A), axial computerized tomography (CT) (B), axial fusion (C) coronal CT (D) and coronal fusion (E) images of liver Diffuse linear increased ^{18}F-FDG uptake was seen throughout the intrahepatic bile ducts (SUVmax:8.0), probably due to inflammatory process, together with mild radiotracer uptake in the periportal lymph nodes (SUVmax:4.6).

☆ Please cite this article as: Araz M, Akkuş P, Baltacioglu MH, Soydal C, Kır KM. Aumento de la captación difusa en los conductos biliares intrahepáticos en la PET/TC con ^{18}F-FDG en un caso con colangitis esclerosante primaria. Rev Esp Med Nucl Imagen Mol. 2020. https://doi.org/10.1016/j.remn.2020.09.004

* Corresponding author.
E-mail address: minesoylu@yahoo.com (M. Araz).

2253-8089/© 2020 Sociedad Española de Medicina Nuclear e Imagen Molecular. Published by Elsevier España, S.L.U. All rights reserved.

In this case, supporting previous publications, we presented the visualisation of diffuse ^{18}F-FDG uptake of intrahepatic bile ducts, almost mapping the inflammatory process of the whole biliary tree in advanced stage PSC, which is to the best of our knowledge, the most striking image of PSC detected by ^{18}F-FDG PET/CT. Diffuse linear uptake should be indicative of benign process anyway, even if a high value of uptake is calculated.

Acknowledgements

None to declare.

References

1. Lee YM, Kaplan MM. Primary sclerosing cholangitis. N Engl J Med. 1995;332:924.
2. Alkhawaldeh K, Faltten S, Biersack HJ, Ezziddin S. The values of F-8 FDG PET in patients with primary sclerosing cholangitis and cholangiocarcinoma using visual and semiquantitative analysis. Clin Nucl Med. 2011;36:879–83.
3. Sangfelt P, Sundin A, Wanders A, Rasmussen I, Karlson BM, Bergquist A, et al. Monitoring dominant strictures in primary sclerosing cholangitis with brush cytology and FDG-PET. J Hepatol. 2014;61:1352–7.