Check for updates

Ear, Nose & Throat Journal
1–3
© The Author(s) 2021
Article reuse guidelines:
sagepub.com/journals-permissions
DOI: 10.1177/0145561321989433
journals.sagepub.com/home/ear
SAGE

Incidentally Found Killian-Jamieson Diverticulum During Thyroidectomy: A Case Report

Levent Yücel, MD[1], Nurlan Isayev, MD[2], Süha Beton, MD[2], Mustafa Kürşat Gökcan, MD[2], and Tarık Babür Küçük, MD[2]

Abstract

The aim of this case study is to demonstrate the very rare coincidental existence and management of a Killian-Jamieson diverticulum (KJD) during thyroid surgery. A 57-year-old woman was referred to our clinic with a malignant thyroid nodule and the complaint of a sore throat. There were no suspicions concerning a diverticulum on examining her with flexible laryngoscopy or ultrasound imaging. During the right central neck dissection, we noticed a 3 × 3 cm KJD and resected it while preserving the recurrent laryngeal nerve. After the successful operation, we questioned the patient and learned that for 1 year she had an occasional complaint of dysphagia. Postoperatively, there was no vocal cord palsy or hypocalcemia, and there was no pharyngoesophageal leak after oral alimentation. There was no recurrence or complaint for KJD or papillary carcinoma for 8 years follow-up. Nonspecific symptoms like a sore throat should be investigated, and patients should be questioned for all aerodigestive symptoms. If necessary, further investigation should be undertaken for a differential diagnosis.

Keywords

diverticulum, deglutition disorders, thyroidectomy, thyroid neoplasms

Introduction

Killian-Jamieson diverticulum (KJD), first described by Ekberg and Nylander in 1983, is a lateral pharyngoesophageal diverticulum,[1] a rare disease that originates from the anterolateral wall of the proximal esophagus. The recurrent laryngeal nerve (RLN) enters the pharynx in this anatomic region that has lower muscle resistance. The pathogenesis of KJD is still unclear, but is thought to be caused by discoordinated pharyngeal constrictor muscles, structural weakness, or cricopharyngeal muscle dysfunction.[2] Killian-Jamieson diverticulum is very rare and occurs in approximately 0.025% of the population.[3]

The detection of KJD often occurs incidentally on neck ultrasonography. Killian-Jamieson diverticulum may mimic a thyroid nodule on ultrasonography, and there have been several cases in which fine-needle aspiration was performed due to misdiagnosis.[3] We present the case of a patient who underwent surgery because of a papillary thyroid carcinoma and KJD was found incidentally. Our aim is to demonstrate a very rare example and management of KJD in a thyroid carcinoma patient.

Case Report

A 57-year-old woman was referred to our clinic with a malignant thyroid nodule. The patient's only complaint was a sore throat. The physical and upper endoscopic examination was normal, and her medical history included diabetes mellitus and hypertension. An ultrasonographic examination revealed an echogenic 4.5 × 5.5 mm nodule on the right thyroid lobe and a 24 × 9.5 mm pathologic lymphadenopathy with microcalcification at level 4 of the neck. A fine needle aspiration

[1] Department of Otorhinolaryngology, University of Health Sciences, Gülhane Training and Research Hospital, Ankara, Turkey
[2] Department of Otorhinolaryngology, Faculty of Medicine, University of Ankara, Ankara, Turkey

Received: December 19, 2020; accepted: January 03, 2021

Corresponding Author:
Levent Yücel, MD, Department of Otorhinolaryngology, Gülhane Training and Research Hospital, General Dr. Tevfik Sağlam Street, No: 1, Etlik/Ankara 06010, Turkey.
Email: leventyucel51@hotmail.com

Creative Commons Non Commercial CC BY-NC: This article is distributed under the terms of the Creative Commons Attribution-NonCommercial 4.0 License (https://creativecommons.org/licenses/by-nc/4.0/) which permits non-commercial use, reproduction and distribution of the work without further permission provided the original work is attributed as specified on the SAGE and Open Access pages (https://us.sagepub.com/en-us/nam/open-access-at-sage).

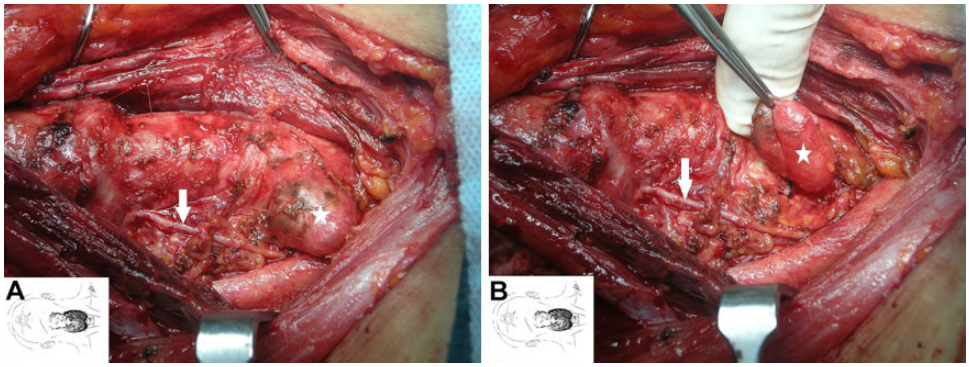

Figure 1. A and B, The KJD from lateral wall of esophagus (white arrow: right RLN, asterix: KJD).

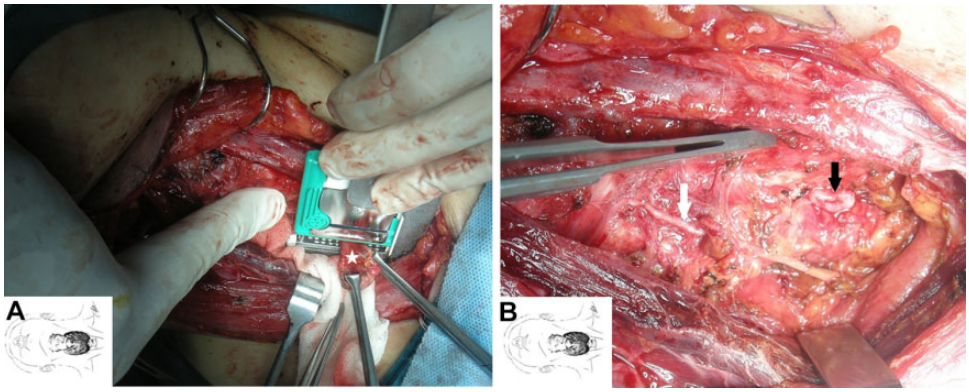

Figure 2. A and B, Diverticulectomy with stapler (A) and view after resection (B) (asterix: KJD, black arrow: wall of diverticulum after resection, white arrow: right RLN).

biopsy was performed on the nodule on the right thyroid lobe; the result was a papillary microcarcinoma. There were no suspicions of diverticulum after examination with flexible laryngoscopy or ultrasound imaging. Intraoperatively, we performed a right level 2-5 neck dissection, and after identification of the right RLN, dissected the thyroid lobe and isthmus. When we performed the right central neck dissection, we noticed a different, 3 × 3 cm mass from the lateral wall of the esophagus (Figure 1A, B). The diagnosis was diverticulum after we aspirated the air with a fine needle. The patient's family was informed about this unexpected situation and a thoracic surgery consultation was given. After left thyroid lobectomy and central neck dissection, the thoracic surgeon resected the KJD with a stapler and sutured the walls of the diverticulum (Figure 2A, B).

Postoperatively, no vocal cord palsy or hypocalcemia was observed. When the patient was questioned after surgery, we learned that she had experienced an occasional complaint of dysphagia for 1 year. After 13 days of nasogastric feeding, oral alimentation was started. There was no pharyngoesophageal leak after oral alimentation. A histopathological examination of the specimen determined a papillary thyroid microcarcinoma and lateral neck metastasis in one lymph node at level 4. A histopathological examination of the diverticulum material revealed a false diverticulum without a muscular layer. The patient received once 150 mCi adjuvant radioactive iodine (^{131}I) therapy. There was no recurrence or complaint for KJD or papillary carcinoma for 8 years follow-up.

Conclusion

Killian-Jamieson diverticulum is a pharyngoesophageal diverticulum in the anterolateral wall of the proximal cervical esophagus, different from a Zenker diverticulum (ZD), that arises on the posterior wall. In the literature, KJD has been described on the left side, but our case was on the right side.[2] The real incidence of KJD is unclear since it may be asymptomatic, in contrast to ZD. The intact cricopharyngeal function in KJD may be the cause of less pronounced symptoms compared to ZD.[4] In our case, a sore throat was a nonspecific complaint that did not suggest diverticulum.

Killian-Jamieson diverticulum can mimic a thyroid nodule in ultrasonographic examinations because of their close location. The misdiagnoses of diverticulum include adenomas, thyroid abscesses, lymphadenopathy, parathyroid hyperplasia or adenoma, pharyngeal or paratracheal air abscesses.[5]

Misdiagnosed cases with fine needle aspiration biopsy have been also described.[6]

The signs of diverticulum on ultrasonography are air bubbles inside the diverticulum, changes in shape during swallowing, the presence of a peripheral echogenic line, hypoechoic rims, and central or peripheral echogenic foci.[7] In our case, there was no doubt of a diverticulum in her radiological examinations.

The detection of a diverticulum during thyroid surgery can include many problems, such as esophageal perforation. Due to that, patients, especially thyroid patients, should be questioned in terms of aerodigestive symptoms. Such symptoms may be considered to have occurred as a result of a multinodular goiter, as reported previously.[8] If there is clinical doubt, barium esophagography, the gold standard for the diagnosis of diverticulum, should be performed.

The management of KJD is controversial. Even if successful endoscopic diverticulectomy has been described, the endoscopic treatment of KJD includes a risk for RLN injury because of its close proximity.[4,9,10] Therefore, most surgeons prefer open cervical diverticulectomy regardless of diverticula size, with identification of the RLN.[2] However, the endoscopic treatment of ZD is preferable according to diverticula size.

In conclusion, KJD is a very rare disease that may be asymptomatic. As in our case, nonspecific symptoms like a sore throat should be investigated and patients should be questioned regarding all aerodigestive symptoms. If necessary, further investigation should be undertaken for a differential diagnosis.

Authors' Note

Written informed consent was obtained from patient who participated in this study. Conception—L.Y.; Design—N.I., S.B.; M.K.G.; Supervision—S.B., M.K.G., T.B.K.; Fundings—Not applicable; Data Collection and/or Processing—L.Y., N.I.; Analysis and/or Interpretation—L.Y., S.B.; Literature Review—L.Y., N.I., S.B., M.K.G., T.B.K.; Writing Manuscript—L.Y.; Critical Review – L.Y., N.I., S.B., M.K.G., T.B.K.

Acknowledgments

Thanks to Serkan Enön, MD, at Department of Thoracic Surgery, Faculty of Medicine, University of Ankara, who performed surgery for Killian-Jamieson diverticulum.

Declaration of Conflicting Interests

The author(s) declared no potential conflicts of interest with respect to the research, authorship, and/or publication of this article.

Funding

The author(s) received no financial support for the research, authorship, and/or publication of this article.

ORCID iD

Levent Yücel https://orcid.org/0000-0001-9045-4636

References

1. Ekberg O, Nylander G. Lateral diverticula from the pharyngoesophageal junction area. *Radiology*. 1983;146(1):117-122. doi:10.1148/radiology.146.1.6401363
2. Haddad N, Agarwal P, Levi JR, Tracy JC, Tracy LF. Presentation and management of Killian Jamieson diverticulum: a comprehensive literature review. *Ann Otol Rhinol Laryngol*. 2020;129(4):394-400. doi:10.1177/00034894198874
3. Saisho K, Matono S, Tanaka T, et al. Surgery for Killian-Jamieson diverticulum: a report of two cases. *Surg Case Rep*. 2020;6:1-6. doi:10.1186/s40792-020-0789-0
4. Siow SL, Mahendran HA, Hardin M. Transcervical diverticulectomy for Killian–Jamieson diverticulum. *Asian J Surg*. 2017;40(4):324-328. doi:10.1016/j.asjsur.2015.01.007
5. Mimatsu K, Oida T, Kano H, et al. Killian-Jamieson diverticula presenting synchronously with thyroid adenoma. *Case Rep Gastroenterol*. 2013;7(1):188-194. doi:10.1159/000350672
6. Walts AE, Braunstein G. Fine-needle aspiration of a paraesophageal diverticulum masquerading as a thyroid nodule. *Diagn Cytopathol*. 2006;34(12):843-845. doi:10.1002/dc.20570
7. Çildag B, Tunçyürek Ö, Ertekin E, Çildag S. Ultrasonographic features of pharyngoesophageal diverticulum in a case misdiagnosed as a thyroid nodule: a case report and review of the literature. *ENT Updates*. 2016;6(2):101. doi:10.2399/jmu.2016002007
8. Saylam G, Keseroğlu K, Bayır Ö, Tatar EÇ, Korkmaz MH. Coincidental Killian-Jamieson diverticulum during thyroid surgery: a rare cause of dysphagia. *Turk Arch Otorhinolaryngol*. 2016;54(4):165. doi:10.5152/tao.2016.1807
9. Lee CK, Chung I-K, Park J-Y, et al. Endoscopic diverticulotomy with an isolated-tip needle-knife papillotome (Iso-Tome) and a fitted overtube for the treatment of a Killian-Jamieson diverticulum. *World J Gastroenterol*. 2008;14(42):6589. doi:10.3748/wjg.14.6589
10. Yang D, Draganov PV. Endoscopic Killian–Jamieson diverticulotomy using a scissor-type electrosurgical knife. *Endoscopy*. 2018;50(7):E175-E176. doi:10.1055/a-0601-6467