Clin Kidney J (2014) 7: 219–220

CKJ

From the Clinic

Colchicine-resistant familial Mediterranean fever in a renal transplantation patient: successful treatment with anakinra

Background

Familial Mediterranean fever (FMF) is an autosomal recessively inherited autoinflammatory disease characterized by recurrent fever, abdominal pain and arthritis. It is common in Turks, Arabs and non-Ashkenazi Jews, and uncontrolled disease can result in AA amyloidosis [1]. Colchicine is a microtubule -depolymerizing drug widely used in the treatment of gout arthritis and in the prevention of FMF attacks and development of secondary amyloidosis. Although colchicine is a very effective drug in preventing FMF attacks, ∼5–15% of FMF patients are resistant to regular colchicine treatment and have recurrent attacks [2]. These patients have been treated with alternative adjunctive treatments such as thalidomide, etanercept, interferon alpha and anakinra to suppress autoinflammation [3].

Herein, we present a patient with colchicine-resistant FMF attacks after living-unrelated kidney transplantation. The patient became attack free with the initiation of anakinra, an interleukin (IL)-1 receptor (IL-1R) antagonist, as an adjunctive treatment.

Case report

Our patient, a 46-year-old woman was diagnosed with FMF in 1986 on the basis of recurrent abdominal pain, arthritis and fever. She had a homozygous M694V, MEFV gene mutation, in exon 10. Her family history was positive for FMF.

The patient had proteinuria since 1999 and her creatinine level increased in 2010 after pregnancy. Amiloid A amyloidosis was diagnosed by rectal biopsy. In January 2012, the patient developed end-stage renal disease (ESRD) and was started on chronic haemodialysis treatment. She had used 1.5 mg/day colchicine for 13 years, but with the development of ESRD, the colchicine dose was reduced to 0.5 mg/day.

The patient underwent kidney transplantation from an unrelated donor (paired kidney) in February 2012. She had a negative panel-reactive antibody and there were six mismatches. Basiliximab was used for induction. The kidney functioned immediately after transplantation. The patient was on prednisolone, tacrolimus and mycophenolate mofetil (MMF) upon discharge. Her creatinine level was 79.2 mmol/L (0.9 mg/dL) during the first month. After transplantation, her colchicine dose was increased to 1.0 mg/day. While her C-reactive protein (CRP) levels were between 25 and 40 mg/dL before transplantation, they dropped immediately after transplantation. In the fourth month, the patient was admitted to the emergency department with fever, right ankle arthritis and diarrhoea, and her creatinine was increased to 114.4 mmol/L (1.3 mg/dl). Stool, urine and blood cultures showed no abnormality, and cytomegalovirus (CMV) DNA was negative. Colchicine was stopped, but the diarrhoea persisted. MMF was decreased and then switched to azathioprine. Although colchicine was restarted at 1.0 mg/day, CRP remained high (around 30 mg/dL) and her arthritis in the right ankle persisted. The patient had difficulty walking and had inflammatory symptoms including a decrease in appetite, subfebrile temperature, depression and inability to go to work. The patient was admitted to the hospital on several occasions due to recurrent ankle arthritis, fever and depression during this period. Despite these symptoms, her creatinine level was stable, at ∼105.6 mmol/L (1.2 mg/dL); CRP levels remained high and were the highest in December 2012 (60 mg/dL), but no infection was determined at that time.

We considered the patient to have colchicine-resistant FMF and started her on IL-1 antagonist (anakinra) treatment at 100 mg/day at the end of January 2013. Her leukocyte count and liver function tests were normal. After initiation of anakinra, all of her symptoms resolved and her CRP level normalized (Figure 1). She experienced no side effects or infection after the initiation of anakinra. She returned to work and reported feeling better. At the eighth month of follow-up after anakinra initiation, the patient remains asymptomatic, and has been able to work; her CRP and creatinine levels are ∼3–5 mg/dL and 88 mmol/L (1.0 mg/dl), respectively.

Discussion

We report herein that colchicine-resistant FMF can be treated successfully with anakinra in kidney transplant recipients. Interestingly, our patient was asymptomatic while on haemodialysis and until 3 months after the transplantation. In the fourth month, the patient developed severe autoinflammation due to FMF attacks, which could not be controlled with colchicine. With the initiation of anakinra, her symptoms resolved and CRP levels normalized.

As seen in Figure 1, there are two rapid declines in CRP levels. The first is immediately after the transplantation. This might be explained by the use of high-dose steroid-blocking at each step of inflammation through IL-1 and 2—tacrolimus-blocking IL-2 induces activation of T cells and also inhibits the CYP3A4 system, which is important for the elimination of colchicine and the IL-2 receptor (IL-2R) antagonist, basiliximab. Soluble IL-2R has been shown to be capable of efficiently binding IL-2; it could therefore act by binding to free IL-2, either to inhibit its interaction with cell surface receptors or alternatively to function as a transport protein. It can thus be a marker of cellular immune activation or sub-serve an important immunoregulatory function. There are some articles showing increased soluble IL-2Rs in serum samples of patients with FMF during attack and increased inflammatory markers [4]. Therefore, IL-2R blockage can suppress the FMF-induced autoinflammation during the early period after transplantation. However, there is no study showing the effect of the IL-2R antagonist basiliximab in FMF patients.

© The Author 2014. Published by Oxford University Press on behalf of ERA-EDTA. All rights reserved.
For permissions, please email: journals.permissions@oup.com.

Downloaded from https://academic.oup.com/ckj/article/7/2/219/448693 by ANKARA UNIVERSITESI user on 12 December 2021

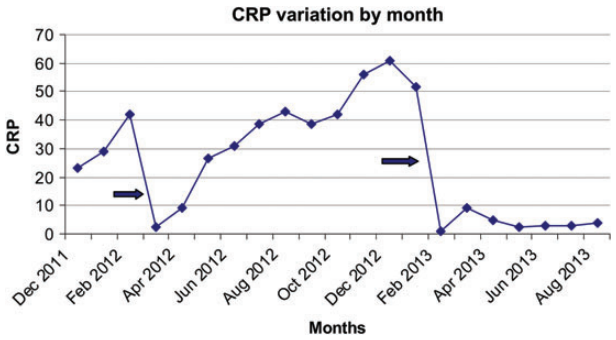

Fig. 1. Left arrow shows the time of renal transplantation and right arrow the initiation of anakinra.

A second decline was seen at the time of initiation of anakinra. The underlying mechanism of inflammation in FMF is thought to be the uncontrolled release of IL-1β due to MEFV gene mutation, which encodes the protein pyrin. IL-1 is a potent proinflammatory cytokine, and serum levels are increased during FMF attacks. Anakinra is an IL-1R antagonist that inhibits the binding of IL-1α and IL-1β to IL-1R and prevents inflammation [5]. There are many cases describing treatment with anakinra in both children and adults. It seems to be effective in preventing attacks and inflammation and perhaps amyloidosis [5–7]. No serious complication or adverse event has been reported with the use of the drug, but like all biologic drugs, risk of infection is increased when compared with placebo. Therefore, the patient should be carefully followed when using anakinra.

In conclusion, anakinra can be an effective and safe adjunctive drug to colchicine for prevention of FMF attacks in colchicine-refractory patients, even after kidney transplantation. Further studies are needed to assess the safety and long-term efficacy of anakinra in these patients.

Conflict of interest statement. All authors made substantial contributions to the conception and design of the work, interpretation of data for the work and drafting. All authors declare that there is no conflict of interest. The informed consent is obtained from the patient. All authors declare that the results presented in this paper have not been published previously in whole or part, except in abstract format.

[1]Nephrology Department, Ankara University School of Medicine, SİNa Hospital, Ankara, Turkey
[2]Rheumatology Department, Ankara University School of Medicine, Ankara, Turkey
[3]General Surgery Department, Ankara University School of Medicine, Ankara, Turkey

Zeynep Kendi Celebi[1]
Orhan Kucuksahin[2]
Sule Sengul[1]
Acar Tuzuner[3]
Kenan Keven[1]

Correspondence and offprint requests to: Zeynep Kendi Celebi; e-mail: zeynepkendi@yahoo.com

References

1. Tuglular S, Yalcinkaya F, Paydas S *et al*. A retrospective analysis for aetiology and clinical findings of 287 secondary amyloidosis cases in Turkey. *Nephrol Dial Transplant* 2002; 17: 2003–2005
2. Ben-Chetrit E, Ozdogan H. Non-response to colchicine in FMF—definition, causes and suggested solutions. *Clin Exp Rheumatol* 2008; 26(Suppl 50): S49–S51
3. Seyahi E, Ozdogan H, Celik S *et al*. Treatment options in colchicine resistant familial Mediterranean fever patients: thalidomide and etanercept as adjunctive agents. *Clin Exp Rheumatol* 2006; 24(Suppl 42): S99–103
4. Baykal Y, Saglam K, Yilmaz MI *et al*. Serum sIL-2r, IL-6, IL-10 and TNF-alpha level in familial Mediterranean fever patients. *Clin Rheumatol* 2003; 22: 99–101
5. Alpay N, Sumnu A, Calışkan Y *et al*. Efficacy of anakinra treatment in a patient with colchicine-resistant familial Mediterranean fever. *Rheumatol Int* 2012; 32: 3277–3279
6. Moser C, Pohl G, Haslinger I *et al*. Successful treatment of familial Mediterranean fever with Anakinra and outcome after renal transplantation. *Nephrol Dial Transplant* 2009; 24: 676–678
7. Stankovic Stojanovic K, Delmas Y, Torres PU *et al*. Dramatic beneficial effect of interleukin-1 inhibitor treatment in patients with familial Mediterranean fever complicated with amyloidosis and renal failure. *Nephrol Dial Transplant* 2012; 27: 1898–1901. doi:10.1093/ndt/gfr528

Received for publication: 23.11.13; Accepted in revised form: 12.12.13

doi: 10.1093/ckj/sft164
Advance Access publication 12 January 2014

Downloaded from https://academic.oup.com/ckj/article/7/2/219/448693 by ANKARA UNIVERSITESI user on 12 December 2021