Neuroscience Letters 767 (2022) 136308



Contents lists available at ScienceDirect

Neuroscience Letters

journal homepage: www.elsevier.com/locate/neulet

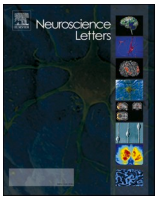



Non-motor connections of the pedunculopontine nucleus of the rat and human brain

Mazhar Özkan [a], Büşra Köse [b], Oktay Algın [c], Sinem Oğuz [b], Mert Emre Erden [b], Safiye Çavdar [b,*]

[a] Department of Anatomy, Tekirdağ Namık Kemal University, School of Medicine, Istanbul, Turkey
[b] Department of Anatomy, Koç University, School of Medicine, Rumelifener Yolu, Istanbul, Turkey
[c] Department of Radiology, City Hospital, Yıldırım Beyazıt University, Ankara, Turkey and National MR Research Center (UMRAM), Bilkent University, Ankara, Turkey

ARTICLE INFO

Keywords:
Pedunculopontine nucleus
Fluoro-Gold
Non-motor connections
Diffusion tensor tractography

ABSTRACT

Introduction: The connections of the pedunculopontine nucleus (PPN) with motor areas of the central nervous system (CNS) are well described in the literature, in contrast relations with non-motor areas are lacking. Thus, the aim of the present study is to define the non-motor connections of the PPN in rats using the fluoro-gold (FG) tracer and compare the presence of these connections in healthy human adults using diffusion tensor tractography (DTI).

Materials and Methods: We injected FG into the PPN of 12 rats. The non-motor connections of the PPN with cortical, subcortical, and brainstem structures were documented. The non-motor connections of the rats were compared with the DTI obtained from 35 healthy adults.

Results: The results of the tract-tracing study in the rat showed that the PPN was connected to non-motor cortical (cingulate, somatosensory, visual, auditory, medial frontal cortices), subcortical (amygdala, hypothalamus, thalamus, habenular, and bed nucleus of stria terminalis), and brainstem (medullary reticular, trigeminal spinal, external cuneate, pontine reticular, vestibular, superior and inferior colliculus, locus ceruleus, periaqueductal gray, parabrachial, dorsal raphe, pretectal, lateral lemniscus nuclei, and the contralateral PPN) structures. The DTI obtained from healthy adults showed similar PPN non-motor connections as in rats.

Conclusion: Understanding the connections of the PPN with non-motor cortical, subcortical, and brainstem areas of the CNS will enrich our knowledge of its contribution in various circuits and the areas that PPN activity can influence. Further, it will provide insight into the role of Parkinson's disease and related disorders and explain the non-motor complications which occur subsequent to deep brain stimulation (DBS) of the PPN.

Abbreviations: AIP, Agranular insular cortex, posterior part; APT, Anterior pretectal nucleus; Au1, Primary auditory cortex; AuD, Dorsal auditory cortex; AuV, Ventral auditory cortex; BLA, Basolateral amygdaloid nucleus, anterior part; BLP, Basolateral amygdaloid nucleus, posterior part; BNST, Bed nucleus of stria terminalis; CeC, Central amygdaloid nucleus, capsular part; CeL, Central amygdaloid nucleus, lateral division; CeM, Central amygdaloid nucleus, medial division; Cg1, Cingulate cortex, area 1; Cg2, Cingulate cortex, area 2; DI, Dysgranular insular cortex; DMD, Dorsomedial hypothalamic nucleus; DPGi, Dorsal paragigantocellular nucleus; DRD, Dorsal raphe nucleus, dorsal part; DRV, Dorsal raphe nucleus, ventral part; DRVL, Dorsal raphe nucleus, ventrolateral part; ECIC, External cortex of the inferior colliculus; ECu, External cuneate nucleus; FrA, Medial frontal cortex; Gi, Gigantocellular reticular nucleus; IC, Inferior colliculus; InG, Intermediate gray layer of the superior colliculus; IRt, Intermediate reticular nucleus; LaDL, Lateral amygdaloid nucleus, dorsolateral part; LaVL, Lateral amygdaloid nucleus, ventrolateral part; LaVM, Lateral amygdaloid nucleus, ventromedial part; LC, Locus ceruleus; LL, Lateral lemniscus; LGN, Lateral geniculate nucleus of thalamus; LH, Lateral hypothalamic area; LHb, Lateral habenular nucleus; LPBV, Lateral parabrachial nucleus, ventral part; M1, Primary motor cortex; MeV, Medial vestibular nucleus; MHb, Medial habenular nucleus; MPA, Medial preoptic area; MPB, Medial parabrachial nucleus; Op, Optic nerve layer of the superior colliculus; PAG, Periaqueductal gray; PaMP, Paraventricular hypothalamic nucleus, medial parvicellular part; PB, Parabrachial nucleus; PCRt, Parvicellular reticular nucleus; PLH, Peduncular part of lateral hypothalamus; PMn, Paramedian reticular nucleus; PnC, Pontine reticular nucleus, caudal part; PnR, Pontine raphe nucleus; PPN, Pedunculopontine nucleus; PPNd, Pedunculopontine nucleus, pars dissipata; PPNc, Pedunculopontine nucleus, pars compacta; PT, Pretectal nucleus; RVL, Rostroventrolateral reticular nucleus; S1BF, Primary somatosensory cortex, barrel field; S1DZ, Primary somatosensory cortex, dysgranular zone; S2, Secondary somatosensory cortex; SC, Superior colliculus; SN, Substantia nigra; Sp5, Spinal trigeminal nucleus; SpVe, Spinal vestibular nucleus; SSCx, Somatosensory cortex; TMN, Tuberomammillary nucleus of hypothalamus; TRN, Thalamic reticular nucleus; V1B, Primary visual cortex, binocular area; V2L, Secondary visual cortex, lateral area; VLL, Ventral nucleus of lateral lemniscus; VMH, Ventromedial hypothalamic nucleus; VPL, Ventral posterolateral nucleus of thalamus.

* Correspondence to: Safiye Çavdar, Koç University, School of Medicine, Department of Anatomy, 34450 Sarıyer, Istanbul, Turkey.
E-mail address: scavdar@ku.edu.tr (S. Çavdar).

https://doi.org/10.1016/j.neulet.2021.136308
Received 31 July 2021; Received in revised form 21 October 2021; Accepted 21 October 2021
Available online 29 October 2021
0304-3940/© 2021 Published by Elsevier B.V.

1. Introduction

The pedunculopontine nucleus (PPN) is located in the dorsal tegmentum of the midbrain and upper pons caudal to the red nucleus and dorsal to the substantia nigra. The PPN was first described by Jacobsohn in 1909, it was considered as a part of the reticular activating system. It came to attention after discovering its vast connections with the basal ganglia [1]. The PPN has been a popular part of the central nervous system (CNS) in the last years due to its involvement in some motor disorders [1,2] and after being identified as a surgical target for their treatment [3–5]

The human PPN has been subdivided into a pars dissipata (PPNd), present throughout the rostrocaudal extent of the nucleus, containing small and medium-sized cells, and a pars compacta (PPNc), located in the caudal half of the nucleus, containing densely arranged large cells [6]. The PPN is composed of cholinergic and noncholinergic (GABAergic and glutamatergic) neurons. The GABAergic neurons are predominantly located in the rostral portion, whereas the cholinergic and glutamatergic neurons are abundant in the caudal part of the PPN [7,8]. Experimental studies indicate that cholinergic PPN neurons are primarily involved in controlling thalamocortical excitability and behavioral state. In contrast, the noncholinergic PPN neurons are involved in motor functions.

Tract-tracing and electrophysiological studies in the rat, cat, and monkey showed reciprocal connections of the PPN with motor areas such as substantia nigra, motor areas of the cortex (primary, supplementary presupplementary dorsal and ventral premotor cortex and frontal eye fields), globus pallidus medialis, subthalamic nucleus and cerebellum [9,10]. Via these connections the motor functions of the PPN are well-known, however its involvement with non-motor functions is less relevant [11–13]. The present study aimed to show the non-motor connections of the PPN. The study has been designed in two parts; in the experimental part, we injected tracer Fluoro-Gold (FG) into the PPN of the rat and documented its non-motor connection. The motor connections of the PPN were shown using DTI in humans [14]. However, its non-motor connections were not identified. Thus, in the second part of the study using 3-tesla diffusion tensor imaging (DTI) tractography, we aimed to reveal the non-motor connections of the PPN in healthy adults.

2. Materials and methods

2.1. Animal study

A total of 12 male adult Wistar albino rats were used in the present study. Animals weighing 250–400 g were fed with a standard laboratory rat chow and tap water ad libitum and housed in Plexiglass cages with a 12–h light/dark cycle in a temperature-controlled room (20 ± 3 °C). The Ethical Committee of Koç University approved all procedures, which followed the New York Academy of Sciences' guidelines for the use of animals in research, testing, and education. Rats were anesthetized with ketamine (50 mg/kg, intraperitoneally) and xylazine (30 mg/kg, intraperitoneally). The heads of the animals were placed in a stereotaxic frame (Stoelting Model 51600, USA). The scalps were incised longitudinally, and the skulls were exposed between lambda and bregma. A small hole was drilled in the skull at a position appropriate for the unilateral injection of FG (n = 12) into the PPN. A Hamilton Syringe (Hamilton 80016, 32 ga, 2 in, point style 3) containing FG solution was lowered into PPN unilaterally, according to the rat brain atlas of Paxinos and Watson (2006) [15]. The coordinates were selected as follows: 7.8 mm posterior from bregma, 1.8 mm lateral to the midline, and 7.6 mm ventral to the surface of the skull.

2.2. Fluoro-Gold (FG) procedures

The FG solution (0.2 µl 2%, FluoroChrome Inc. Englewood, CO, USA) was pressure injected into PPN. After a 5–7 day survival period, animals were deeply anesthetized with ketamine (50 mg/kg, intraperitoneally) and xylazine (30 mg/kg, intraperitoneally) and perfused transcardially with 250–300 ml of heparinized saline solution, followed by 4 % paraformaldehyde in 0.1 M phosphate buffer (400–450 ml). Brains were removed and subsequently fixed in the same solution for 24 h at 4 °C. Coronal sections (40 µm) were cut using a cryostat (Leica). Every third section was placed on gelatin subbed glass slides, dehydrated, covered with anti-fade fluorescence mounting medium (ab104136, Abcam), and examined under a fluorescence microscope (Zeiss). Although 12 injections were made into the PPN, only 7 with correct injections with minimal contamination of the adjacent structures or along the pipette tract were included (Fig. 1a, b).

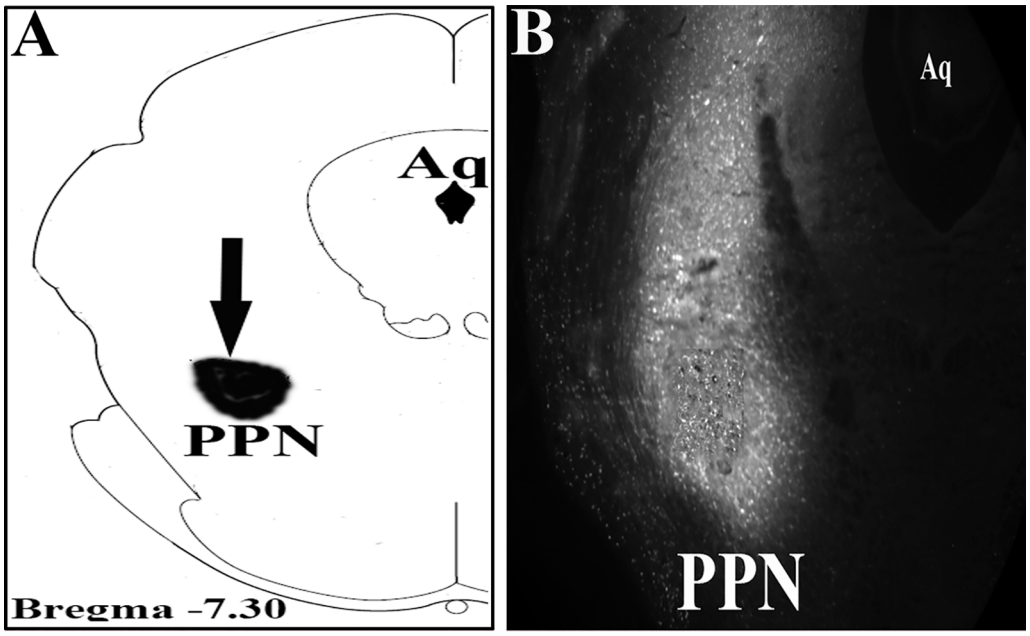

Fig. 1. A Schematic illustrations of injection sites of the PPN. **B** An example photograph of FG injection to the PPN. (PPN- pedunculopontine nucleus, Aq- cerebral aqueduct).

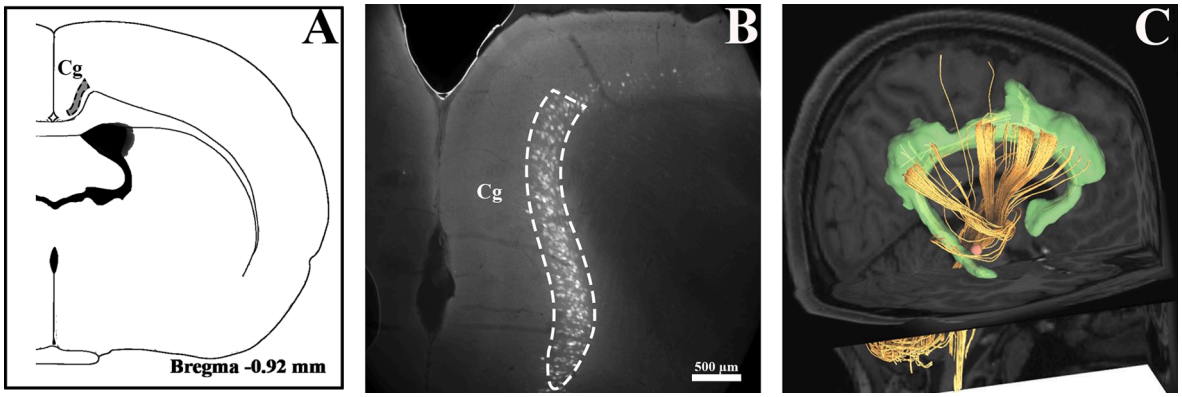

Fig. 2. **A**. Schematic illustration was added for orientation of the brain region where labelled cells of the cingulate cortex (Cg) was present. **B** Ipsilateral FG labelled cells in the cingulate cortex. **C** The DTI of bilateral PPN-Cg connections. (Cg- cingulate cortex).

2.2.1. Diffusion tensor imaging (DTI)

The Human Connectome Project (HCP) data of 35 healthy individuals (16 females-19 males, 20–59 years old, mean age: 31) from the MGH-USC consortium were included in this study. The data were obtained using a 3-tesla MRI System (Magnetom Skyra Siemens Healthcare, Erlangen, Germany) equipped with a 64-channel brain coil. During MRI data acquisition, subjects were positioned with the head in the supine position in the MRI scanner. A spin echo-EPI sequence was used while creating diffusion images. DTI data of each case consist of different b values (it varies as 1000, 3000, 5000, 10000 s/mm2). Each image in the data set was obtained in NIFTI format. The images used consisted of 96 sections and had a thickness of 1.5 mm and an isotropic voxel size of 1.5 mm. More information about shooting protocols, coils, and data is available on the connectome's own website (https://db.humanconnectome.org/). T1-weighted magnetization-prepared rapid-acquisition gradient-echo (MPRAGE) images were superimposed on the raw data in the data sets created, and the data were made ready for processing. Harvard Ascending Arousal Network Atlas (AAN) was used to show the tracts (https://www.nmr.mgh.harvard.edu/resources/aan-atlas). The MRIcroGL (Version, 2021, March) program was used for 3D visualization and rendering of nuclei and tracts (https://www.nitrc.org/projects/mricrogl). HCP 842, FreeSurfer, AAL2, and AAL3 atlases were used to show non-motor areas in the human brain (http://brain.labsolver.org/diffusion-mri-templates/hcp-842-hcp-1021, https://surfer.nmr.mgh.harvard.edu/fswiki/CorticalParcellation, http://www.gin.cnrs.fr). Synchronization was achieved by overlapping the previously parceled areas in the atlas with the images in the data. Seed points are drawn along the expected course of the white matter tracts of interest using the free-hand ROI method. Linked areas were identified through atlases (https://www.imaios.com)e-Anatomy). DSI Studio software was used to show the pathways revealed by data analysis and deterministic tractography method. Complete scanning protocols can be found in https://www.humanconnectome.org/storage/app/media/documentation/mgh_diffusion/MGH-Adult-Diffusion-Data-Scanning-Protocols-update.pdf.

3. Results

Subsequent to the placement of the FG tracer into the PPN, prominent connections with the motor (basal ganglia, substantia nigra, motor cortex, zona incerta, deep cerebellar nuclei, subthalamic, and red nucleus) and non-motor areas of the CNS were observed. The connections of the PPN with motor areas of the CNS were denser and dominant compared to its non-motor connections. In the present study, we have evaluated the connections of PPN with non-motor cortical, subcortical, and brainstem areas of the CNS.

3.1. The connections of the PPN with non-motor cortical areas

The distinct non-motor cortical connections of the PPN were with the cingulate (Cg1 and Cg2) (Fig. 2a–c), medial frontal (FrA), primary and secondary somatosensory (S1DZ, S1BF, S2) (Fig. 3a–c), insular (DI and

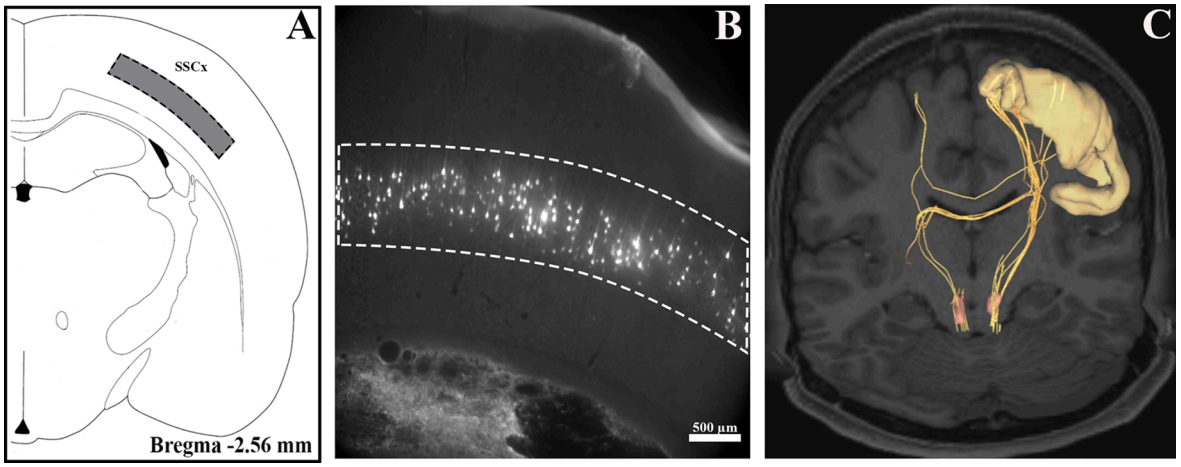

Fig. 3. **A** Schematic illustration was added for orientation of the brain region where labelled cells of the somatosensory cortex (SSCx) was present. **B** Ipsilateral FG labelled neurons in the layer V of the SSCx. **C** The DTI of bilateral PPN-SSCx connections. Note that few fibers crossed the midline at the level of the corpus callosum. (SSCx-somatosensory cortex).

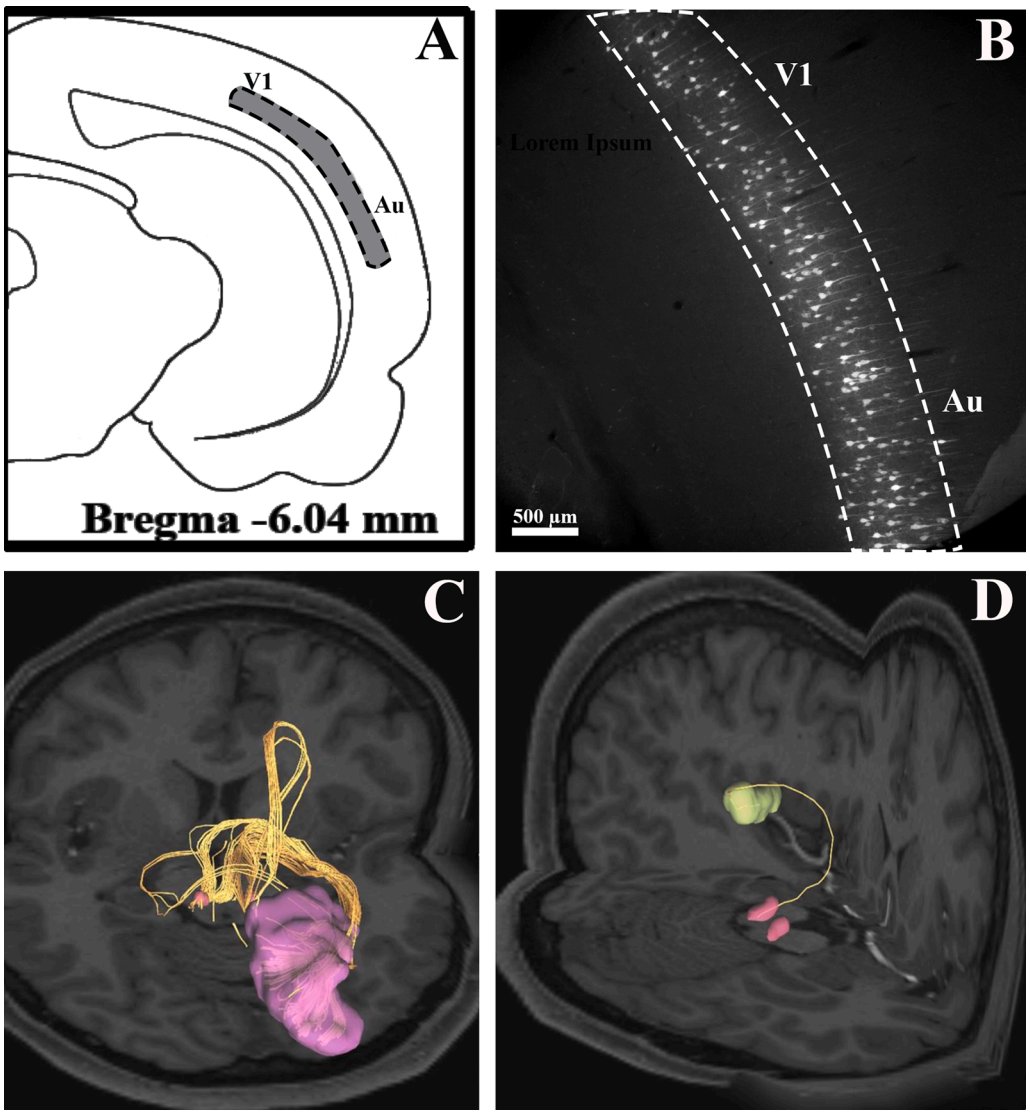

Fig. 4. A. Schematic illustration was added for orientation of the brain region where labelled cells of the visual (V1) and auditory (Au) cortex was present. **B** Ipsilateral FG labelled neurons in both visual and auditory cortices. **C** The DTI of ipsilateral and contralateral connections with the visual cortex. **D** Ipsilateral connection of the PPN with the auditory cortex was observed, while the contralateral connection was absent. (V1-primary visual cortex, Au-auditory cortex).

AIP), primary and secondary visual (V1B, V2L, VLL) (Fig. 4a–c) and primary auditory (AuD, Au1, and AuV) (Fig. 4a, b, and d) cortices. All cortical projections were ipsilateral. No contralateral cortical labeling was present. The labeled cells were localized in the internal pyramidal (layer V) layer of the cortex (Fig. 3b).

The intensity of non-motor PPN-cortical, subcortical and brainstem connections are stated in Table 1.

The DTI results in humans highly confirmed the cortical connections in the rat. However, in contrast to the ipsilateral PPN-cortical connections in rat, the DTI in humans showed bilateral PPN-cortical connections, dense with the ipsilateral, and scares with the contralateral cingulate, somatosensory and visual cortices (Figs. 2c, 3c, 4c). The DTI of PPN-auditory connections were ipsilateral similar to the FG results (Fig. 4d). The DTI of contralateral PPN-SSCx (somatosensory cortex) connections crossed the midline at the level of the corpus callosum (Fig. 3c).

3.2. The connections of the PPN with non-motor subcortical areas

Bilateral FG labeled cells were observed in the medial (MHb) and lateral (LHb) habenular nuclei localized on each side of the 3rd ventricle (Fig. 5a, b). The MHb and LHb labeling was predominant on the ipsilateral side (Fig. 5a, b). The non-motor ipsilateral thalamic nuclei connections of the PPN were with the ventral posterolateral (VPL), lateral geniculate (LGN), and rostral portion of thalamic reticular (TRN) nuclei. The PPN had distinct bilateral connections with the paraventricular (PaMP), ventromedial (VMH), dorsomedial (DMD) (Fig. 6a, b) and preoptic (MPA) hypothalamic nuclei. Further, diffused FG labeling was also observed at the lateral hypothalamic area (LH) and tuberomammillary nucleus (TMN). All hypothalamic nuclei labeling was dominant on the ipsilateral and scarce on the contralateral side. Further, ipsilateral labeling was observed with the central (CeM, CeL, and CeC), basal (BLA and BLP), and lateral (LaDL, LaVM, and LaVL) amygdala nuclei (Fig. 7a, b). Additionally, unilateral FG labeled cells were observed at the bed nucleus of stria terminalis (BNST).

Similar to the FG results, the DTI showed bilateral connections of the PPN with the habenular (Fig. 5c) and hypothalamic nuclei (Fig. 6c). In contrast to the FG results, the DTI showed bilateral connections with the amygdala (Fig. 7c).

Table 1
The density of ipsilateral and contralateral cortical, subcortical and brainstem connections of the PPN with non-motor areas of the CNS in the rat.

	Density of ipsilateral FG labelled neurons	Density of contralateral FG labelled neurons
Cortical		
• Somatosensory cortex (S1DZ, S1BF,S2)	+++	–
• Auditory cortex (AuD, Au1, AuV)	+++	–
• Visual cortex (V1B, V2L)	+++	–
• Cingulate cortex (Cg1, Cg2)	+++	–
• Medial frontal cortex (FrA)	++	–
• Insular cortex (DI, AIP)	++	–
Subcortical		
• Amygdala (LaDL, LaVM, LaVL, BLA, BLP, CeM, CeL, CeC)	++	–
• Hypothalamus (PaMP, VMH, DMD, PLH, LH MPA and TMN)	+++	++
• Habenular nucleus (MHb and LHb)	+++	++
• Thalamus (VPL, LGN and TRN)	+	–
• Bed nucleus of stria terminalis (BNST)	+	–
Brainstem		
Medulla Oblongata		
• Meullary reticular nuclei (Gi, DPGi, IRt, PCRt, PMn, RVL)	+++	+
• Trigeminal complex (Sp5)	++	+
• External cuneate nucleus (ECu)		
Pons		
• Pontine reticular nucleus (PnC, PnR)		
• Vestibular nuclei (SpVe, MeV)	+	+
Midbrain		
• Superior colliculus (Op, InG)	++	+
• Inferior colliculus (ECIC)	++	+
• Parabrachial nucleus (MPB, LPBV)	+	+
• Locus ceruleus (LC)	+	+
• Dorsal raphe nucleus (DRD, DRVL, DRV)	+++	+
• Pretectal nucleus (APT)	++	+
• Lateral Lemnical nucleus (VLL)	++	+
• Pedunculopontine nucleus (PPN)	+	+
• Periaqueductal gray (PAG)	++	+

Note: The density of ipsilateral and contralateral labeled cells was estimated as follows: + sparse: for the cell number 1–10, ++ moderate: for cell number 11–30, +++ dense: for the cell number 31 and above in a specific area.

3.3. The connections of the PPN with non-motor brainstem areas

Subsequent to FG injections to the PPN, labeled neurons were observed in various non-motor regions of the medulla oblongata, pons, and midbrain. In the medulla oblongata, the PPN was connected to the medullary reticular nuclei (Gi, DPGi, IRt, PCRt, PMn, and RVL), spinal nucleus of the trigeminal nerve (Sp5) (Fig. 8a–c) and external cuneate nucleus (ECu). In the pons, the PPN was connected to the pontine reticular nuclei (PnC, PnR) and vestibular nuclei (SpVe, MeV). In the midbrain, the PPN was connected to wide areas, including the locus coeruleus (LC), parabrachial nucleus (PB), superior (SC) (Fig. 9a–c) and inferior (IC) colliculus, dorsal raphe (DR) (Fig. 10a–c), lateral lemnical nucleus (LL), pretectal (PT) nuclei, periaquaductal gay (PAG) and contralateral PPN. All brainstem connections of the PPN were bilateral, dense on the ipsilateral and scarce on the contralateral side. Similar to the FG results, all DTI connections of the PPN with non-motor brainstem structures were bilateral, dense on the ipsilateral, and scarce on the contralateral side (Figs. 8c, 9c, and 10c).

4. Discussion

4.1. Major findings

The present tract-tracing study in the rat shows the connections of the PPN with wide non-motor cortical (cingulate, somatosensory, visual, auditory, and medial frontal), subcortical (amygdala, hypothalamus, thalamus, habenular and bed nucleus of stria terminalis), and brainstem structures. Extensive connections of the PPN with the medulla oblongata (medullary reticular and trigeminal spinal and external cuneate nuclei), pons (pontine reticular and vestibular nuclei), and midbrain (SC, IC, LC, PAG, PB, DR, LL, PT, and PPN) were observed. The non-motor connections of the PPN in rats were confirmed using DTI obtained from healthy human adults.

Tract-tracing and evoked-potential studies in rodents and primates reported different connections of the PPN among species [16]. Aravamuthan et al. 2009 reported four main differences in the connection of the PPN between rats and monkeys using probabilistic diffusion tractography [17]. The different connections were between PPN-M1 (primary motor cortex), PPN-SN (substantia nigra), PPN-deep cerebellar nuclei, and PPN-cortical connections. They concluded that the difference in the connection of the PPN in humans and monkeys might be due to the changing role of the PPN in maintaining bipedal as opposed to quadrupedal gait. They did not report any difference regarding the non-motor connections of the PPN between the two species. The results of the present DTI study in humans highly corresponded to the non-motor PPN connections observed in rats. The major difference was that the cortical connections in rats were unilateral, however, in humans these connections were bilateral which may be related to the complex neuronal network in humans.

The wide non-motor cortical, subcortical, and brainstem connections of the PPN provide evidence for its integrating role. Experimental and clinical studies showed the involvement of the PPN in an extensive variety of non-motor functions such as cortical arousal, behavioral state, sleep-wake cycle, attention, reward and learning, verbal fluency, and

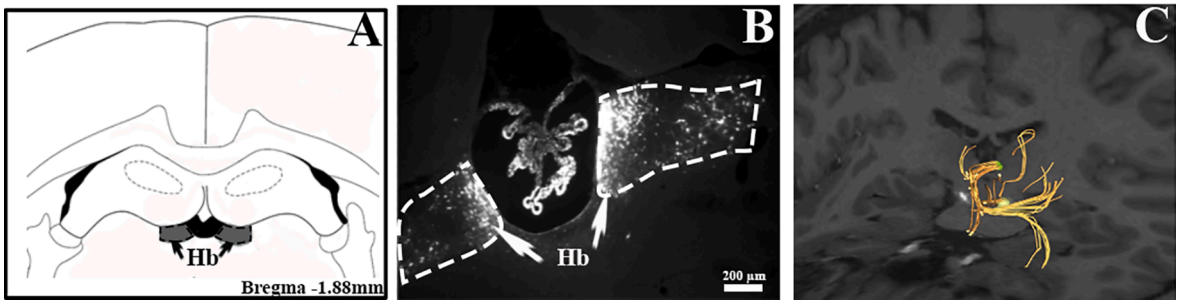

Fig. 5. **A** Schematic illustration was added for orientation of the brain region where labelled cells of the habunular nucleus (Hb) was present. **B** Bilateral FG labelled cells were observed in in the Hb nucleus, dense on the ipsilateral scarce on the contralateral side. **C** The DTI image showed bilateral connections of the PPN with the left Hb nucleus. (Hb-habenular nucleus).

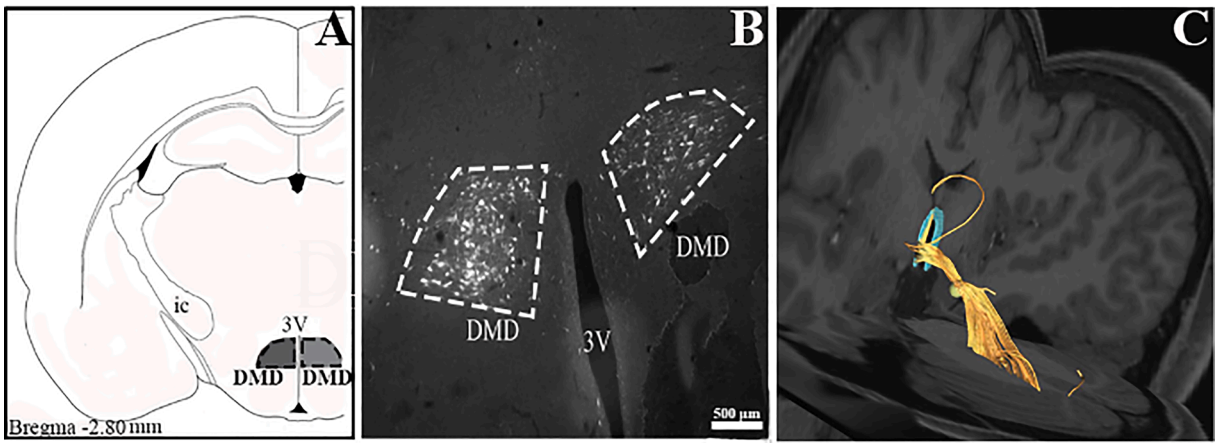

Fig. 6. **A** Schematic illustration was added for orientation of the brain region where labelled cells of the dorsomedial hypothalamic nucleus (DMD) was present. **B** Bilateral FG labelled neurons were observed in dorsomedial hypothalamic nucleus. **C** A DTI image of ipsilateral and contralateral connections of the PPN with the hypothalamus. (DMD- dorsomedial hypothalamic nucleus, 3V-3rd ventricle).

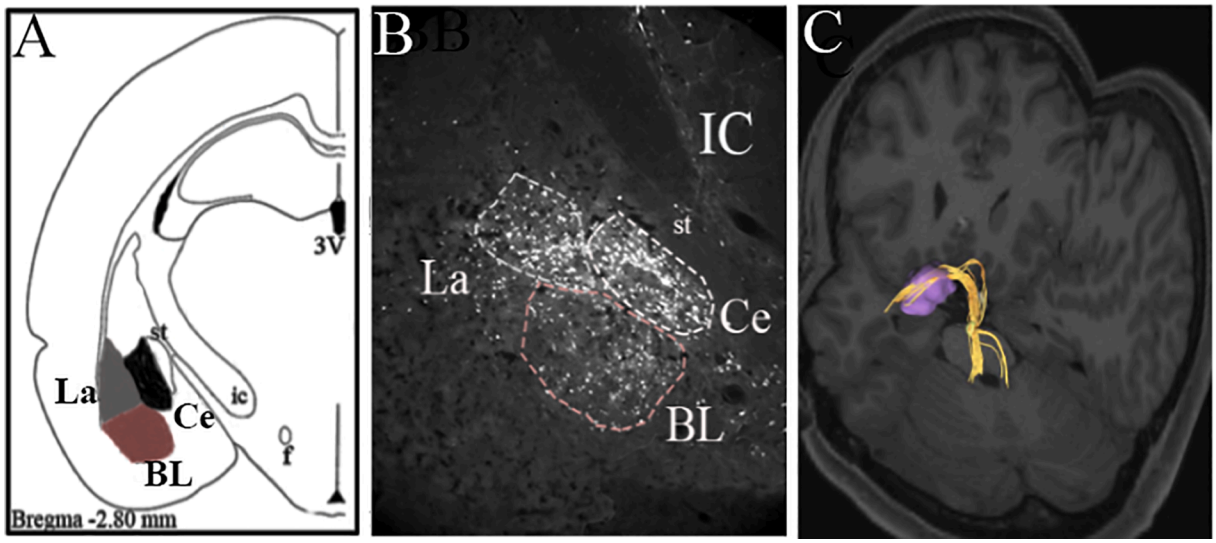

Fig. 7. **A** Schematic illustration was added for orientation of the brain region where labelled cells of the amygdala nuclei (La, Ce and BL) was present. **B** Ipsilateral FG labelled neurons were observed in amygdala nuclei. **C** A bilateral DTI image showing the PPN-amygdala connections, the majority of the connections were ipsilateral. (La-lateral, BL-basolateral, Ce-central amygdala nuclei, ic-internal capsule, st-stria terminalis).

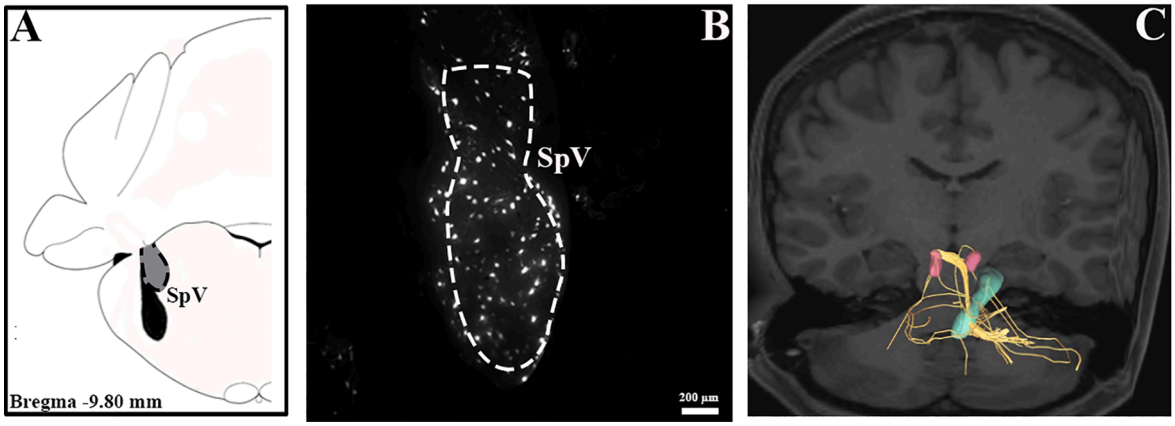

Fig. 8. **A**. Schematic illustration was added for orientation of the brain region where labelled cells of the spinal nucleus of the trigeminal nerve (Sp5) was present. **B** Bilateral FG labelled neurons were observed in the Sp5, dense on the ipsilateral and sparse on the contralateral side. **C** The DTI image showed ipsilateral and contralateral connections of the PPN with the trigeminal complex. Note that the contralateral connections were denser than its ipsilateral connections. (Sp5- spinal nucleus of the trigeminal nerve).

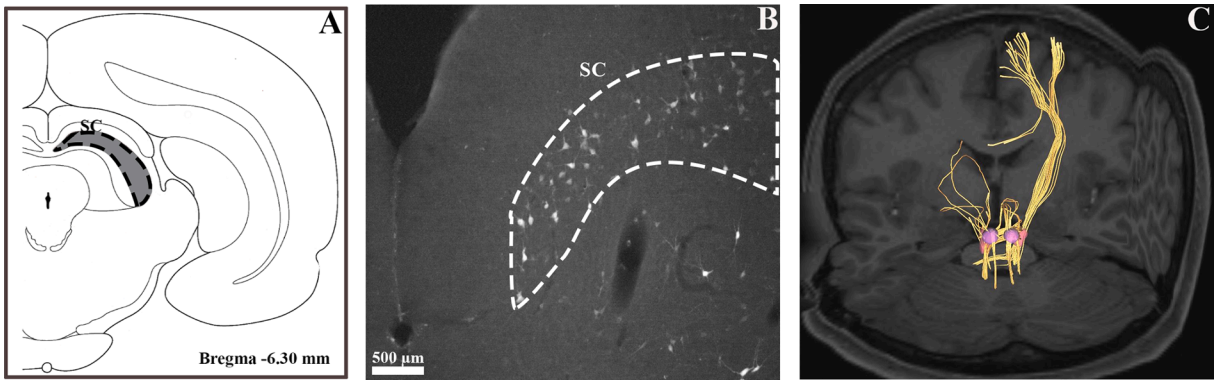

Fig. 9. **A** Schematic illustration was added for orientation of the brain region where labelled cells of the SC was present. **B** Bilateral FG labelled neurons were observed in the SC, dense on the ipsilateral and sparse on the contralateral side. **C** The DTI image showed ipsilateral and contralateral connections of the PPN with the SC. (SC-superior colliculus).

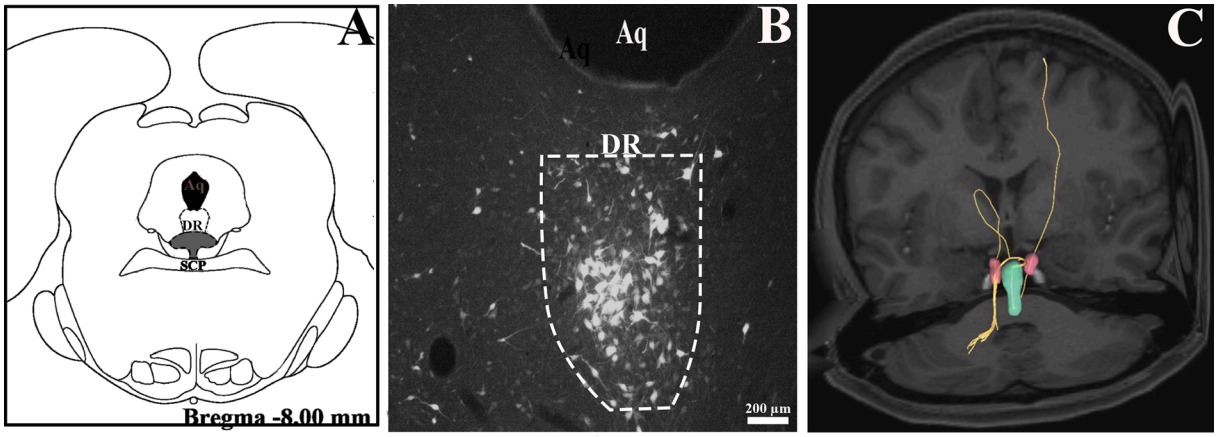

Fig. 10. **A** Schematic illustration was added for orientation of the brain region where labelled cells of the DR was present. **B** Bilateral labelled neurons were observed in the DR nuclei, dense on the ipsilateral and sparse on the contralateral side. **C** The DTI image showed bilateral connections of the PPN with the DR nuclei. (DR-dorsal raphe nucleus, SCP-superior cerebellar peduncle).

cognition (Table 2).

The development of deep brain stimulation (DBS) for the treatment of PD has provided some insight into the function of the PPN in humans [18–20]. Impairment or improvement in non-motor functions (sleep, respiratory, cardiovascular, learning, working memory, executive and cognitive) were displayed by PD patients after the application of the DBS to the PPN [21–24]. The non-motor connections of the PPN with the hypothalamus, amygdala, and brainstem reticular nuclei can be responsible for the improvement/impairment observed in PD patients subsequent to DBS. The direct connections of the PPN with the medial frontal cortical areas of the brain observed in the rat, and studies of the human brain may indicate its involvement with executive functions.

Extensive studies have reported the important role of the PPN in the control of sleep [25,26]. Bilateral lesions of the PPN demonstrated the dysfunction of paradoxical sleep [25]. Sleep involves networks of neuronal populations within the CNS that control movement, arousal, autonomic functions, behavior, and cognition. The connections of the PPN with wake-promoting areas such as the LC, DR and hypothalamus may indicate a modulatory role of PPN in sleep generation. Thus, the sleep disturbance that occurs after PPN stimulation may be related to the dysfunction of these connections. Further, the connections of the PPN with the TRN may also contribute to sleep control. It has been shown that cholinergic fibers from the PPN reach the TRN. The present study confirmed the PPN-rostral TRN connections. The TRN plays an important role in modulating the flow of information through the thalamus and in generating changes in thalamic activity during transitions from wakefulness to sleep. The TRN is composed of GABAergic neurons, and these neurons have an inhibitory effect on the thalamic relay neurons and prevent the information flow to cortical levels, as in sleep state. The PPN-TRN connections may have a modulating role in the sleep circuit.

The amygdala is a specialized region of the brain for processing emotion. Emotion influences cognitive processes including learning and memory [27]. A defect in the cholinergic flow from the PPN to the amygdala severely affects emotional memory, showing that the cholinergic system and amygdala are essential for learning and memory [28,29]. Aitta-Aho et al. [30] demonstrated that cholinergic projections to distinct amygdala nuclei can differentially impact amygdala circuits and behavior. In the present study, in addition to the basolateral amygdala connections, we also found PPN connections with the central and lateral amygdala and confirmed the presence of PPN-amygdala connections in healthy adults using DTI. Although the PPN-amygdala connection has been cited in the literature, the impact of these connections has not been thoroughly explained. Further extensive studies are necessary to reveal the functions of the PPN-amygdala connections.

The PPN is also connected to hypothalamic nuclei involved in the regulation of behavioral states and autonomic functions [31]. An experimental study showed that the cholinergic fibers from the PPN controls renal sympathetic nerve activity and cardiorespiratory activities [32]. Thus, the extensive PPN-hypothalamic nuclei connections underpin the fact that the PPN is also involved in autonomic functions.

The PPN was intensely connected to non-motor structures of the brainstem, in particular with the medullary and pontine reticular nuclei,

Table 2
Studies in literature showing the relations of the PPN with non-motor functions.

Authors	Research type	Research material	Function
Dellu et al., 1991 [37]	PPN lesion	Spraque-Dawley rats	Impaired learning
Fujimoto et al., 1992 [38]	PPN lesion	Wistar rats	Impaired acquisition, preserved retention and retrieval of avoidance behavior
Lim et al., 2009 [39]	PPN-DBS	PD patients	Increased time and percentage of REM sleep
Wilson et al., 2009 [40]	PPN lesion	Lister Hooded rats	Impaired learning and/or motivation
Alessandro et al., 2010 [21]	PPN-DBS	PD patients	Improvement in delayed recall and verbal fluency
Ceravolo et al., 2011 [23]	PPN-DBS	PD patients	Improvement in delayed recall and executive functions
Luo et al., 2011 [41]	PPN stimulation using paired acoustic	Mice	Induction of the frequency-specific plasticity
Norton et al., 2011 [42]	PPN recording	Long Evans rats	Reward, sensory-motor gating, learning
Schofield et al., 2011 [43]	Tract-tracing	Guinea pig	Habituation and novelty detection, arousal and attention, sensory gating in acute startle reflex, reward
MacLaren et al., 2013 [31]	PPN inactivation	Lister Hooded rats	Impairment of action-outcome associative learning
Okada and Kobayashi, 2013 [44]	PPN recording	Macaque monkey	Reward processing and motivational control
Cyr et al., 2014 [45]	PPN lesion	Long Evans rats	Impairment in attention
Van Dort et al., 2015 [46]	PPN activation	Mice	REM sleep induction, increase REM sleep episodes
Thompson et al., 2016 [47]	PPN recording	Mice	Influence decision making
Syed et al., 2016 [48]	PPN lesion	Long Evans rats	Impaired probabilistic reversal learning
Mazzone et al., 2019[49]	PPN stimulation	PD patients	Wake involvement
Kumar Yadav and Mallick, 2021 [50]	PPN stimulation	Wistar rats	Regulate REM

LC, SC, IC, Sp5, PB, DR, PT, and LL. The results of the present study confirms former studies related to the connections of the PPN with auditory (Au1, IC, and LL), and visual (LGN, SC, V1 and V2) structures of the CNS [39–41], indicates that PPN may have a role in many aspects of the auditory and visual processing in both cortical and brainstem levels.

The results of the present study showed that the right and left PPN is connected to each other in humans which may contribute to explain the positive effects of unilateral PPN DBS in Parkinsonian patients avoiding a bilateral surgery. The present study showed connections of the PPN with vestibular nuclei. This finding was confirmed by a clinical study on PD patients who underwent PPN stimulation resulting in improved balance function [35]. The present tract-tracing study in rats and DTI study in healthy humans provides evidence for the PPN-Sp5 connections. Timofeeva et al. 2005 speculated the function of PPN-Sp5 connections in the rat as "gathering information through whisker" [36]. However, the impact of PPN-Sp5 in humans is unknown.

Declaration of Competing Interest

The authors declare that they have no known competing financial interests or personal relationships that could have appeared to influence the work reported in this paper.

Acknowledgements

The authors would like to thank Koç University Research Center for Translational Medicine (KUTTAM) for using the facilities.

Ethical approval

All procedures performed in the study were approved by the ethical standards of the institutional Committee of Koç University.

Funding Sources

This research did not receive any specific grant from funding agencies in public, commercial, or not-for-profit sectors.

References

[1] W.J.H. Nauta, W.R. Mehler, Projections of the lentiform nucleus in the monkey, Brain Res. 1 (1) (1966) 3–42, https://doi.org/10.1016/0006-8993(66)90103-X.
[2] S. Moonedley, A.M. Graybiel, Connections of the nucleus tegmenti pedunculopontinis, pars compacta (TPc) in cat, in: Anat. Rec., WILEY-LISS DIV JOHN WILEY & SONS INC, 605 THIRD AVE, NEW YORK, NY 10158-0012, 1980: pp. A129–A129.
[3] P. Mazzone, O. Vilela Filho, F. Viselli, A. Insola, S. Sposato, F. Vitale, E. Scarnati, Our first decade of experience in deep brain stimulation of the brainstem: elucidating the mechanism of action of stimulation of the ventrolateral pontine tegmentum, J. Neural Transm. 123 (7) (2016) 751–767, https://doi.org/10.1007/s00702-016-1518-5.
[4] C. Karachi, D. Grabli, F.A. Bernard, D. Tandé, N. Wattiez, H. Belaid, E. Bardinet, A. Prigent, H.-P. Nothacker, S. Hunot, A. Hartmann, S. Lehéricy, E.C. Hirsch, C. François, Cholinergic mesencephalic neurons are involved in gait and postural disorders in Parkinson disease, J. Clin. Invest. 120 (8) (2010) 2745–2754, https://doi.org/10.1172/JCI4264210.1172/JCI42642DS1.
[5] E.C. Hirsch, A.M. Graybiel, C. Duyckaerts, F. Javoy-Agid, Neuronal loss in the pedunculopontine tegmental nucleus in Parkinson disease and in progressive supranuclear palsy, Proc. Natl. Acad. Sci. U. S. A. 84 (16) (1987) 5976–5980, https://doi.org/10.1073/pnas.84.16.5976.
[6] M.-M. Mesulam, C. Geula, M.A. Bothwell, L.B. Hersh, Human reticular formation: cholinergic neurons of the pedunculopontine and laterodorsal tegmental nuclei and some cytochemical comparisons to forebrain cholinergic neurons, J. Comp. Neurol. 283 (4) (1989) 611–633, https://doi.org/10.1002/cne.902830414.
[7] P. Winn, Experimental studies of pedunculopontine functions: are they motor, sensory or integrative? Parkinsonism Relat. Disord. 14 (Suppl 2) (2008) S194–8, https://doi.org/10.1016/j.parkreldis.2008.04.030.
[8] C. Martinez-Gonzalez, J.P. Bolam, J. Mena-Segovia, Topographical organization of the pedunculopontine nucleus, Front. Neuroanat. 5 (2011) 22.
[9] C.B. Saper, A.D. Loewy, Projections of the pedunculopontine tegmental nucleus in the rat: evidence for additional extrapyramidal circuitry, Brain Res. 252 (2) (1982) 367–372, https://doi.org/10.1016/0006-8993(82)90404-8.
[10] B. Lavoie, A. Parent, Pedunculopontine nucleus in the squirrel monkey: projections to the basal ganglia as revealed by anterograde tract-tracing methods, J. Comp. Neurol. 344 (2) (1994) 210–231, https://doi.org/10.1002/cne.903440204.
[11] K. Takakusaki, T. Shiroyama, S.T. Kitai, Two types of cholinergic neurons in the rat tegmental pedunculopontine nucleus: electrophysiological and morphological characterization, Neuroscience 79 (1997) 1089–1109.
[12] K.P. Grace, H. Liu, R.L. Horner, 5-HT1A receptor-responsive pedunculopontine tegmental neurons suppress REM sleep and respiratory motor activity, J. Neurosci. 32 (5) (2012) 1622–1633.
[13] M. Ye, A. Hayar, B. Strotman, E. Garcia-Rill, Cholinergic modulation of fast inhibitory and excitatory transmission to pedunculopontine thalamic projecting neurons, J. Neurophysiol. 103 (5) (2010) 2417–2432.
[14] K.A. Muthusamy, B.R. Aravamuthan, M.L. Kringelbach, N. Jenkinson, N.L. Voets, H. Johansen-Berg, J.F. Stein, T.Z. Aziz, Connectivity of the human pedunculopontine nucleus region and diffusion tensor imaging in surgical targeting, J. Neurosurg. 107 (4) (2007) 814–820.
[15] G. Paxinos, C. Watson, The rat brain in stereotaxic coordinates: hard cover edition, Elsevier, 2006.
[16] B.M. Spann, I. Grofova, Cholinergic and non-cholinergic neurons in the rat pedunculopontine tegmental nucleus, Anat. Embryol. (Berl) 186 (1992) 215–227, https://doi.org/10.1007/BF00174143.
[17] B.R. Aravamuthan, J.A. McNab, K.L. Miller, M. Rushworth, N. Jenkinson, J. F. Stein, T.Z. Aziz, Cortical and subcortical connections within the pedunculopontine nucleus of the primate Macaca mulatta determined using probabilistic diffusion tractography, J. Clin. Neurosci. 16 (3) (2009) 413–420.
[18] C. Karachi, A. André, E. Bertasi, E. Bardinet, S. Lehéricy, F.A. Bernard, Functional Parcellation of the Lateral Mesencephalus, J. Neurosci. 32 (2012) 9396 LP – 9401. https://doi.org/10.1523/JNEUROSCI.0509-12.2012.
[19] V. Caggiano, R. Leiras, H. Goñi-Erro, D. Masini, C. Bellardita, J. Bouvier, V. Caldeira, G. Fisone, O. Kiehn, Midbrain circuits that set locomotor speed and gait selection, Nature 553 (7689) (2018) 455–460, https://doi.org/10.1038/nature25448.

[20] T.L. Tattersall, P.G. Stratton, T.J. Coyne, R. Cook, P. Silberstein, P.A. Silburn, F. Windels, P. Sah, Imagined gait modulates neuronal network dynamics in the human pedunculopontine nucleus, Nat. Neurosci. 17 (3) (2014) 449–454, https://doi.org/10.1038/nn.3642.
[21] S. Alessandro, R. Ceravolo, L. Brusa, M. Pierantozzi, A. Costa, S. Galati, F. Placidi, A. Romigi, C. Iani, F. Marzetti, Non-motor functions in parkinsonian patients implanted in the pedunculopontine nucleus: focus on sleep and cognitive domains, J. Neurol. Sci. 289 (2010) 44–48.
[22] J.A. Hyam, S. Wang, H. Roy, S.H. Moosavi, S.C. Martin, J.S. Brittain, T. Coyne, P. Silburn, T.Z. Aziz, A.L. Green, The pedunculopontine region and breathing in Parkinson's disease, Ann. Clin. Transl. Neurol. 6 (5) (2019) 837–847.
[23] R. Ceravolo, L. Brusa, S. Galati, D. Volterrani, A. Peppe, G. Siciliano, M. Pierantozzi, V. Moschella, U. Bonuccelli, P. Stanzione, Low frequency stimulation of the nucleus tegmenti pedunculopontini increases cortical metabolism in parkinsonian patients, Eur. J. Neurol. 18 (2011) 842–849.
[24] A. Costa, G.A. Carlesimo, C. Caltagirone, P. Mazzone, M. Pierantozzi, A. Stefani, A. Peppe, Effects of deep brain stimulation of the peduncolopontine area on working memory tasks in patients with Parkinson's disease, Parkinsonism Relat. Disord. 16 (1) (2010) 64–67, https://doi.org/10.1016/j.parkreldis.2009.05.009.
[25] S. Deurveilher, E. Hennevin, Lesions of the pedunculopontine tegmental nucleus reduce paradoxical sleep (PS) propensity: evidence from a short-term PS deprivation study in rats, Eur. J. Neurosci. 13 (10) (2001) 1963–1976, https://doi.org/10.1046/j.0953-816x.2001.01562.x.
[26] A.M. Fink, C. Dean, M.R. Piano, D.W. Carley, The pedunculopontine tegmentum controls renal sympathetic nerve activity and cardiorespiratory activities in nembutal-anesthetized rats, PLoS One. 12 (2017). https://doi.org/10.1371/journal.pone.0187956.
[27] Y. Yang, J.-Z. Wang, From structure to behavior in basolateral amygdala-hippocampus circuits, Front. Neural Circuits. 11 (2017) 86.
[28] M.E. Hasselmo, The role of acetylcholine in learning and memory, Curr. Opin. Neurobiol. 16 (6) (2006) 710–715.
[29] P.M. Callahan, A.V. Terry, M.C. Peitsch, J. Hoeng, K. Koshibu, Differential effects of alkaloids on memory in rodents, Sci. Rep. 11 (2021) 1–9.
[30] T. Aitta-aho, Y.A. Hay, B.U. Phillips, L.M. Saksida, T.J. Bussey, O. Paulsen, J. Apergis-Schoute, Basal forebrain and brainstem cholinergic neurons differentially impact amygdala circuits and learning-related behavior, Curr. Biol. 28 (16) (2018) 2557–2569.e4.
[31] D.A.A. MacLaren, J.A. Santini, A.L. Russell, T. Markovic, S.D. Clark, Deficits in motor performance after pedunculopontine lesions in rats–impairment depends on demands of task, Eur. J. Neurosci. 40 (8) (2014) 3224–3236.
[32] L. Bayer, P.Y. Risold, B. Griffond, D. Fellmann, Rat diencephalic neurons producing melanin-concentrating hormone are influenced by ascending cholinergic projections, Neuroscience. 91 (3) (1999) 1087–1101.
[35] N. Yousif, H. Bhatt, P.G. Bain, D. Nandi, B.M. Seemungal, The effect of pedunculopontine nucleus deep brain stimulation on postural sway and vestibular perception, Eur. J. Neurol. 23 (3) (2016) 668–670.
[36] E. Timofeeva, C. Dufresne, A. Sík, Z.-W. Zhang, M. Deschênes, Cholinergic modulation of vibrissal receptive fields in trigeminal nuclei, J. Neurosci. 25 (2005) 9135–9143.
[37] F. Dellu, W. Mayo, J. Cherkaoui, M. Le Moal, H. Simon, Learning disturbances following excitotoxic lesion of cholinergic pedunculo-pontine nucleus in the rat, Brain Res. 544 (1) (1991) 126–132.
[38] K.-I. Fujimoto, K. Ikeguchi, M. Yoshida, Impaired acquisition, preserved retention and retrieval of avoidance behavior after destruction of pedunculopontine nucleus areas in the rat, Neurosci. Res. 13 (1) (1992) 43–51, https://doi.org/10.1016/0168-0102(92)90033-9.
[39] A.S. Lim, E. Moro, A.M. Lozano, C. Hamani, J.O. Dostrovsky, W.D. Hutchison, A. E. Lang, R.A. Wennberg, B.J. Murray, Selective enhancement of rapid eye movement sleep by deep brain stimulation of the human pons, Ann. Neurol. Off. J. Am. Neurol. Assoc. Child Neurol. Soc. 66 (2009) 110–114.
[40] D.I.G. Wilson, D.A.A. MacLaren, P. Winn, On the relationships between the pedunculopontine tegmental nucleus, corticostriatal architecture, and the medial reticular formation, in: Basal Ganglia IX, Springer, 2009, pp. 143–157.
[41] F. Luo, X. Liu, C. Wang, J. Yan, The pedunculopontine tegmental nucleus: a second cholinergic source for frequency-specific auditory plasticity, J. Neurophysiol. 105 (1) (2011) 107–116, https://doi.org/10.1152/jn.00546.2010.
[42] A.B.W. Norton, Y.S. Jo, E.W. Clark, C.A. Taylor, S.J.Y. Mizumori, Independent neural coding of reward and movement by pedunculopontine tegmental nucleus neurons in freely navigating rats, Eur. J. Neurosci. 33 (2011) 1885–1896.
[43] B.R. Schofield, S.D. Motts, J.G. Mellott, Cholinergic cells of the pontomesencephalic tegmentum: connections with auditory structures from cochlear nucleus to cortex, Hear. Res. 279 (1-2) (2011) 85–95, https://doi.org/10.1016/j.heares.2010.12.019.
[44] K. Okada, Y. Kobayashi, Reward prediction-related increases and decreases in tonic neuronal activity of the pedunculopontine tegmental nucleus, Front. Integr. Neurosci. 7 (2013) 36.
[45] M. Cyr, M.J. Parent, N. Mechawar, P. Rosa-Neto, J.-P. Soucy, S.D. Clark, M. Aghourian, M.-A. Bedard, Deficit in sustained attention following selective cholinergic lesion of the pedunculopontine tegmental nucleus in rat, as measured with both post-mortem immunocytochemistry and in vivo PET imaging with [^{18}F] fluoroethoxybenzovesamicol, Behav. Brain Res. 278 (2015) 107–114, https://doi.org/10.1016/j.bbr.2014.09.021.
[46] C.J. Van Dort, D.P. Zachs, J.D. Kenny, S. Zheng, R.R. Goldblum, N.A. Gelwan, D. M. Ramos, M.A. Nolan, K. Wang, F.-J. Weng, Y. Lin, M.A. Wilson, E.N. Brown, Optogenetic activation of cholinergic neurons in the PPT or LDT induces REM sleep, Proc. Natl. Acad. Sci. 112 (2) (2015) 584–589.
[47] J.A. Thompson, J.D. Costabile, G. Felsen, Mesencephalic representations of recent experience influence decision making, Elife. 5 (2016) e16572. https://doi.org/10.7554/eLife.16572.
[48] A. Syed, P.M. Baker, M.E. Ragozzino, Pedunculopontine tegmental nucleus lesions impair probabilistic reversal learning by reducing sensitivity to positive reward feedback, Neurobiol. Learn. Mem. 131 (2016) 1–8, https://doi.org/10.1016/j.nlm.2016.03.010.
[49] P. Mazzone, G. Della Marca, E. Scarnati, Deep brain stimulation of the pedunculopontine tegmental nucleus and arousal in Parkinson's disease, in, Arousal Neurol. Psychiatr. Dis., Elsevier (2019) 143–159.
[50] R. Kumar Yadav, B.N. Mallick, Dopaminergic-and cholinergic-inputs from substantia nigra and pedunculo-pontine tegmentum, respectively, converge in amygdala to modulate rapid eye movement sleep in rats, Neuropharmacology 193 (2021) 108607, https://doi.org/10.1016/j.neuropharm.2021.108607.