Interactive CardioVascular and Thoracic Surgery 26 (2018) 112–118
doi:10.1093/icvts/ivx259 Advance Access publication 16 August 2017

ORIGINAL ARTICLE

Cite this article as: Cakici M, Gumus F, Ozcinar E, Baran C, Bermede O, Inan MB *et al.* Controlled flow diversion in hybrid venoarterial–venous extracorporeal membrane oxygenation. Interact CardioVasc Thorac Surg 2018;26:112–8.

Controlled flow diversion in hybrid venoarterial–venous extracorporeal membrane oxygenation

Mehmet Cakici[a], Fatih Gumus[a], Evren Ozcinar[a], Cagdas Baran[a], Onat Bermede[b], Mustafa Bahadır Inan[a], Mustafa Serkan Durdu[a], Mustafa Sirlak[a] and Ahmet Ruchan Akar[a,*]

[a] Department of Cardiovascular Surgery, Heart Center, Cebeci Hospitals, Ankara University School of Medicine, Ankara, Turkey
[b] Department of Anesthesiology, Cebeci Hospitals, Ankara University School of Medicine, Ankara, Turkey

* Corresponding author. Department of Cardiovascular Surgery, Heart Center, Cebeci Hospitals, Ankara University School of Medicine, Dikimevi, Ankara 06340 Turkey. Tel: +90-533-6460684; fax: +90-312-3625639; e-mail: akarruchan@gmail.com (A.R. Akar).

Received 28 April 2017; received in revised form 28 June 2017; accepted 9 July 2017

Abstract

OBJECTIVES: Patients on venoarterial or venovenous extracorporeal membrane oxygenation (ECMO) support may require venoarterial–venous (VAV-ECMO) configuration during follow-up. We report 12 cases of VAV-ECMO with significant outflow steal.

METHODS: Between October 2014 and November 2016, a total of 97 patients (56.6 ± 12.0 years; 59 men/38 women; body surface area 1.84 ± 0.36 m^2) were supported with venoarterial ECMO ($n = 85$) or venovenous ECMO ($n = 12$). Among the 97 patients, 12 patients (age 61.5 ± 3.5 years; 8 men/4 women; body surface area 1.8 ± 0.8 m^2) required hybrid use of VAV-ECMO. Control and monitoring of flow ratios in supplying cannulae using flow sensors were performed, and occluder devices were used according to patient requirements to achieve optimum haemodynamics and oxygenation.

RESULTS: Among the 85 venoarterial ECMO-supported patients, Harlequin syndrome was detected in 9 cases (10.6%) who required switching to VAV-ECMO. Among the 12 patients, 3 (25%) patients required VAV-ECMO while on venovenous ECMO support as a result of initial respiratory failure subsequently developed cardiac decompensation. Mean duration of VAV-ECMO support was 6.4 ± 1.8 days. Overall, on VAV-ECMO support, 70.0 ± 4.6% of blood flow was detected within the supplying right internal jugular vein cannula as a result of lower afterload in venous system. We partially occluded the internal jugular vein cannula and directed flow to the common femoral artery. After adjustment, 34.3 ± 7.4% flow was directed to internal jugular vein and 65.6 ± 7.4% to common femoral artery.

CONCLUSIONS: Non-invasive monitoring of flow rates within the supplying cannulae of VAV-ECMO and the use of partial occlusion for venous-supplying cannula enable individualized patient management and effective weaning from VAV-ECMO.

Keywords: Heart failure • Cardiogenic shock • Extracorporeal membrane oxygenation • Assisted circulation

INTRODUCTION

Extracorporeal membrane oxygenation (ECMO) has been increasingly used in acute cardiopulmonary failure in critically ill patients [1, 2]. Venoarterial ECMO (VA-ECMO) is currently an advanced rescue treatment modality for refractory cardiogenic shock [3, 4]. Venovenous ECMO (VV-ECMO) provides partial or complete support for oxygenation and respiratory function using dual or single cannulation technique for patients with respiratory failure. However, patients treated initially with VV-ECMO may subsequently develop cardiac decompensation and patients receiving VA-ECMO support may develop profound upper body differential hypoxaemia defined as Harlequin syndrome [1]. Differential hypoxaemia results in coronary and cerebral hypoperfusion and hypoxaemia compared with lower body perfusion, which may lead to neurological complications, progressive left ventricular dysfunction and ineffective ECMO support. Several solutions were described including ventilator adjustments, changing cannula configuration [5], increasing ECMO flows [6], switching the arterial cannula to axillary artery [7], central cannulation or using hybrid systems in venovenous–arterial or veno-arterial–venous (VAV) configurations with triple cannulation strategy [8–11].

To have a universal nomenclature, Napp *et al.* [12] proposed a nomenclature that uses 'A' and all following letters for supplying cannulae and all letters before 'A' for draining cannulae. In demand of switching to VAV-ECMO, internal jugular vein (IJV) cannulation is the most preferred access as a supplying target for patients with differential hypoxaemia to provide optimal oxygen delivery to cerebral and coronary circulations. However, because of differential afterload conditions of right IJV and common femoral artery (CFA) as supplying targets, significant flow diversion may develop towards the IJV cannula. We identified 12 patients who required switching to VAV-ECMO support. To determine

© The Author 2017. Published by Oxford University Press on behalf of the European Association for Cardio-Thoracic Surgery. All rights reserved.

Downloaded from https://academic.oup.com/icvts/article/26/1/112/4083519 by ANKARA user on 12 December 2021

the flow characteristics within arterial- and venous-supplying cannulae, we carried out the study on flow monitoring within supplying cannulae using flow sensors. Uncontrolled flow diversion towards venous-supplying cannula was detected in all cases and subsequently corrected by an occluder device. The present report examines the management of differential hypoxaemia and flow characteristics on VAV-ECMO support.

METHODS

Study population

We retrospectively evaluated a total of 97 patients (59 men and 38 women; mean age 56.6 ± 12.0 years; range 28–71 years) who underwent VA-ECMO support ($n = 85$) or VV-ECMO ($n = 12$) support between October 2014 and November 2016. ECMO circuit used in this study was a continuous-flow centrifugal pump (JostraRotaflow®; Maquet Cardiopulmonary, Rastatt, Germany), oxygenator (JostraQuadrox; Maquet Cardiopulmonary) and heat exchanger.

Harlequin syndrome was defined as critical variation in the oxygen saturation between upper and lower body (right radial artery versus femoral artery) in patients with VA-ECMO as a result of poor lung function [13]. We identified 12 patients who required conversion to VAV-ECMO support as a result of Harlequin syndrome on VA-ECMO support or cardiac decompensation on VV-ECMO support. Patient characteristics and indications for switching to VAV-ECMO are summarized in Table 1. All patients were evaluated for flow diversion to supplying cannulae using the Stöckert® flow sensor 3/8″ (Sorin Group, Munich, Germany), which is placed on jugular-supplying line. Flow value of each cannula was regulated due to clinical and echocardiographic parameters of patients by tightening or loosening of venous occluder device (Stöckert). The algorithm that describes the management of flow adjustments during VAV-ECMO support in our centre is presented in Fig. 1.

Technical aspects

Eighty-five patients underwent VA-ECMO support via ultrasound-guided percutaneous cannulation with distal anterograde limb perfusion catheter (DPC). Heparin infusion was started, and activated clotting time was measured every 6 h with a target activated clotting time of 160–180 s. Activated partial thromboplastin time was measured twice daily with a target of 50–60 s. After ultrasound-guided femoral vein puncture, a flexible J-tip guide wire is advanced through the common femoral vein (CFV). A 21–23-Fr multiperforated venous cannula (HLS® Cannulae, Maquet®) was inserted over the guide wire up to cavoatrial junction under echocardiography guidance. Otherwise, arterial high flow with 17–19-Fr and 15-cm-length multiperforated cannula (HLS Cannulae, Maquet) was advanced over the guide wire within CFA.

Nine of 85 patients required switching to VAV-ECMO configuration because of Harlequin syndrome. An additional 12–17-Fr cannula was percutaneously inserted through IJV and connected to the supplying cannula in a Y-shaped fashion.

Among 12 patients who needed VV-ECMO support, 3 patients required conversion to VAV configuration. We initially preferred 21-Fr drainage cannula for CFV and 15-Fr supplying cannula for IJV for VV-ECMO support. In these patients, an additional 17–19-Fr arterial cannula was placed to CFA and connected to the IJV cannula in shape of Y to change the configuration.

Flow measurements in the circuit

We measured flow rates of each supplying cannula in patients on VAV-ECMO support. Flow sensor was placed on the IJV-supplying cannula, and we estimated flow diversion ratio between supplying cannulae. Diversion rates of supplying lines at initiation of VAV-ECMO support for 12 patients are summarized on Table 2.

Management of venoarterial/venoarterial–venous ECMO support and weaning protocols

The ECMO support was initiated as VA (CFA-CFV) or VV (IJV-CFV) configuration in all patients. All patients were examined daily for clinical and echocardiographic changes. partial arterial oxygen pressure (PaO_2), partial arterial carbon dioxide pressure ($PaCO_2$), arterial oxygen saturation (SaO_2), pH and lactate levels were monitored via right radial and femoral arterial blood samples. Switching to the VAV-ECMO support was a multidisciplinary decision made by cardiovascular surgeons, anaesthetists and intensivists. On VAV-ECMO support, the position of the arterial-supplying and venous drainage/supplying cannulae was routinely checked by radiographic and echocardiographic evaluation in all patients.

Serial echocardiographic assessments, organ perfusion and arterial pulsatility guided our weaning protocol. After gradual reductions in the sweep gas, we gradually reduced VAV-ECMO pump flow rates in increments of 0.5 l/min over 24 h on full-dose therapeutic anticoagulation. We closely monitored mean blood pressure, central venous pressure, differential arterial blood gases, urine output and lactate levels. On echocardiography, we aimed to show that left ventricular ejection fraction was above 30% with good right ventricular function associated with none to minimal tricuspid regurgitation. Controlled flow diversion of supplying cannulae was achieved according to the haemodynamic, echocardiographic and arterial blood sample findings as described in Fig. 1, by tightening or loosening of venous occluder device, which is placed proximally to flow sensor (Fig. 2). In cases with satisfactory haemodynamic status and signs of left ventricular recovery on echocardiography, arterial inflow was gradually decreased, and ECMO flow was directed towards the IJV-supplying cannula. According to our weaning protocol, these patients were first weaned from arterial support, and ECMO support was converted to VV configuration. In patients without any sign of improvement in haemodynamics, we increased arterial inflow and decreased venous inflow support by tightening venous occluder device with the perspective of supplying adequate oxygenation level to upper body. In case of improved respiratory function and sufficient upper body arterial oxygenation, the IJV cannula was removed and VAV-ECMO support was converted back to VA configuration. In patients, who were bridged to heart transplantation or left ventricular assist device implantation, weaning from VAV-ECMO support was performed by total decannulation after the procedure, if the haemodynamic status and respiratory status of the patient was sufficient. ECMO cannulae and DPC were removed via open surgical approach, and target vessels were surgically repaired.

Downloaded from https://academic.oup.com/icvts/article/33/1/113/6309019 by ANKARA user on 12 December 2021

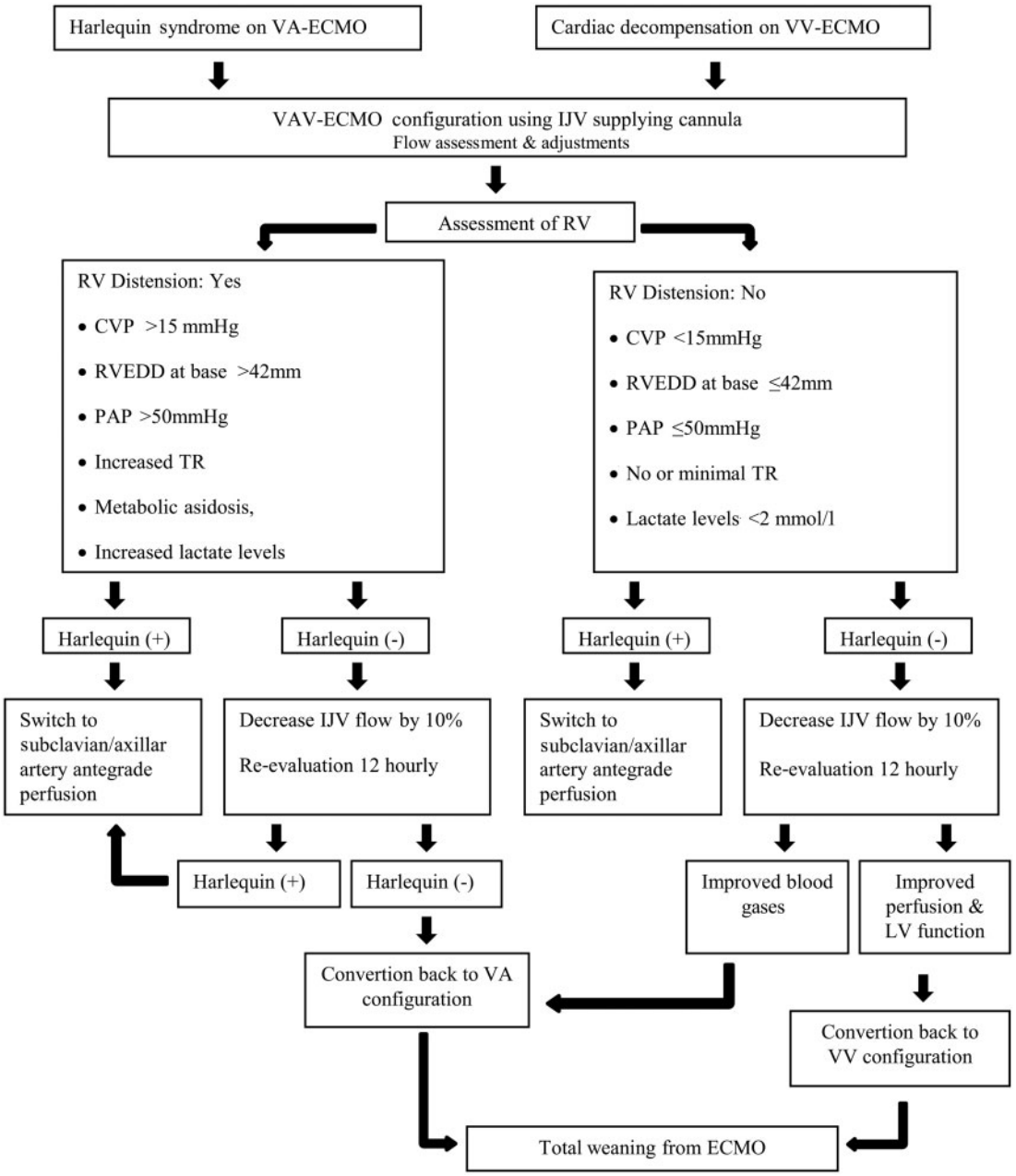

Figure 1: Algorithm of flow management of supplying cannulae for VAV-ECMO configuration. CVP: central venous pressure; ECMO: extracorporeal membrane oxygenation; Harlequin (+): continuing status of upper body deoxygenation (radial artery $SVO_2 < 90$, upper/lower extremity $PO_2 < 0.5$) after VAV support; Harlequin (-): improved upper body deoxygenation after VAV support; IJV: internal jugular vein; LV: left ventricle; PAP: pulmonary artery pressure; RV: right ventricle; RVEDD: right ventricle end-diastolic diameter; TR: tricuspid regurgitation; VA: venoarterial; VV: venovenous.

Follow-up

We assessed anticoagulation status by activated clotting time, activated partial thromboplastin time, platelet count, prothrombin time/international normalized ratio, fibrinogen and D-dimer. Lactate levels were monitored for adequate tissue perfusion. Blood gases in the ECMO circuit before and after going through the oxygenator were assessed by the perfusionists daily. Doppler evaluation of the pedal pulses was performed daily. The ECMO team checked anterograde and retrograde flow patterns through DPCs daily. DPCs were routinely replaced weekly to avoid catheter thrombosis and infection. Arterial blood samples were gained from right radial artery during VA or VV-ECMO support. Both right radial artery and femoral artery blood samples were used to evaluate the perfusion and oxygenation of upper body after conversion to VAV configuration. Haemodynamic, metabolic and echocardiographic values were used to calibrate the adequate perfusion rates through supplying cannulae (Fig. 1).

RESULTS

A total of 12 patients underwent VAV-ECMO support. Demographic and characteristic features of patients prior to VA or VV-ECMO support are summarized in Table 1. Among the 85 patients with VA-ECMO, 9 patients were diagnosed with

Downloaded from https://academic.oup.com/icvts/article/26/1/112/4083519 by ANKARA user on 12 December 2021

Table 1: Patient characteristics and indications of primary ECMO support

Patient	1	2	3	4	5	6	7	8	9	10	11	12	Mean ± SD (%)
Age (years)	59	63	60	65	64	65	66	59	60	41	52	64	61.5 ± 3.5
Gender	M	F	M	M	F	M	F	M	M	M	M	F	8 men/4 women
Weight (kg)	78	62	68	79	73	73	57	62	61	71	90	80	79 ± 1.4
Height (cm)	176	180	166	163	174	182	174	175	177	172	181	168	174 ± 6.1
Body surface area (kg/m^2)	1.94	1.79	1.83	1.84	1.87	1.93	1.68	1.75	1.75	1.84	2.11	1.90	1.9 ± 0.02
Pre-ECMO LVEF (%)	35	25	35	45	35	45	25	40	30	25	45	15	33.3 ± 9.6
Systolic PAP (mmHg)	57	54	66	48	63	59	48	66	70	45	80	60	59.6 ± 10.1
Smoking history	X	X		X	X			X	X		X		58.3%
Chronic renal failure		X					X						16.6%
Diabetes mellitus		X		X			X					X	33.3%
Chronic obstructive lung disease		X				X							16.6%
Coronary artery disease		X	X		X				X				33.3%
Indication for VA-ECMO													
Cardiogenic shock	X	X			X		X		X		X	X	58.3%
Cardiac arrest			X										8.3%
Fulminant myocarditis										X			8.3%
Indication for VV-ECMO													
ARDS						X		X					16.6%
Pulmonary embolism				X									8.3%
Inotropic support													
Dobutamine		X			X		X			X		X	41.6%
Dopamine	X	X	X	X	X		X	X	X	X	X	X	91.6%
Adrenaline	X			X			X		X				33.3%
Noradrenaline	X		X		X	X			X		X	X	58.3%
Indication for VAV-ECMO support													
Harlequin syndrome (VA to VAV)	X	X	X		X		X		X	X	X	X	75%
Low cardiac output (VV to VAV)				X		X		X					25%
Additional supplying cannula (Fr)	15	15	15	19	15	19	15	17	15	17	15	12	12–19
Cannula diameter													
Drainage cannula (Fr)	21	19	19	21	19	21	19	21	21	19	21	21	19–21
Supplying cannula (Fr)	19	17	17	15	17	15	17	15	19	17	19	19	15–19

Data are represented for each patient and the mean + standard deviation (%) values are given in the last column.
ARDS: adult respiratory distress syndrome; ECMO: extracorporeal membrane oxygenation; LVEF: left ventricular ejection fraction; PAP: pulmonary artery pressure; SD: standard deviation; VA: venoarterial; VV: venovenous; VAV: venoarterial–venous.

Harlequin syndrome and switched to VAV-ECMO. On VAV-ECMO support, upper and lower body PaO_2 ratio increased from 0.51 ± 0.07 to 0.93 ± 0.02 and upper and lower body blood oxygen saturation (SaO_2) ratio from 0.75 ± 0.06 to 1 (Table 3). Among 12 patients on VV-ECMO, 3 patients subsequently developed cardiac decompensation and switched to VAV-ECMO. The most common indication for VAV-ECMO was cardiogenic shock (7 of 12 patients). The mean duration of VAV-ECMO support was 6.4 ± 1.8 days. Two patients had chronic renal failure and required renal replacement therapy. Mean value of left ventricular ejection fraction was raised from 33.3 ± 9.6% to 35 ± 5.3% after VA-ECMO support in 9 patients. We experienced left ventricular distention and increase in pulmonary capillary wedge pressure ≥15 mmHg in 2 patients and severe pulmonary oedema in 1 patient during VAV-ECMO support. We performed percutaneous atrial septostomy for decompression of left ventricle in these patients. A femoral vein approach was used, and trans-septal puncture was applied to all patients. The balloon catheter is advanced over the wire into the left atrium and enlarged by stationary balloon dilatation by inflation under biplane fluoroscopy or 2D echocardiography guidance. Atrial septal defect was confirmed by right atrium/left atrium pressure measurements and repeated echocardiographic evaluation.

On VAV-ECMO support, overall 70.0 ± 4.6% of blood flow was detected within the supplying IJV cannula as a result of lower afterload in venous system. We partially occluded and reduced the IJV cannula flow by 10% and echocardiographic evaluation repeated 12 hourly to achieve optimum haemodynamics, oxygenation and right heart measurements and function. After adjustment, 34.3 ± 7.4% of flow was directed to the IJV cannula (Table 2). Initial serum lactate was 4.75 ± 1.8 mmol/l and decreased to 0.73 ± 0.02 mmol/l and mean value of pH levels improved from 7.11 ± 0.06 to 7.39 ± 0.01 after adjusted for VAV-ECMO support (Table 3).

Overall, 8 (66.6%) patients were successfully weaned from VAV-ECMO. We did not detect any specific complications due to triple cannulation strategy. Two patients were bridged to long-term left ventricular assist device implantation and 1 patient to heart transplantation. One patient (1 of 3) died of septic pulmonary emboli causing massive pulmonary haemorrhage in VV to VAV group, whereas 3 patients (3 of 9) died due to septic shock and multiorgan failure in VA to VAV group.

DISCUSSION

Percutaneous ECMO support has been applied with varying degrees of success as a rescue treatment modality in acute cardiopulmonary failure [14]. A recent meta-analysis revealed a 13% absolute increase in 30-day survival with VA-ECMO compared

Downloaded from https://academic.oup.com/icvts/article/34/1/115/6359219 by ANKARA user on 12 December 2021

Table 2: Flow distribution rates of each cannula in non-occluded and occluded forms depending on requirement of organs

	Initial VAV-ECMO		Adjusted VAV-ECMO	
	Flow distribution, l/min (%)		Flow distribution, l/min (%)	
Patient	IJV (%)	CFA (%)	IJV (%)	CFA (%)
1	2.9 (72)	1.1 (28)	1.4 (35)	2.6 (65)
2	2.5 (71)	1.0 (29)	1.1 (31)	2.4 (69)
3	2.6 (74)	0.9 (26)	1.1 (31)	2.4 (69)
4	2.7 (67)	1.3 (33)	1.3 (33)	2.7 (67)
5	2.9 (73)	1.1 (27)	2 (50)	2 (50)
6	3 (67)	1.5 (33)	1.9 (42)	2.6 (58)
7	2.1 (70)	0.9 (30)	1 (33)	2 (67)
8	2.5 (71)	1.0 (29)	1.1 (31)	2.4 (69)
9	2.4 (68)	1.1 (32)	1.5 (43)	2 (57)
10	2.9 (64)	1.6 (36)	1.2 (27)	3.3 (73)
11	2.2 (63)	1.3 (37)	0.8 (23)	2.7 (77)
12	2.4 (80)	0.6 (20)	1.0 (33)	2.0 (67)
Mean ± SD (%)	2.59 ± 0.29 (70.0% ± 4.6)	1.11 ± 0.27 (30.2% ± 4.6)	1.28 ± 0.36 (34.3% ± 7.4)	2.42 ± 0.39 (65.6% ± 7.4)

Data are represented as *n* (%) or mean ± standard deviation.
CFA: common femoral artery; ECMO: extracorporeal membrane oxygenation; IJV: internal jugular vein; VAV: venoarterial–venous.



Figure 2: Placement of flow sensor and occluder device on the IJV supplying line. CFA: common femoral artery; IJV: internal jugular vein.

with patients in which VA-ECMO was not used in the setting of refractory cardiac arrest [15]. In the setting of cardiogenic shock, 33% higher 30-day survival was reported with VA-ECMO compared with patients with IABP support [15]. However, VA-ECMO is also associated with significant complications including bleeding, central nervous system complications, pneumonia, sepsis, renal failure requiring continuous VV haemofiltration, liver dysfunction, limb ischaemia, venous thrombosis and disseminated intravascular coagulation [16, 17]. One of the fatal complications of VA-ECMO is Harlequin syndrome. Harlequin syndrome is a phenomenon related to cannulation strategy, where upper body hypoxia occurs. Impaired lung function and refractory cardiogenic shock with pulmonary oedema may be responsible for differential hypoxia. During VA-ECMO support via femoral artery and vein cannulation, the location of mixing zone of upper and lower arterial flows depends on the amount of ECMO support provided and the degree of left ventricular reserve. In patients with poor left ventricular and pulmonary reserve, deoxygenated blood may be ejected into the coronary and cerebral circulation, resulting in hypoxaemic injury to the heart and brain. In practice, close monitoring of right radial artery and femoral artery blood gases is warranted to detect differential hypoxia. Cerebral near-infrared spectroscopy monitoring is also useful to confirm Harlequin syndrome [17, 18]. Previously reported incidence of Harlequin syndrome in patients on VA-ECMO support was 8.8% [19]. To overcome this phenomenon, there are several strategies including ventilator adjustments, relocating venous drainage cannula [5], increasing ECMO flows [6], switching the arterial cannula to axillary artery [7] or central cannulation techniques. In our practice, we favour switching to VAV-ECMO for an optimum oxygen delivery in patients with differential hypoxia during VA-ECMO support or development of haemodynamic collapse during VV-ECMO support. VAV-ECMO intends to provide oxygenated blood to the right atrium, which then passes through the right heart and lungs, thereby providing oxygenated blood to the coronary arteries and brain. Nine of the 85 patients (10.6%)

Downloaded from https://academic.oup.com/icvts/article/26/1/112/4083519 by ANKARA user on 12 December 2021

Table 3: Characteristics of patients before and after conversion to VAV-ECMO

	Pre-ECMO ($n = 12$)	VA-ECMO ($n = 9$)	VV-ECMO ($n = 3$)	VAV-ECMO (values with initial values; $n = 12$)	VAV-ECMO (values with adjusted flow; $n = 12$)
Mean arterial pressure (mmHg)	48.7 ± 4.7	65.7 ± 6.7	55.0 ± 6.0	67.3 ± 3.7	62 ± 4.48
Central venous pressure (mmHg)	9.08 ± 1.5	4.3 ± 1.06	8.5 ± 2.1	11.5 ± 1.3	7.3 ± 1.37
Right ventricular diameter (mm)	42.9 ± 3.8	32.7 ± 2.9	37 ± 7.1	43 ± 2.1	38.2 ± 2.3
pH	7.11 ± 0.06	7.4 ± 0.01	7.39 ± 0.04	7.41 ± 0.02	7.39 ± 0.01
Lactate (mmol/l)	4.75 ± 1.8	0.8 ± 0.02	2.4 ± 0.6	1.6 ± 0.05	0.73 ± 0.02
ECMO flow through supplying cannulae (%)		100	100	IJV: 70 ± 4.6 CFA: 30 ± 4.6	IJV: 34.3 ± 7.4 CFA: 65.6 ± 7.4
Upper/lower body PaO_2	1.02 ± 0.02	0.51 ± 0.07	0.9 ± 0.06	0.88 ± 0.03	0.93 ± 0.02
Upper/lower body SaO_2	1	0.75 ± 0.06	0.92 ± 0.01	0.97 ± 0.02	1
($PaCO_2$) (mmHg)	46 ± 4.3	40.2 ± 2.25	42.7 ± 3.5	40.7 ± 1.42	39.5 ± 1.5
LVEF (%)	33.3 ± 9.6	35 ± 5.3	40 ± 5	35.8 ± 4.68	36.5 ± 4.98
Systolic PAP (mmHg)	59.6 ± 10.1	43.7 ± 4.43	43.1 ± 3.1	50 ± 6.03	48.7 ± 5.6

Data are represented as mean + standard deviation. Non-adjusted and adjusted ECMO flows are given as IJV or CFA cannula flow percentages of total flow.
CFA: common femoral artery; ECMO: extracorporeal membrane oxygenation; PaO_2: partial arterial oxygen pressure; $PaCO_2$: partial arterial carbon dioxide pressure; SaO_2: arterial oxygen saturation; IJV: internal jugular vein; LVEF: left ventricular ejection fraction; PAP: pulmonary artery pressure; VA: venoarterial configuration; VV: venovenous configuration; VAV: venoarterial–venous configuration; VA-ECMO: Veno-arterial ECMO configuration; VV-ECMO: Veno-venous ECMO configuration; VAV-ECMO: Venoarterial-venous ECMO configuration.

required switching VA-ECMO to VAV-ECMO support for Harlequin syndrome. Converting patients from VV to VAV versus venovenous–arterial support is also an important issue. In patients who require VA-ECMO support due to cardiac dysfunction during VV-ECMO support, we believe that VAV configuration is efficient and avoids Harlequin syndrome, but venovenous–arterial configuration may not contribute to recovery of the differential hypoxia. Later, VAV configuration could be converted to VA-ECMO alone. Axillary cannulation strategy provides antegrade flow, easier ambulation, lower risk of limb ischaemia, potentially better cerebral oxygenation, decreased risk of atheroembolization but has higher rate of bleeding and requires surgical approach to establish vascular access [20]. In patients with thrombocytopenia and haemolysis due to ECMO, we avoid further surgery and risk of bleeding.

Switching to VAV-ECMO necessitates insertion of a supplying cannula to IJV for patients on VA-ECMO support. The IJV-supplying cannula delivers oxygenated blood into the right atrium leading to better oxygenation in the pulmonary artery and left atrium. However, centrifugal pumps are preload- and afterload-sensitive devices, and excessive flow could be directed to venous system. In our experience, approximately 70% of total blood flow was directed towards supplying IJV cannula, which may cause increased right ventricular preload, increased cerebral venous pressure and haemodynamic instability [8]. To overcome this handicap, we adjusted the flow rates of supplying lines with an occluder device on the IJV cannula, until satisfactory oxygenation and perfusion were achieved. In our last experience (Patient 12), we preferred a 12-Fr cannula for left IJV as supplying cannula to avoid any injury to superior vena cava anastomosis after heart transplantation. In cases with significant hypoxia, small cannulae may result in limited and inadequate flow supply. Hence, we were reluctant to use small-sized cannulae for venous-supplying cannula in every patient. However, smaller-sized cannulae for IJV may be primarily preferred for the patients with insufficient right IJV diameter, severe right heart failure and history of heart transplantation.

In our series, 3 patients required VAV-ECMO support during VV-ECMO. A primary advantage of VAV-ECMO in the setting of respiratory failure and further cardiac failure is providing better upper body oxygenation and avoiding pulmonary vasoconstriction [8, 21, 22]. Patients with right heart failure should be frequently evaluated using echocardiography after insertion of the IJV cannula to avoid a possible right ventricular overload.

Only scanty data from case series and small observational studies are available for the management of VAV-ECMO support [12]. Previously, Biscotti *et al.* [10] reported that they directed two-thirds of the reinfusion blood flow towards the arterial limb using Hoffman tubing clamp. To our knowledge, this small patient cohort is the first which describes a novel solution by monitoring differential blood flows within supplying cannulae and use of venous occluder device to prevent right ventricular overload on VAV-ECMO support. In our study, the degree of flow adjustment was decided according to the echocardiographic findings and differential right radial and femoral arterial blood sample results (Fig. 1).

Weaning VAV-ECMO support is an individualized and gradual process aiming at adequate support with minimal flow. During weaning from VAV-ECMO, supplying perfusion should not be less than 1 l/min to avoid a possible occlusion of distal perfusion catheter that may lead to limb ischaemia.

Limitations

Retrospective case series are susceptible to reporting bias; however, all the presented data are prospectively collected. Another limitation of this report is that there was no control group with no flow diversion. The aim of this report is sharing our experiences with ECMO specialists globally for better care and management of complex ECMO problems.

CONCLUSION

Harlequin syndrome is not a rare event during VA-ECMO support. Differential upper and lower body blood oxygen saturations and oxygen content are useful measures for accurate diagnosis. Our observations suggest that, on VAV-ECMO, differential flow

Downloaded from https://academic.oup.com/ 19 by ANKARA user on 12 December 2021

rates between supplying cannulae occur as a result of afterload mismatch and result in right heart distention. Quantifying flow rates within the supplying cannulae with flow sensors and the use of occluder device for high flow rates within the venous system can be a rational strategy for optimum oxygen delivery and perfusion on VAV-ECMO support.

ACKNOWLEDGEMENTS

We sincerely thank all members of 'Heart Failure and Transplant Team' for daily management of the patients, Saadet Aslan for echocardiographic assessments and intensive care unit nurses for their outstanding assistance.

Conflict of interest: none declared.

REFERENCES

[1] Squiers JJ, Lima B, DiMaio JM. Contemporary extracorporeal membrane oxygenation therapy in adults: fundamental principles and systematic review of the evidence. J Thorac Cardiovasc Surg 2016;152:20–32.
[2] Abrams D, Combes A, Brodie D. Extracorporeal membrane oxygenation in cardiopulmonary disease in adults. J Am Coll Cardiol 2014;63:2769–78.
[3] Sayer GT, Baker JN, Parks KA. Heart rescue: the role of mechanical circulatory support in the management of severe refractory cardiogenic shock. Curr Opin Crit Care 2012;18:409–16.
[4] Orhan G, Mete EMT, Sargin M, Kudsioglu T, Erdogan SB, Guvenc TS *et al*. Are mechanical assist devices life-saving in acute cardiogenic shock? Turk Gogus Kalp Dama 2016;24:454–61.
[5] Lindfors M, Frenckner B, Sartipy U, Bjallmark A, Broome M. Venous cannula positioning in arterial deoxygenation during Veno-arterial extracorporeal membrane oxygenation-A simulation study and case report. Artif Organs 2017;41:75–81.
[6] Bartlett RH. Physiology of gas exchange during ECMO for respiratory failure. J Intensive Care Med 2017; 32:243–8.
[7] Pujara D, Sandoval E, Simpson L, Mallidi HR, Singh SK. The state of the art in extracorporeal membrane oxygenation. Semin Thorac Cardiovasc Surg 2015;27:17–23.
[8] Moravec R, Neitzel T, Stiller M, Hofmann B, Metz D, Bucher M *et al*. First experiences with a combined usage of veno-arterial and veno-venous ECMO in therapy-refractory cardiogenic shock patients with cerebral hypoxemia. Perfusion 2014;29:200–9.
[9] Bonacchi M, Harmelin G, Peris A, Sani G. A novel strategy to improve systemic oxygenation in venovenous extracorporeal membrane oxygenation: the "chi-configuration". J Thorac Cardiovasc Surg 2011;142: 1197–204.
[10] Biscotti M, Lee A, Basner RC, Aqerstrand C, Abrams D, Brodie D *et al*. Hybrid configurations via percutaneous access for extracorporeal membrane oxygenation: a single-center experience. ASAIO J 2014;60:635–42.
[11] Choi JH, Kim SW, Kim YU, Kim YS, Kim KS, Joo SJ *et al*. Application of veno-arterial-venous extracorporeal membrane oxygenation in differential hypoxia. Multidiscip Respir Med 2014;9:55.
[12] Napp LC, Kuhn C, Hoeper MM, Vogel-Claussen J, Haverich A, Schafer A *et al*. Cannulation strategies for percutaneous extracorporeal membrane oxygenation in adults. Clin Res Cardiol 2016;105:283–96.
[13] Avgerinos DV, DeBois W, Voevidko L, Salemi A. Regional variation in arterial saturation and oxygen delivery during venoarterial extracorporeal membrane oxygenation. J Extra Corpor Technol 2013;45:183–6.
[14] Cardarelli MG, Young AJ, Griffith B. Use of extracorporeal membrane oxygenation for adults in cardiac arrest (E-CPR): a meta-analysis of observational studies. ASAIO J 2009;55:581–6.
[15] Ouweneel DM, Schotborgh JV, Limpens J, Sjauw KD, Engstrom AE, Lagrand WK *et al*. Extracorporeal life support during cardiac arrest and cardiogenic shock: a systematic review and meta-analysis. Intensive Care Med 2016;42:1922–34.
[16] Zangrillo A, Landoni G, Biondi-Zoccai G, Greco M, Greco T, Frati G *et al*. A meta-analysis of complications and mortality of extracorporeal membrane oxygenation. Crit Care Resusc 2013;15:172–8.
[17] Raleigh L, Ha R, Hill C. Extracorporeal membrane oxygenation applications in cardiac critical care. Semin Cardiothorac Vasc Anesth 2015;19: 342–52.
[18] Lawler PR, Silver DA, Scirica BM, Couper GS, Weinhouse GL, Camp PC. Extracorporeal membrane oxygenation in adults with cardiogenic shock. Circulation 2015;131:676–80.
[19] Rupprecht L, Lunz D, Philipp A, Lubnow M, Schmid C. Pitfalls in percutaneous ECMO cannulation. Heart Lung Vessel 2015;7:320–6.
[20] Cakıcı M, Ozcinar E, Baran C, Bermede AO, Saricaoglu MC, Inan MB *et al*. A retrospective cohort analysis of percutaneous versus side-graft perfusion techniques for veno-arterial extracorporeal membrane oxygenation in patients with refractory cardiogenic shock. Perfusion 2017; 32:363–71.
[21] Ius F, Sommer W, Tudorache I, Avsar M, Siemeni T, Salman J *et al*. Veno-veno-arterial extracorporeal membrane oxygenation for respiratory failure with severe haemodynamic impairment: technique and early outcomes. Interact CardioVasc Thorac Surg 2015;20:761–7.
[22] Stohr F, Emmert MY, Lachat ML, Stocker R, Maggiorini M, Falk V *et al*. Extracorporeal membrane oxygenation for acute respiratory distress syndrome: is the configuration mode an important predictor for the outcome? Interact CardioVasc Thorac Surg 2011;12:676–80.

Downloaded from https://academic.oup.com/icvts/article/26/1/112/4083519 by ANKARA user on 12 December 2021