Bratislava Medical Journal
https://doi.org/10.1007/s44411-026-00697-w

RESEARCH

Margins Matter: Surgical Outcomes in Malignant Proliferating Trichilemmal Tumor of the Scalp

Servet Elçin Alpat[1] · **Elif Akbay**[2,3] · **Burak Kaya**[1,4] · **Bilge Ayça Kırmızı**[5] · **Savaş Serel**[1]

Received: 31 March 2026 / Revised: 30 May 2026 / Accepted: 4 June 2026
© The Author(s) 2026

Abstract

Background Malignant proliferating trichilemmal tumor is a rare adnexal malignancy derived from the outer root sheath. It most often affects the scalp and may be mistaken for squamous cell carcinoma because of overlapping clinical and histopathological features. As a result, management is largely informed by small case series and case reports.

Methods We retrospectively reviewed 11 consecutive patients with histopathologically confirmed malignant proliferating trichilemmal tumor managed at two tertiary referral centers between January 2020 and May 2024. Demographic, clinicopathological, operative, immunohistochemical, and follow-up data were analyzed. To place our cohort in context, we also performed a focused narrative review of the recent literature on malignant proliferating trichilemmal tumor and related trichilemmal malignancies.

Results The mean age was 64.1 ± 5.7 years (range, 55–74 years), and 7 patients were female. Mean tumor diameter was 27.5 ± 9.1 mm. Five patients (45.5%) had coexisting trichilemmal cysts. All patients underwent wide local excision with planned 1–2 cm clinical margins; 6 patients (54.5%) required local or free flap reconstruction. p53 showed diffuse nuclear positivity in 10 of 11 tumors (90.9%), and Ki-67 exceeded 20% in 8 of 11 (72.7%). Two patients (18.2%) had compromised deep margins on the index excision specimen and underwent re-excision. No local recurrence, nodal disease, or distant metastasis was identified during a mean follow-up of 16.3 ± 5.4 months.

Conclusions In this cohort, malignant proliferating trichilemmal tumor behaved primarily as a locally aggressive scalp malignancy in which adequate deep clearance was critical to definitive surgical management. Achieving histologically clear margins—particularly at the deep plane—and performing prompt re-excision when margins were compromised were the decisive factors for local control. Misinterpretation as squamous cell carcinoma remains a diagnostic pitfall on limited biopsy material and the reconstructive burden is notable, with more than half of patients requiring complex reconstruction. Mohs micrographic surgery is a reasonable option in selected cases, though the supporting data come largely from trichilemmal carcinoma and should not be applied to malignant proliferating trichilemmal tumor without caution. Careful pathological review and long-term follow-up are necessary for all patients.

Keywords Malignant proliferating trichilemmal tumor · Proliferating trichilemmal tumor · Scalp neoplasm · Wide local excision · Surgical margins · Adnexal malignancy

✉ Servet Elçin Alpat
elcinisilgan@gmail.com

Elif Akbay
drelifakbay@gmail.com

Burak Kaya
drburak@yahoo.com

Bilge Ayça Kırmızı
akarabork@yahoo.com

Savaş Serel
savasserel@gmail.com

[1] Department of Plastic, Reconstructive and Aesthetic Surgery, Faculty of Medicine, Ankara University, Ankara, Türkiye

[2] Plastic, Reconstructive and Aesthetic Surgery Clinic, Sabuncuoğlu Şerefeddin Training and Research Hospital, Amasya University, Amasya, Türkiye

[3] Present address: Özel Pendik Yüzyıl Hastanesi, İstanbul, Türkiye

[4] Present address: Burak Kaya Clinic, Ankara, Türkiye

[5] Department of Pathology, Faculty of Medicine, Ankara University, Ankara, Türkiye

Published online: 14 June 2026

1 Introduction

The scalp harbors a broad spectrum of benign and malignant lesions, ranging from common cystic and keratinocytic lesions to malignant melanoma and adnexal carcinomas [1, 2]. Within this spectrum, malignant proliferating trichilemmal tumor (MPTT) is a rare follicular adnexal malignancy derived from the outer root sheath. Although it is most often encountered on the scalp of older individuals, its true biological behavior remains difficult to define because the available literature is dominated by isolated case reports and small case-based series [3, 4].

The nomenclature surrounding this tumor has been historically inconsistent, with terms such as proliferating pilar tumor, proliferating trichilemmal cyst, proliferating epidermoid cyst, giant hair matrix tumor, and trichochlamydocarcinoma used interchangeably across different studies and eras [3–5]. Although "proliferating trichilemmal tumor" has gained acceptance as the standard designation in contemporary classifications, the broader term does not capture the biological heterogeneity within this tumor spectrum, ranging from indolent cystic proliferations to locally invasive neoplasms with malignant potential. MPTT is generally thought to arise through malignant transformation within a pre-existing proliferating trichilemmal cyst or simple trichilemmal cyst [3, 4]. Most reported tumors occur on the scalp, likely reflecting the high follicular density of this region, and their histopathological evaluation may be challenging because abrupt trichilemmal keratinization, the absence of a granular layer, invasive lobular growth, and variable cytologic atypia can closely mimic squamous cell carcinoma (SCC) [5–8]. Correct distinction is clinically important because, although MPTT may behave aggressively at the local level, metastatic spread appears to be uncommon and is reported mainly in selected advanced cases [5, 8].

From a surgical standpoint, complete excision with histologically negative margins remains the cornerstone of treatment [9–11]. Wide local excision is the most commonly reported approach, whereas Mohs micrographic surgery has been described mainly in selected cases and appears more strongly supported in the trichilemmal carcinoma (TC) literature than in bona fide MPTT [9, 10]. Evidence for adjuvant radiotherapy, chemotherapy, or other ancillary treatment strategies remains sparse and largely anecdotal, and very large scalp lesions may still require extensive resection and complex reconstruction [11–14]. Because of this limited evidence base for MPTT, contemporary referral-center cohorts remain valuable. The present study reports 11 histopathologically confirmed MPTTs managed at two high-volume tertiary referral centers. Our aim was to describe the clinical profile, pathological features, reconstructive requirements, and oncologic outcomes of this cohort, and to discuss these findings in the context of the available literature without overstating conclusions drawn from related but distinct trichilemmal malignancies.

2 Materials and methods

2.1 Ethical Approval, Study Design, and Patient Selection

This study was approved by the Institutional Review Boards of both participating centers (Approval No. 2024/459 and Approval No. 2021/15) and conducted in accordance with the Declaration of Helsinki. The consent process was managed in line with institutional requirements for retrospective studies. Patients treated between January 2020 and May 2024 were reviewed. Inclusion criteria were a histopathological diagnosis of MPTT involving the scalp or posterior neck, availability of complete operative and pathology records, and a minimum postoperative follow-up of 9 months. Cases with incomplete documentation were excluded. Demographic, clinical, operative, histopathological, immunohistochemical, and follow-up data were collected from the medical records. The presence of coexisting trichilemmal cysts was recorded from clinical documentation and operative notes.

2.2 Surgical Management

All patients underwent excision under general anesthesia. Across both centers, the operative strategy during the study period was to plan 1–2 cm clinical margins, with depth tailored to intraoperative findings. Frozen-section analysis was not routinely used; margin assessment was based on permanent paraffin sections. When clinical fixation suggested possible deep extension, the deep resection plane was extended to include the periosteum. Reconstruction was individualized according to the final defect size, depth, and location using primary closure, split thickness skin grafting, local flap reconstruction or free-tissue transfer.

2.3 Histopathological and Immunohistochemical Evaluation

All specimens underwent routine hematoxylin-eosin evaluation. Immunohistochemical analysis was performed on formalin-fixed, paraffin-embedded tissue using standardized protocols. p53 positivity was defined as strong diffuse nuclear staining in more than 10% of tumor cells. Ki-67 was assessed in hotspot areas, and a proliferative index greater than 20% was categorized as high. Margin status was recorded as negative (> 1 mm clearance), close (< 1 mm),

or positive (ink on tumor). Lymphovascular invasion and perineural invasion were documented when present.

2.4 Follow-up and Statistical Analysis

Patients were scheduled for follow-up at 3, 6, and 12 months after surgery and annually thereafter. Local recurrence was defined as histologically confirmed tumor at or adjacent to the primary operative site. Residual disease identified in a planned re-excision specimen obtained for compromised margins on the index excision was not classified as local recurrence; instead, such cases were categorized as incomplete primary resection. Follow-up duration was calculated from the date of the final margin-negative resection. As no local recurrence was observed during follow-up, inferential analysis of recurrence-related outcomes was not performed, and outcomes were summarized descriptively. Analyses were performed with GraphPad Prism version 10.2.0 (GraphPad Software, Boston, MA, USA). Continuous variables are presented as mean ± standard deviation, and categorical variables as number (percentage).

2.5 Contextual Literature Mapping

To contextualize the findings of the present cohort, we performed a focused descriptive mapping of the literature. MEDLINE, Embase, Science Citation Index, Google Scholar, and PubMed were searched through December 2025 for publications relevant to malignant proliferating trichilemmal tumor, trichilemmal carcinoma, scalp adnexal malignancy, and outer root sheath neoplasms, together with closely related variants such as proliferating trichilemmal tumor, proliferating pilar tumor, and malignant proliferating trichilemmal cyst. Title-, abstract-, and keyword-level screening was used to characterize the breadth, overlap, and publication profile of the retrieved literature. This mapping was intended to identify publications relevant to MPTT diagnosis, margin control, recurrence, and reconstructive management. Selected studies on trichilemmal carcinoma were included for contextual discussion of surgical strategy, margin control, and diagnostic overlap, but were clearly distinguished from MPTT data throughout. This component was designed as a descriptive contextual mapping exercise rather than a formal systematic review, scoping review, or evidence synthesis.

Table 1 Patient Demographics and Tumor Characteristics

Characteristics	Value	Details
Total patients	11	7 F, 4 M
Mean age, years	64.1 ± 5.7	Range, 55–74
Tumor location	Scalp in all cases	1 extended to posterior neck
Coexisting pilar cysts	5/11 (45.5%)	
Mean tumor size, mm	27.5 ± 9.1	
Histological diagnosis	MPTT in all cases	Confirmed on H&E
Diffuse p53 positivity	10/11 (90.9%)	Strong nuclear staining
Ki-67 > 20%	8/11 (72.7%)	High proliferative activity
LVI / PNI	0 / 0	Not identified

H&E, hematoxylin-eosin; LVI, lymphovascular invasion; MPTT, malignant proliferating trichilemmal tumor; PNI, perineural invasion

3 Results

3.1 Demographic and Tumor Characteristics

Eleven patients were included, with a female-to-male ratio of 1.75/1. Mean age at presentation was 64.1 ± 5.7 years. All lesions arose on the hair-bearing scalp, and 1 extended toward the posterior neck. Mean tumor diameter was 27.5 ± 9.1 mm (Table 1). No patient had a documented history of xeroderma pigmentosum or a defined photosensitivity disorder. Five of 11 patients (45.5%) had documented coexisting trichilemmal (pilar) cysts at the time of presentation, supporting the recognized association between pilar cysts and the development of proliferating trichilemmal tumors.

3.2 Surgical Treatment and Reconstruction

All patients underwent wide local excision with planned 1–2 cm clinical margins. Six patients (54.5%) required complex reconstruction using local pedicled flaps or free tissue transfer due to defect size and scalp location (Fig. 1). The remaining 5 patients (45.5%) were managed with primary closure or split-thickness skin grafting. No patient in this series required periosteal resection or calvarial burring, because gross fixation to the periosteum was not encountered. Permanent pathology of the index excision showed deep margin compromise in 2 patients, and both margins were positive. Both subsequently underwent planned re-excision to achieve clear margins.

3.3 Histopathological and Immunohistochemical Findings

All tumors showed features consistent with MPTT, including abrupt trichilemmal keratinization without a granular layer, invasive lobular growth, and variable cytologic atypia (Fig. 2). Neither lymphovascular invasion nor perineural invasion was identified. Diffuse nuclear p53 positivity was observed in 10 of 11 cases (90.9%), and Ki-67 exceeded 20% in 8 of 11 cases (72.7%).



Fig. 1 Clinical images of two patients with MPTT of the scalp. **(a)** Preoperative appearance of a scalp MPTT in the first patient. **(b)** Intraoperative marking for wider re-excision following histopathological confirmation of positive margins on the initial specimen; the defect was subsequently reconstructed with a double-rotation (yin-yang) scalp flap. **(c)** Preoperative appearance of a second patient presenting with extensive MPTT occupying more than half of the scalp surface, with multiple coexisting trichilemmal cystic lesions. **(d)** Postoperative result following scalp reconstruction with a radial forearm free flap.

3.4 Oncologic Outcomes

Mean follow-up was 16.3 ± 5.4 months. No local recurrence was observed during follow-up. Two patients (18.2%) had compromised deep margins on the pathology of the index excision specimen and therefore underwent planned re-excision. In these cases, residual tumor was identified in the re-excision specimen, consistent with incomplete deep clearance rather than true postoperative recurrence. No regional nodal metastasis or distant spread was documented during follow-up. At final follow-up, all patients were free of documented local, regional, or distant disease (Table 2).

3.5 Descriptive Landscape of the Literature

Descriptive mapping of the retrieved literature identified 382 records published between 1969 and March 2025. On title-, abstract-, and keyword-level screening, 293 records

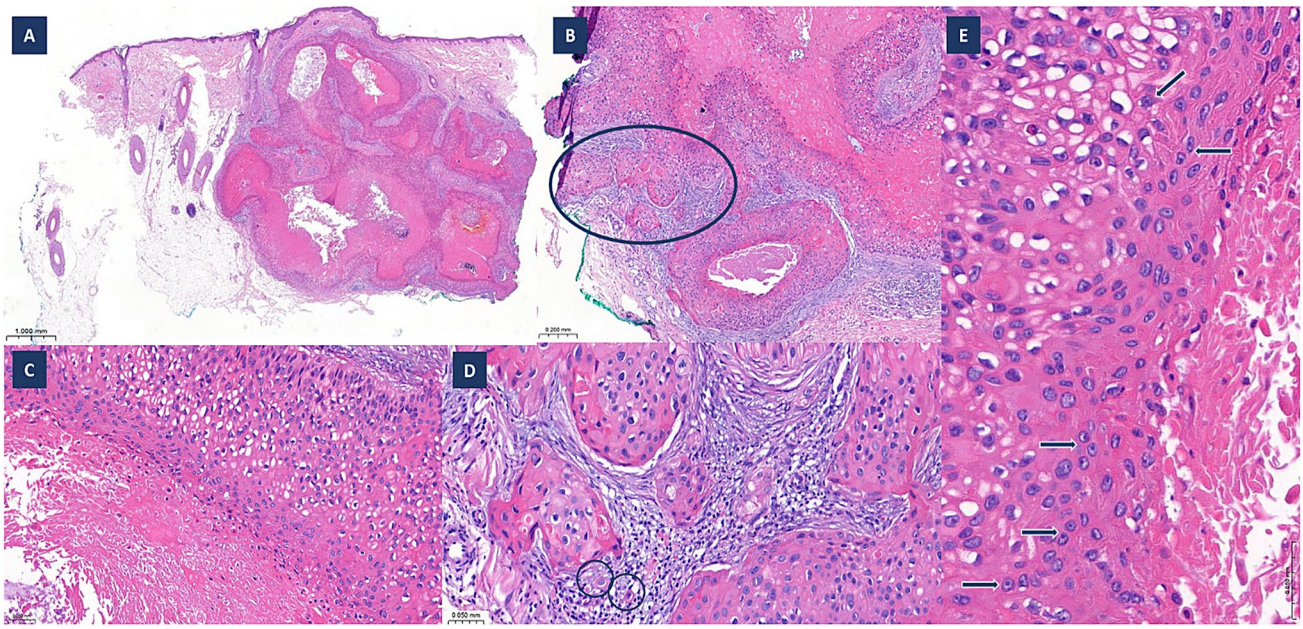

Fig. 2 **(a)** Low-power view showing lobular tumor architecture with central trichilemmal keratinization and peripheral cellular palisading. **(b)** Intermediate magnification; the circled area marks the invasive front where tumor infiltrates adjacent stroma — the feature distinguishing this from a benign proliferating pilar tumor. **(c)** High-power view of the keratinizing center and peripheral proliferating cells showing mild cytologic atypia, focal clear cytoplasm, vesicular nuclei, and prominent nucleoli. **(d)** High-power view of the invasion zone with irregular tumor islands and single infiltrating cells (circles) within the stroma. **(e)** High-power view of residual tumor within scar tissue (re-excision specimen); arrows indicate tumor cells with vesicular nuclei and prominent nucleoli, indicating persistent microscopic disease after the index excision.

Table 2 Surgical Management and Outcomes

Parameter	*n* (%)	Notes
Wide local excision	11 (100%)	Planned 1–2 cm clinical margins
Complex reconstruction	6 (54.5%)	Local pedicled flap or free flap
Primary closure / STSG	5 (45.5%)	Smaller defects
Compromised deep margin on index excision pathology	2 (18.2%)	Both underwent re-excision
Local recurrence	0	None observed
Regional or distant metastasis	0	None observed
Disease-free at final follow-up	11 (100%)	Mean follow-up 16.3 months; no documented disease

STSG, split-thickness skin grafting

were found to contain at least one predefined trichilemmal concept or a closely related variant. Within this concept-based body of literature, 78 records were focused on MPTT, 85 addressed TC, 126 fell within the broader proliferating trichilemmal/pilar tumor spectrum, 63 used outer or external root sheath terminology, and 41 addressed adnexal malignancy or related adnexal neoplastic terminology. Because individual records could contribute to more than one concept, these categories were overlapping and not mutually exclusive.

The publication profile was dominated by low-level evidence. Among the concept-based records, 216 were case reports or case-based publications, whereas only 27 were narrative reviews, 2 were systematic reviews, and 3 were comparative studies. Temporally, the literature was distributed across 32 publications from 1969 to 1989, 105 from 1990 to 2009, 92 from 2010 to 2019, and 64 from 2020 through March 2025, indicating continued publication activity but limited expansion of higher-level outcome data.

Several descriptive patterns identified in the mapped literature help contextualize the present cohort. Scalp involvement was referenced in 159 records, supporting the scalp as the dominant anatomical setting for this tumor spectrum. Fifty-nine records described diagnostic overlap with SCC, underscoring the persistent histopathological and clinical difficulty of distinguishing trichilemmal malignancies from SCC. Seventy-three records addressed recurrence and 78 addressed metastatic disease, suggesting that aggressive behavior is clearly documented in the literature but appears to be concentrated in a subset of infiltrative, recurrent, or incompletely excised tumors rather than reflecting the usual course. Finally, 24 records mentioned Mohs surgery; however, these data were derived predominantly from the TC literature rather than from bona fide MPTT series. Overall, the mapped literature supports complete excision with histologically negative margins and structured follow-up as consistent management principles, while also indicating that Mohs-associated outcome data should not be directly

Table 3 Selected literature used to contextualize the findings of the present MPTT cohort

Study	Cohort size	Disease context	Surgical approach	Reported recurrence	Main contribution
Present study	11	MPTT	WLE; reconstruction tailored to defect	No local recurrence; no nodal or distant metastasis	Cohort-based evidence that compromised deep margins prompted re-excision and that durable local control depended on complete deep clearance.
Ye et al., 2004	76	PPT spectrum (benign, low-grade and high-grade malignant)	Excision in all cases	Group 1: 0/48; Group 2: 3/20 (15%); Group 3: 4/8 (50%) recurrence/ metastasis	Three-tiered classification correlating invasion and atypia with behavior; meta-analysis of 185 cases from 8 series
Osto et al., 2021	65 patients from 39 studies	Scalp MPTT systematic review	Predominantly surgical; mixed adjuvant use	Regional nodal disease 15.4%; distant metastasis 9.2%; recurrence 24.4% among followed cases	Best pooled MPTT-specific benchmark for presentation, recurrence, and surveillance
Kearns-Turcotte et al., 2022	4	MPTT with multiple trichilemmal cysts	WLE + LND; reconstruction tailored to defect	No recurrence in reported follow-up	Highlights transformation spectrum, SCC misclassification, and reconstructive burden
Sun et al., 2023	231	TC	Mixed	Recurrence and metastasis reported; head and neck predominance	Large, pooled TC dataset
Shahinfar et al., 2024	100	TC	WLE vs. MMS	Recurrence 10.1% after WLE vs. 4.8% after Mohs	Suggests a possible recurrence advantage for margin-controlled surgery in TC
Al-Aswad et al., 2024	12	Immobile scalp malignancies with deep fixation	Excision with calvarial burring and graft reconstruction	Two recurrences; STSG outperformed FTSG on burred calvaria	Useful reconstructive analogue when periosteal or calvarial involvement is suspected
Liu et al., 2016	3	Giant scalp malignancies, including 1 MPTT	Extensive resection and flap-based reconstruction	No recurrence in reported follow-up	Supports aggressive resection and complex reconstruction in giant scalp defects

Abbreviations: LND, lymph node dissection; MMS, Mohs micrographic surgery; MPTT, malignant proliferating trichilemmal tumor; NR, not reported; TC, trichilemmal carcinoma; WLE, wide local excision

extrapolated from TC to MPTT without caution. Against this broader descriptive literature landscape, Table 3 highlights selected studies that provide the most relevant clinical context for interpreting the present cohort.

4 Discussion

Our series represents one of the larger contemporary scalp MPTT cohorts reported from high-volume tertiary referral centers. The central message of this cohort was not distant aggressiveness, but the importance of complete deep excision in achieving durable local control. Although no local recurrence was observed during follow-up, 2 patients had compromised deep margins on index excision pathology and required re-excision, with residual tumor identified in the re-excision specimen. These findings support the view that inadequate deep clearance is a surgically relevant problem in scalp MPTT even when overt recurrence has not yet developed.

The use of the term "malignant" in the context of proliferating trichilemmal tumors warrants discussion. It is recognized that proliferating trichilemmal tumors exist on a biological spectrum, as formalized in the three-tiered classification proposed by Ye et al. [15]. Based on the histological profile of the tumors in our cohort—which demonstrated invasive lobular growth with variable but not marked cytologic atypia, in the absence of geographic necrosis or pathologic mitotic forms—the present cases correspond most closely to Ye et al.'s Group 2, designated by the authors as "low-grade malignant proliferating pilar tumors (LMPPTs)." In their series, 15% of Group 2 tumors recurred locally, a figure that parallels our finding that 18.2% of patients had compromised deep margins requiring re-excision. This

concordance strengthens the view that our tumors behave as low-grade malignant neoplasms and supports the continued use of the "malignant" designation.

The absence of distant metastasis in our cohort does not, in our view, argue against malignancy. Malignancy encompasses more than metastatic potential alone; it includes invasive growth, cytologic atypia, destructive local behavior, and the capacity for recurrence. All tumors in our cohort demonstrated invasive lobular growth, diffuse p53 positivity was present in 90.9%, Ki-67 exceeded 20% in 72.7%, and two patients had residual tumor confirmed on re-excision specimens. These features constitute functional malignancy in the surgical and pathological sense—a concept described by Sharma et al. in the context of proliferating trichilemmal tumors, whereby a tumor exhibits invasive, destructive, and recurrence-prone behavior despite the absence of distant spread or overt cytologic anaplasia [16]. Furthermore, the published literature confirms that proliferating trichilemmal tumors can metastasize: Park et al. documented a case that recurred multiple times and metastasized to regional and distant sites, with serial specimens demonstrating progressive increases in Ki-67 positivity [17]. In their meta-analysis of 185 cases from 8 series, Ye et al. reported overall local recurrence and lymph node metastasis rates of 3.7% and 1.2%, respectively, and noted that these figures are almost certainly underestimates owing to incomplete follow-up in some included studies [15]. Thus, the absence of metastasis at a given time point does not preclude future malignant progression, and we believe that retaining the "malignant" designation is both histopathologically justified and clinically prudent. From a practical standpoint, designating these tumors as non-malignant may lead surgeons to underestimate the importance of deep margin control and prompt re-excision when margins are compromised—precisely the factors that determined local control in our series.

These findings should be interpreted in light of the study design and available follow-up, yet the cohort still provides meaningful referral-center evidence on the practical importance of complete deep excision in scalp MPTT. The overall pattern is biologically plausible and consistent with the published MPTT literature, in which complete surgical removal remains the dominant therapeutic principle and adverse local outcomes are reported most often in infiltrative, recurrent, or incompletely excised lesions, particularly in scalp tumors where the galea, periosteum, and calvarial interface can make deep clearance technically demanding [3–5, 11, 18, 19]. Case-based reports similarly support wide excision with histologically clear margins as the most defensible approach when infiltrative growth or marked cytologic atypia is present [20].

Our observations are broadly consistent with the most informative pooled data currently available for scalp MPTT (Table 3). In the only systematic review focused specifically on scalp disease, Osto et al. summarized 39 studies including 65 patients and reported regional nodal involvement at presentation in 15.4%, distant metastasis in 9.2%, and recurrence in 24.4% of cases with documented follow-up [19]. Their review further supported complete surgical excision as the principal treatment strategy and highlighted the importance of continued surveillance. By comparison, no local recurrence was observed in our series during the available follow-up period. However, this apparently favorable outcome should not obscure the surgical relevance of margin control, as 2 patients required re-excision because of compromised deep margins. Taken together, these findings suggest that the absence of documented recurrence in a short-term cohort does not diminish the importance of complete deep clearance in scalp MPTT.

A second important point is the emphasis on histopathological discipline. MPTT remains a lesion in which adequate sampling, morphology and clinicopathologic correlation are indispensable. In both pooled and case-series literature, these tumors have repeatedly been described as lesions that may be mistaken for SCC, particularly on limited biopsy material or in ulcerated tumors [6, 7, 13, 18, 19]. Kearns-Turcotte et al. reported four MPTTs arising in patients with multiple trichilemmal cysts, including cases in which initial biopsy suggested SCC and final excision established the trichilemmal diagnosis [18]. Similarly, Ye et al. demonstrated in their study of 76 proliferating pilar tumors that careful histologic evaluation is essential for distinguishing benign from malignant variants, and their three-tiered classification system provides a practical framework for histopathological grading [15]. This view is also supported by earlier clinicopathologic work suggesting that proliferating trichilemmal lesions occupy a biologic spectrum in which careful histologic assessment may help identify tumors with more aggressive potential and guide prognostic interpretation [21, 22]. In our view, the diagnosis should rest primarily on morphologic features, with immunohistochemistry serving as an adjunct rather than a substitute. The high frequency of diffuse p53 positivity and elevated Ki-67 in our cohort is in keeping with prior reports suggesting that these markers may help distinguish malignant lesions from benign proliferating trichilemmal tumors, although they should not be interpreted in isolation [4, 19, 23].

The finding that 5 of 11 patients (45.5%) in our cohort had coexisting trichilemmal (pilar) cysts at presentation warrants comment. This observation is consistent with the well-recognized transformation spectrum from simple pilar cyst to proliferating trichilemmal tumor and, in some cases, to malignant proliferating trichilemmal tumor. Kearns-Turcotte et al. similarly reported MPTT arising in patients with multiple trichilemmal cysts [18], Ye et al. documented this

association in their large clinicopathologic series [15], and Park et al. described a case arising in the setting of a long-standing trichilemmal lesion that underwent progressive malignant transformation over a decade [17]. This coexistence supports the hypothesis that MPTT may develop through progressive transformation of pre-existing trichilemmal cysts and suggests that patients presenting with multiple pilar cysts may benefit from clinical surveillance for the development of rapidly growing or changing lesions.

The reconstructive burden in this series is also notable. More than half of the patients required flap-based or free-tissue reconstruction, a reminder that even infrequent adnexal malignancies can produce substantial defects once adequately resected. This observation aligns with Kearns-Turcotte et al., who described large scalp tumors requiring flap, graft, and free-flap reconstruction [18]. It is also supported indirectly by Liu et al., who reported a giant scalp MPTT requiring extensive resection and reconstruction, illustrating the scale of soft-tissue deficits that can arise when long-standing lesions are finally treated definitively [14]. Although not specific to MPTT, Al-Aswad et al. further help frame the deep-plane reconstructive problem on the scalp: fixation may indicate galeal or periosteal involvement, large lesions may justify preoperative imaging, and split-thickness grafts performed better than full-thickness grafts on burred calvaria [24]. From a practical standpoint, oncologic clearance and reconstruction should be planned together in scalp MPTT, particularly in larger lesions or those approaching the deep plane.

The role of Mohs micrographic surgery should be discussed carefully and without overstatement. The MPTT literature contains only limited Mohs experience, mostly in case reports and highly selected lesions. Osto et al. identified a small Mohs-treated subgroup without documented local recurrence, but the numbers were too limited and the reporting too heterogeneous to support a definitive superiority claim [19]. The strongest comparative data come instead from TC. Sun et al. analyzed 231 TC cases and confirmed that the head and neck region predominates, that recurrence and metastasis can occur, and that careful margin control remains central to treatment assessment [25]. Shahinfar et al. more specifically reported recurrence rates of 10.1% after wide local excision versus 4.8% after Mohs in a series of 100 TC patients [10]. These TC data provide a plausible technical rationale for margin-controlled excision in follicular outer root sheath malignancies, but they should remain contextual in an MPTT paper. On the basis of currently available evidence, Mohs can be presented as a reasonable option in selected MPTT cases, particularly recurrent tumors, anatomically constrained scalp lesions, or margin-threatened defects, but not as a universally established standard.

The available evidence for nodal staging, adjuvant radiotherapy, and systemic treatment remains limited. Osto et al. documented regional nodal disease in 15.4% and distant metastasis in 9.2% of pooled scalp MPTT cases, confirming that metastatic spread is real, although it is not the dominant pattern of presentation [19]. At the same time, metastatic scalp case reports confirm that a biologically aggressive subset does exist, even if such cases appear to represent the exception rather than the rule [26]. Sentinel lymph node biopsy, radiotherapy, and chemotherapy have each been described in isolated reports, generally in advanced, recurrent, or metastatic disease [11, 19, 27]. In the absence of nodal involvement, unresectability, repeated local failure, or overt metastatic spread, complete surgery followed by structured surveillance remains the most defensible strategy. Likewise, routine sentinel node biopsy or routine postoperative radiotherapy cannot be recommended based on current evidence alone.

This study has several limitations. It is retrospective, includes a small number of patients, and has a relatively short mean follow-up for a tumor in which late recurrence is possible. The literature used for contextual comparison is heterogeneous and dominated by case reports and small case series, and selected TC studies were included only to inform discussion of margin control and surgical strategy rather than to define MPTT-specific outcomes. These limitations should temper interpretation, but they do not undermine the main practical message of the present series: MPTT of the scalp behaves primarily as a locally aggressive surgical disease, and durable local control depends above all on complete excision at the deep plane.

5 Conclusion

MPTT of the scalp is uncommon, diagnostically challenging, and primarily a surgical disease. In this series, durable local control was achieved without documented recurrence during follow-up, but adequate deep clearance remained critical because compromised deep margins required re-excision in 2 patients. The histological profile of the tumors in this cohort corresponds to the low-grade malignant category in the classification proposed by Ye et al. [15]. Although no distant metastasis was observed, the tumors demonstrated functional malignancy through invasive growth, elevated proliferative indices, and incomplete deep clearance requiring surgical re-intervention. Wide local excision remains an appropriate treatment strategy, with prompt re-excision when margins are compromised. Mohs micrographic surgery may be particularly useful in recurrent lesions, margin-threatened tumors, or anatomically constrained defects, but supporting evidence should be described as indirect when

it comes from TC rather than MPTT. Careful pathological review, individualized reconstruction, and long-term surveillance are essential.

Author contributions Servet Elçin Alpat: Study conception and design, operative management, data collection and drafting of the manuscript. Elif Akbay: Operative management, data collection and critical revision of the manuscript. Burak Kaya: operative management, data collection and critical revision of the manuscript. Bilge Ayça Kırmızı: Pathological interpretation and preparation of Figure 2. Savaş Serel: Operative management and data collection. All authors reviewed the manuscript.

Funding Open access funding provided by the Scientific and Technological Research Council of Türkiye (TÜBİTAK). The authors did not receive support from any organization for the submitted work. No funding was received to assist with the preparation of this manuscript.

Data availability The datasets analysed may be available from the corresponding author upon reasonable request.

Declarations

Competing interests The authors have no relevant financial or non-financial interests to disclose. The authors have no competing interests to declare that are relevant to the content of this article.

Ethics Approval This study was performed in line with the principles of the Declaration of Helsinki. Approval was granted by the Institutional Review Board of both participating centers (Approval No. 2024/459 and Approval No. 2021/15). All procedures performed in this study involving human participants were in accordance with the ethical standards of the institutional and national research ethics committees.

Consent to Participate and Publish Informed consent was obtained from all individual participants included in the study and was managed in accordance with institutional requirements for retrospective studies as determined by the respective Institutional Review Boards.

Clinical Trial Number Not Applicable.

Open Access This article is licensed under a Creative Commons Attribution 4.0 International License, which permits use, sharing, adaptation, distribution and reproduction in any medium or format, as long as you give appropriate credit to the original author(s) and the source, provide a link to the Creative Commons licence, and indicate if changes were made. The images or other third party material in this article are included in the article's Creative Commons licence, unless indicated otherwise in a credit line to the material. If material is not included in the article's Creative Commons licence and your intended use is not permitted by statutory regulation or exceeds the permitted use, you will need to obtain permission directly from the copyright holder. To view a copy of this licence, visit http://creativecommons.org/licenses/by/4.0/.

References

1. Chiu CS, Lin CY, Kuo TT, Kuan YZ, Chen MJ, Ho HC, Yang LC, Chen CH, Shih IH, Hong HS, Chuang YH. Malignant cutaneous tumors of the scalp: a study of demographic characteristics and histologic distributions of 398 Taiwanese patients. J Am Acad Dermatol. 2007;56(3):448–52. https://doi.org/10.1016/j.jaad.2006.08.060.
2. Richmond HM, Duvic M, Macfarlane DF. Primary and metastatic malignant tumors of the scalp: an update. Am J Clin Dermatol. 2010;11(4):233–46. https://doi.org/10.2165/11533260-000000000-00000.
3. Sethi S, Singh UR. Proliferating trichilemmal cyst: report of two cases, one benign and the other malignant. J Dermatol. 2002;29(4):214–20. https://doi.org/10.1111/j.1346-8138.2002.tb00252.x.
4. Joshi TP, Marchand S, Tschen J. Malignant Proliferating Trichilemmal Tumor: A Subtle Presentation in an African American Woman and Review of Immunohistochemical Markers for This Rare Condition. Cureus. 2021;13(8):e17289. https://doi.org/10.7759/cureus.17289.
5. Katrancioglu O, Akkas Y, Akkaş EA, Cevit R, Kılıçkap S. Metastasis to Pleura of Malignant Trichilemmal Tumor. Respiratory Case Rep. 2013;2:150–3. https://doi.org/10.5505/RESPIRCASE.2013.81300.
6. Nanjundappa A, Halkud R, Venugopal B, Chavan P, Sidappa KT, Biswas S, Samskruthi M, Naik SM. Squamous Cell Carcinoma of the Scalp Masquerading as Trichilemmal Tumor of the Scalp. Int J Head Neck Surg. 2014;5(3):144–7. https://doi.org/10.5005/jp-journals-10001-1201.
7. Alam K, Gupta K, Maheshwari V, Varshney M, Jain A, Khan AH. A large proliferating trichilemmal cyst masquerading as squamous cell carcinoma. Indian J dermatology. 2015;60(1):104. https://doi.org/10.4103/0019-5154.147854.
8. Fakhoury E, Cruz A, Kuehl G, D'Alessio M. Rare Case of a Malignant Proliferating Trichilemmal Tumor: A Case Report. J Med Cases. 2012;4(3):182–4. https://doi.org/10.4021/jmc1007e.
9. Tierney E, Ochoa MT, Rudkin G, Soriano TT. (2005). Mohs' micrographic surgery of a proliferating trichilemmal tumor in a young black man. Dermatologic surgery: official publication for American Society for Dermatologic Surgery [et al.], 31(3), 359–63. https://doi.org/10.1111/j.1524-4725.2005.31090.
10. Shahinfar S, Shalabi MMK, Nadir U, Malick H, Lauck KC, Mehrmal S, Kelley B, Tolkachjov SN. Trichilemmal carcinoma: surgical outcomes with wide local excision versus Mohs micrographic surgery. Arch Dermatol Res. 2024;316(10):696. https://doi.org/10.1007/s00403-024-03457-4.
11. Sutherland D, Roth K, Yu E. Malignant proliferating trichilemmal tumor treated with radical radiotherapy: A case report and literature review. Cureus. 2017;9(1):e999. https://doi.org/10.7759/cureus.999.
12. Rao S, Ramakrishnan R, Kamakshi D, Chakravarthi S, Sundaram S, Prathiba D. Malignant proliferating trichilemmal tumour presenting early in life: an uncommon feature. J Cutan aesthetic Surg. 2011;4(1):51–5. https://doi.org/10.4103/0974-2077.79196.
13. Gulati HK, Deshmukh SD, Anand M, Morale V, Pande DP, Jadhav SE. Low-grade malignant proliferating pilar tumor simulating a squamous-cell carcinoma in an elderly female: a case report and immunohistochemical study. Int J trichology. 2011;3(2):98–101. https://doi.org/10.4103/0974-7753.90818.
14. Liu X, Li W, Yuan H, Gu W, Chen D. Surgical treatment of rare giant malignant tumors of the scalp: A report of 3 cases with different tumor types. Oncol Lett. 2016;12(5):3411–6. https://doi.org/10.3892/ol.2016.5113.
15. Ye J, Nappi O, Swanson PE, Patterson JW, Wick MR. Proliferating pilar tumors: A clinicopathologic study of 76 cases with a proposal for definition of benign and malignant variants. Am J Clin Pathol. 2004;122(4):566–74. https://doi.org/10.1309/0XLEGFQ64XYJU4G6.
16. Sharma R, Verma P, Yadav P, Sharma S. Proliferating trichilemmal tumor of scalp: Benign or malignant, a dilemma. J Cutan

Aesthetic Surg. 2012;5(3):213–5. https://doi.org/10.4103/0974-2077.101394.
17. Park BS, Yang SG, Cho KH. Malignant proliferating trichilemmal tumor showing distant metastases. Am J Dermatopathol. 1997;19(5):536–9. https://doi.org/10.1097/00000372-199710000-00018.
18. Kearns-Turcotte S, Thériault M, Blouin MM. Malignant proliferating trichilemmal tumors arising in patients with multiple trichilemmal cysts: A case series. JAAD case Rep. 2022;22:42–6. https://doi.org/10.1016/j.jdcr.2022.01.033.
19. Osto M, Parry N, Rehman R, Ahmed U, Mehregan D. Malignant proliferating trichilemmal tumor of the scalp: A systematic review. Am J Dermatopathol. 2021;43(12):851–66. https://doi.org/10.1097/DAD.0000000000001991.
20. Alici O, Keles MK, Kurt A. A rare cutaneous adnexal tumor: Malignant proliferating trichilemmal tumor. Case Rep Med. 2015;2015:742920. https://doi.org/10.1155/2015/742920.
21. Folpe AL, Reisenauer AK, Mentzel T, Rütten A, Solomon AR. Proliferating trichilemmal tumors: clinicopathologic evaluation is a guide to biologic behavior. J Cutan Pathol. 2003;30(8):492–8. https://doi.org/10.1034/j.1600-0560.2003.00041.x.
22. Benslimane Kamal I, Hali F, Marnissi F, Chiheb S. The proliferating and malignant proliferating trichilemmal cyst: An anatomo-clinical study of three cases. Skin appendage disorders. 2022;8(2):161–4. https://doi.org/10.1159/000518354.
23. Chaichamnan K, Satayasoontorn K, Puttanupaab S, Attainsee A. Malignant proliferating trichilemmal tumors with CD34 expression. J Med Association Thail = Chotmaihet thangphaet. 2010;93(Suppl 6):S28–34.
24. Al-Aswad F, Al-Hassani F, Fernandez-Diaz OF, Al Naser M. Management of immobile scalp skin tumors and analysis of skin graft survival on burred calvaria. Plastic and reconstructive surgery. Global open. 2024;12(4):e5757. https://doi.org/10.1097/GOX.0000000000005757.
25. Sun J, Zhang L, Xiao M, Li S, Chen R, Li Y, Yang Y. Systematic analysis and case series of the diagnosis and management of trichilemmal carcinoma. Front Oncol. 2023;12:1078272. https://doi.org/10.3389/fonc.2022.1078272.
26. Bae SB, Lee KK, Kim JS, Lee JH, Lee NS, Lee GT, Park SK, Won JH, Baick SH, Hong DS, Lee DW, Park HS. A case of malignant proliferating trichilemmoma of the scalp with multiple metastases. Korean J Intern Med. 2001;16(1):40–3. https://doi.org/10.3904/kjim.2001.16.1.40.
27. Cecchi R, Rapicano V, De Gaudio C. Malignant proliferating trichilemmal tumour of the scalp managed with micrographic surgery and sentinel lymph node biopsy. J Eur Acad Dermatology Venereology: JEADV. 2008;22(10):1258–9. https://doi.org/10.1111/j.1468-3083.2008.02611.x.

Publisher's Note Springer Nature remains neutral with regard to jurisdictional claims in published maps and institutional affiliations.