BMC Cancer

RESEARCH

Open Access

Real-world treatment patterns and survival outcomes in metastatic head and neck adenoid cystic carcinoma

Hatice Bölek[1], Mehmet Kayaalp[1], Taha Koray Şahin[2], Osman Talha Doğan[3], Seher Yüksel[4], Sumerya Duru Birgi[5], Ibrahim Halil Gullu[2], Mustafa Kürşat Gökcan[6], Sercan Aksoy[2] and Hatime Arzu Yaşar[1*]

Abstract

Purpose There is no standard-of-care systemic therapy for metastatic adenoid cystic carcinoma (ACC), and its management remains challenging. This study aimed to evaluate treatment patterns and disease outcomes in patients with metastatic head and neck ACC.

Methods We conducted a retrospective analysis of patients diagnosed with metastatic head and neck ACC between January 2005 and December 2023.

Results A total of 51 patients were included in the study, of whom 36 (70.6%) received at least one line of systemic treatment. The median overall survival (OS) for the entire cohort was 29.21 months. Patients with lung metastases had significantly longer OS compared to those without (44.52 vs. 11.04 months, $p=0.008$). The median OS for patients who received at least one line of systemic treatment was 26.78 months. The median progression-free survival (PFS) was 7.82 months, 6.11 months, and 4.53 months for first-, second-, and third-line treatments, respectively. Disease progression was the primary reason for treatment discontinuation across all therapy lines.

Conclusion There is no consensus on the optimal treatment approach for metastatic ACC, and therapeutic strategies remain heterogeneous. Patients with lung metastases had better survival outcomes than those with metastases at other sites.

Keywords Adenoid cystic carcinoma, Head and neck cancer, Prognostic factors

Introduction

Adenoid cystic carcinoma (ACC) is a malignant tumor arising from the epithelium of exocrine glands and accounts for less than 1% of all head and neck malignancies and approximately 10–15% of all salivary gland neoplasms [1, 2]. Although treatment modalities vary depending on the tumor stage, surgery followed by postoperative radiation is the most employed approach for localized disease. Treatment failure is high, and even after achieving locoregional control, patients with ACC may experience late recurrences and develop distant metastases long after their initial treatment [3]. The lungs

*Correspondence:
Hatime Arzu Yaşar
arzuyasar@gmail.com
[1]Department of Medical Oncology, Ankara University Faculty of Medicine, Ankara, Turkey
[2]Department of Medical Oncology, Hacettepe University Faculty of Medicine, Ankara, Turkey
[3]Department of Internal Medicine, Hacettepe University Faculty of Medicine, Ankara, Turkey
[4]Department of Pathology, Ankara University Faculty of Medicine, Ankara, Turkey
[5]Department of Radiation Oncology, Ankara University Faculty of Medicine, Ankara, Turkey
[6]Department of Otorhinolaryngology, Ankara University Faculty of Medicine, Ankara, Turkey

© The Author(s) 2025. **Open Access** This article is licensed under a Creative Commons Attribution-NonCommercial-NoDerivatives 4.0 International License, which permits any non-commercial use, sharing, distribution and reproduction in any medium or format, as long as you give appropriate credit to the original author(s) and the source, provide a link to the Creative Commons licence, and indicate if you modified the licensed material. You do not have permission under this licence to share adapted material derived from this article or parts of it. The images or other third party material in this article are included in the article's Creative Commons licence, unless indicated otherwise in a credit line to the material. If material is not included in the article's Creative Commons licence and your intended use is not permitted by statutory regulation or exceeds the permitted use, you will need to obtain permission directly from the copyright holder. To view a copy of this licence, visit http://creativecommons.org/licenses/by-nc-nd/4.0/.

are the most frequent site of metastasis, followed by the bone, lymph nodes, and liver [4–6]. Even with metastatic disease, patients with ACC typically exhibit a prolonged natural history and long-term survival.

Currently, there is no standard-of-care systemic therapy or guideline recommendations for treating metastatic ACC, and managing metastatic ACC remains challenging. Platinum-based regimens are the most frequently selected treatment for metastatic ACC; however, response rates remain low. Anti-vascular endothelial growth factor (anti-VEGF) tyrosine kinase inhibitors (TKIs), including sunitinib, sorafenib, dovitinib, lenvatinib, and axitinib, have not shown a substantial improvement in metastatic disease outcomes [7–11]. Adding avelumab, a programmed death ligand-1 (PD-L1) inhibitor, to axitinib demonstrated only modest activity, with an objective response rate of 18% and a median progression-free survival (PFS) of 7.3 months [12]. Watchful waiting remains an option for asymptomatic patients with metastatic ACC who have a low tumor burden due to the low response rates and indolent course of the disease. Due to the rarity and slow progression of this tumor, prospective observation of patients is challenging. In this study, we aim to evaluate disease outcomes and patterns of systemic treatment use in patients with metastatic head and neck ACC.

Method

We conducted a retrospective cohort study involving patients diagnosed with metastatic head and neck ACC, who were treated and followed up at two tertiary Hospitals in Ankara, Turkey, between January 2005 and December 2023. The study included patients who Had a diagnosis of ACC of the head and neck, were older than 18 years of age, and had distant metastasis. Patients without metastatic disease, as well as those with extensive locoregional disease without distant metastasis who received palliative systemic therapy due to inoperability, were not included in the analysis. Additionally, patients with missing data for survival analysis were excluded.

We extracted demographic information (e.g., age, gender), performance status, date of metastatic disease, treatment date of the last follow-up, and mortality status. The primary objective of the study was to evaluate overall survival (OS) in the entire study population. Secondary objectives were OS and PFS among patients who received systemic therapy for metastatic disease. OS-1 was defined as the time from the date of metastatic disease to the date of death. OS-2 was defined as the time from the beginning date of first-line systemic treatment to the date of death for patients who received at least one line of the systemic treatment. PFS was defined as the time from the beginning date of the treatment to the date of radiologic progression or death.

All statistical analyses were conducted using IBM SPSS Statistics version 24.0 for Mac (IBM Corp., Armonk, NY). Continuous variables were expressed as medians with Q1-Q3, while categorical variables were presented as percentages. Survival outcomes were estimated using the Kaplan–Meier method. All p-values were two-sided, with statistical significance defined as $p < 0.05$.

Results

A total of 51 patients with metastatic head and neck ACC were included in the study. The median age was 50.18 years (Q1: 40.3, Q3: 57.8). Among the patients, 26 (51%) were female, and 31 (62%) had an Eastern Cooperative Oncology Group (ECOG) performance status of 0. Only 4 (7.8%) patients Had metastatic disease at diagnosis. Regarding primary tumor sites, 15 (29.4%) originated from the major salivary glands, 13 (25.5%) from the oral cavity and hypopharynx, and 7 (13.7%) from the nasal sinuses. Other tumor locations are detailed in Table 1. A total of 45 patients (88.2%) underwent surgical resection of the primary lesion, and 43 of them received adjuvant therapy. The most common metastatic site was the lung (78.4%), followed by lymph nodes (35.3%) and bone metastases (23.5%).

The median OS-1 was 29.21 months (95% CI: 3.52–54.89) (Fig. 1A). The median OS-1 was 44.52 months (95% CI: 25.50–63.53) in patients with lung metastasis, which was significantly longer compared to those without lung metastasis ($p = 0.008$) (Fig. 1B). The median OS was 51.55 months (95% CI: 33.66–69.43) for patients with lung-only metastasis, 29.21 months (95% CI: 14.72–43.69) for those with lung plus other metastatic site(s), and 11.04 months (95% CI: 2.72–19.36) for patients without lung metastasis ($p = 0.019$) (Supplementary Fig. 1). The median OS-1 was 20.50 months (95% CI: 11.35–29.64) for patients with lymph node metastasis and 44.39 months (95% CI: 21.19–67.57) for those without lymph node metastasis ($p = 0.102$) (Fig. 1C). The median OS-1 was 19.15 months (95% CI: 6.03–32.28) in patients with bone metastasis and 44.38 months (95% CI: 19.81–68.96) in those without bone metastasis ($p = 0.071$) (Fig. 1D).

Among the patients, 36 (70.6%) received at least one line of systemic treatment, and 4 (7.8%) underwent a metastasectomy. The characteristics of patients who received systemic treatment are presented in Table 1. The most utilized protocols were the cyclophosphamide, adriamycin, and cisplatin (CAP) regimen (7 patients), etoposide monotherapy (5 patients), and cisplatin plus 5-fluorouracil (4 patients) combination. Details of systemic treatments are provided in Table 2. The median OS of patients who received systemic treatment (OS-2) was 26.78 months (95% CI: 3.48–50.07). For patients who did not undergo systemic therapy or metastasectomy,

Table 1 Baseline characteristics of the patients

Variable		All (*N* = 51)	Receiving systemic treatment (*N* = 36)
Age (median, Q1-Q3), years		50.18 (40.3–57.8)	47.61 (38.1–53.6)
Gender	Male	25 (49)	18 (50)
	Female	26 (51)	18 (50)
Performance status	1	31 (60.8)	24 (66.7)
	2	17 (33.3)	10 (27.8)
	3	2 (9)	1 (2.8)
Metastatic disease at diagnosis		4 (7.8)	2 (5.6)
Time to metastatic disease (median, Q1-Q3), years		2.1 (0.8–7.7)	1.98 (0.8–8.4)
Histologic subtype	Tubular	1 (2)	1(2.8)
	Cribriform	11 (21.6)	7 (19.4)
	Solid	3 (5.9)	3 (8.4)
	Mixed	8 (15.7)	3 (8.4)
	Unknown	28 (54.9)	22 (61.1)
Primary tumor location	Parotid	5 (9.8)	4 (11.1)
	Submandibular-sublingual gland	10 (19.6)	6 (16.7)
	Oral cavity-hypopharynx	13 (25.5)	8 (22.2)
	Nasopharynx	6 (11.8)	5 (13.9)
	Nasal sinuses	5 (9.8)	4 (11.2)
	Maxilla	7 (13.7)	6 (16.7)
	Mandibula	3 (5.9)	2 (5.6)
	Orbital	1 (2)	0
	Larynx	1 (2)	1 (2.8)
Surgery of primary lesion		45 (88.2)	31 (86.1)
Adjuvant treatment		43 (84.3)	31 (86.1)
Adjuvant radiotherapy		27 (62.8)	21 (67.7)
Adjuvant chemotherapy		1 (2.3)	0
Adjuvant chemoradiotherapy		15 (34.9)	10 (32.3)
Lymph node metastasis		18 (35.3)	16 (44.4)
Lung metastasis		40 (78.4)	31 (86.1)
Liver metastasis		6 (11.8)	5 (13.9)
Bone metastasis		12 (23.5)	9 (25)

the median overall survival was 22.93 months (95% CI: 2.76–43.10). The median PFS of first-line treatment was 5.53 months (95% CI: 2.19–8.85). The median PFS was 4.14 months (95% CI: 2.76–5.51) in patients who received monotherapy and 7.82 months (95% CI: 1.20–19.14) in those who received combination chemotherapy ($p = 0.532$). The reasons for the discontinuation of first-line treatment were disease progression in 28 patients, death in 5 patients, and completion of treatment in 2 patients.

Twenty-four patients received second-line treatment. The most used agents for second-line therapy were single-agent taxanes (7 patients) and TKIs (3 patients received axitinib, 1 lenvatinib, and 1 sunitinib) (Table 2). The median PFS for second-line treatment was 6.11 months (95% CI: 1.97–10.25). The reasons for discontinuation of second-line treatment were disease progression in 15 patients, death in 1 patient, completion of treatment in 3 patients, worsening performance status in 1 patient, and toxicity in 2 patients. Fourteen patients received third-line treatment. TKIs were the most used agents (6 patients received axitinib and 2 sunitinib) (Table 2). The median PFS for third-line treatment was 4.53 months (95% CI: 2.52–6.54). The reasons for discontinuation of third-line treatment were progression in 8 patients, death in 3 patients, completion of treatment in 1 patient, and worsening performance status in 1 patient.

Discussion

There is no consensus on the optimal treatment regimen for patients with metastatic head and neck ACC. Despite including two academic centers in this study, a wide variety of treatment regimens were used even in first-line therapy. Further research and collaborative efforts are required to develop and establish standardized treatment protocols. The median OS for metastatic disease was 29.21 months for the entire cohort, while it was 26.78 months in patients who received systemic treatment. This difference may be attributed to baseline

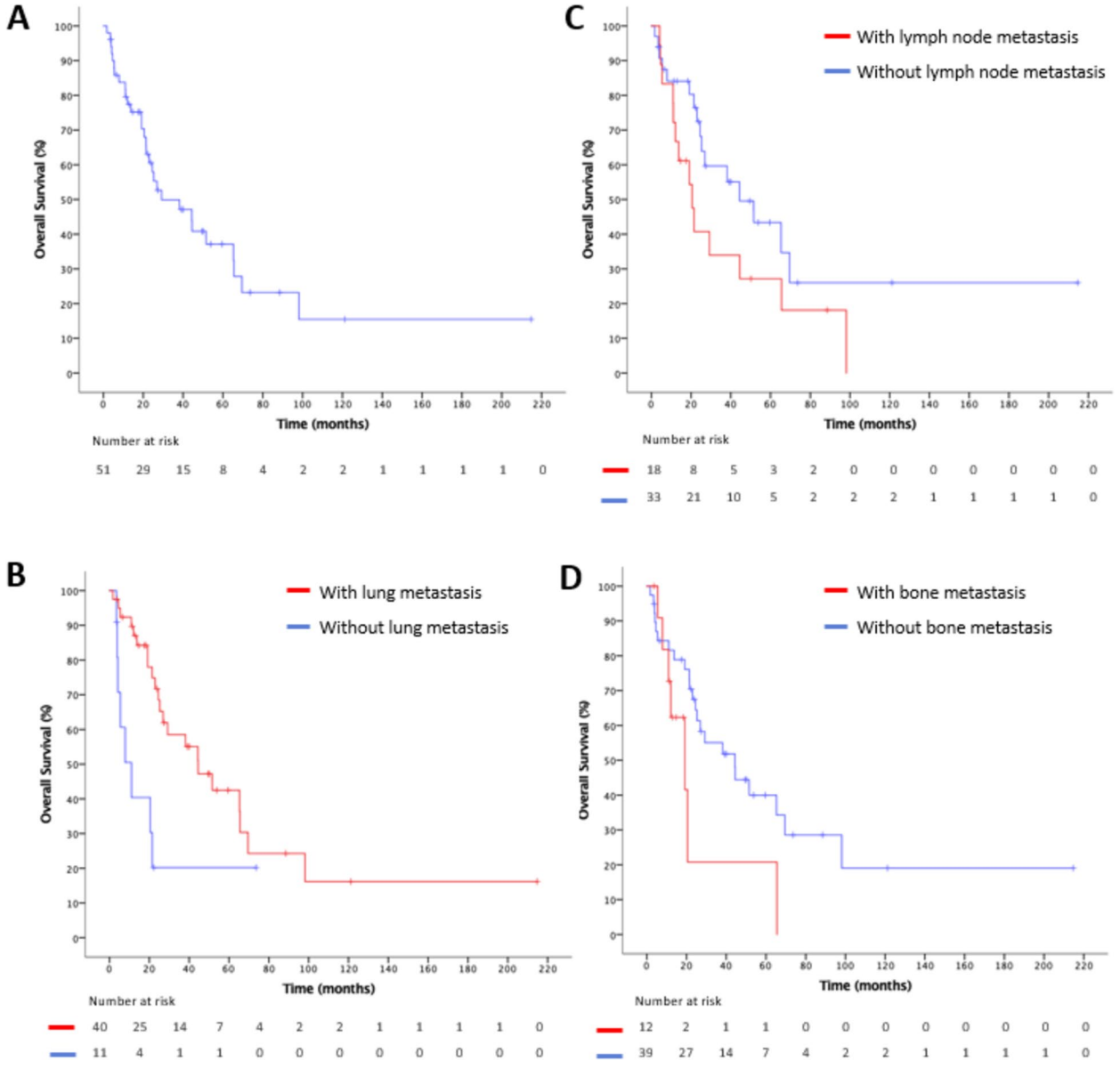

Fig. 1 Kaplan–Meier curves for overall survival in the entire population (**A**) and categorized by the presence of lung (**B**), lymph node (**C**), and bone (**D**) metastases

imbalances, as patients selected for systemic therapy often present with more symptomatic disease, greater tumor burden are not candidates for metastasectomy. Furthermore, adenoid cystic carcinoma is typically an indolent malignancy, and currently available systemic treatments have demonstrated limited efficacy with low objective response rates. These factors, combined with the retrospective design, underscore the need for cautious interpretation of the results.

In our cohort, platinum-based combination therapies were the most frequently used regimen in first-line treatment (21/36, 58.3%), while single-agent taxanes were the most frequently used in second-line treatment (7/24, 29.2%) and TKIs in third-line treatment (8/14, 57.1%). Median OS with first line treatment was 26.78 months. The median PFS was 5.53, 6.11, and 4.53 months for the first, second and third lines of the treatment, respectively. Disease progression was the primary reason for treatment discontinuation across all three lines of therapy. The PFS and OS values in our study are consistent with those reported in previous chemotherapy studies. CAP is the most studied combination therapy, but the studies included a small number of patients [13–15]. A small retrospective study showed that the CAP regimen resulted in a partial response in 2 out of 14 patients, while 10 out of 14 patients Had stable disease. The median PFS was

Table 2 Patterns of systemic treatment

First line (*N* = 36)	
Cyclophosphamide, adriamycin, cisplatin	7 (19.5)
Cisplatin, epirubicin, capecitabine	1 (2.8)
Docetaxel, cisplatin, 5-fluorouracil	2 (5.5)
Cisplatin, 5-fluorouracil	4 (11.1)
Cisplatin, vinorelbine	1 (2.8)
Cisplatin, capecitabine	1 (2.8)
Cisplatin, adriamycin	1 (2.8)
Carboplatin, paclitaxel	3 (8.3)
Carboplatin, gemcitabine	1 (2.8)
Cyclophosphamide, etoposide	1 (2.8)
Cyclophosphamide, methotrexate	1 (2.8)
Single agent taxane	2 (5.5)
Cyclophosphamide	2 (5.5)
Etoposide	5 (13.9)
Adriamycin	1 (2.8)
Sunitinib	1 (2.8)
Axitinib	2 (5.5)
Second line (*N* = 24)	
Cyclophosphamide, adriamycin, cisplatin	2 (8.3)
Docetaxel, cisplatin, 5-fluorouracil	1 (4.2)
Carboplatin, paclitaxel	2 (8.3)
Cisplatin, docetaxel	1 (4.2)
Cisplatin, gemcitabine	1 (4.2)
Gemcitabine, vinorelbine	1 (4.2)
Cyclophosphamide, adriamycin	1 (4.2)
Cyclophosphamide, etoposide	1 (4.2)
Cyclophosphamide	1 (4.2)
Single agent taxane	7 (29.2)
Everolimus	1 (4.2)
Axitinib	3 (12.5)
Lenvatinib	1 (4.2)
Sunitinib	1 (4.2)
Third line (*N* = 14)	
Cyclophosphamide, adriamycin, cisplatin	1 (7.1)
Cisplatin, gemcitabine	1 (7.1)
Carboplatin, paclitaxel	1 (7.1)
Cyclophosphamide, adriamycin	1 (7.1)
Cisplatin	1 (7.1)
Gemcitabine	1 (7.1)
Axitinib	6 (42.8)
Sunitinib	2 (14.3)

5.7 months, and the median OS was 23.4 months [14]. A Phase II trial investigating the efficacy of a cisplatin plus vinorelbine combination in metastatic salivary gland tumors reported an objective response rate (ORR) of 31.6% in the ACC subgroup, with a median PFS of 6.3 months for the entire cohort [16]. The combination of various cytotoxic drugs, including gemcitabine, paclitaxel, 5-fluorouracil (5-FU), epirubicin, and adriamycin, with platinum-based agents has been reported to exhibit variable clinical activity [16–19]

In patients with metastatic ACC, anti-VEGF TKIs serve as an alternative treatment option besides chemotherapy. The phase II trial of sorafenib included patients, nearly Half of whom Had received prior systemic treatment. The ORR was 11%, while the median PFS and median OS were 11.3 and 19.6 months, respectively. Two phase II trials investigated the efficacy of axitinib in patients with recurrent or metastatic ACC. The first trial, which included patients who experienced disease progression within 6 months, reported an ORR of 9.1% and a median PFS of 5.7 months [8]. The second phase II trial enrolled patients whose cancer Had progressed within the past 9 months. In this study, the ORR was 0.0%, but the disease control rate was 100%, with a median PFS of 10.8 months [20]. A Phase II trial of lenvatinib, which included patients who experienced disease progression within 6 months, reported an ORR of 15.6% and a median PFS of 17.2 months [7]. This PFS outcome is the best reported among all anti-VEGF TKI studies in metastatic ACC.

In our cohort, better OS was observed in patients with lung metastases compared to those without lung metastases (44.52 vs. 11.04 months, $p = 0.008$), while median OS was 29.21 months for the entire population. A retrospective study including 145 patients with distant metastatic ACC showed that patients with lung-only metastases had longer OS compared to those with other distant metastases (44 vs. 8 months) [4]. Sung et al. reported that the 2-year survival rate was 74% for patients with lung metastases (median OS: 54 months) and 38% for those with bone metastases (median OS: 20 months) [21]. A relatively large study including 298 patients with metastatic ACC showed that lung metastases were associated with better OS, whereas liver and bone metastases were associated with shorter survival [22]. These data indicate that patients with lung metastases have a more favorable prognosis compared to those with metastases at other sites. However, it is important to note that the observed survival benefit in patients with lung-only metastases may not solely reflect tumor biology. It could also be influenced by lead-time bias or selection bias, as these patients may be more frequently monitored, diagnosed earlier, or deemed better candidates for active surveillance. Distinguishing whether the observed stable disease and survival rates are a result of the drug's effects or merely a reflection of the delayed natural progression of ACC is one of the key challenges in evaluating the efficacy of the therapies for metastatic ACC. Developing biomarkers to identify patients who may benefit from treatment and determining prognostic factors are important for optimizing treatment strategies. Although efforts have been made in this area, the rarity and natural history of the disease have contributed to the lack of definitive evidence for patients with metastatic ACC [7, 8, 23].

Given the modest efficacy of existing treatments for metastatic ACC, there is a pressing need for more effective therapeutic options. Several trials are now underway to evaluate the effects of different medications. There are ongoing trials evaluating the effects of stereotactic body radiotherapy for the early treatment of oligometastatic ACC (NCT04883671), the efficacy of epidermal growth factor receptor tyrosine kinase inhibitors (NCT04974866), mRNA degrader REM-422 (NCT06118086), lenvatinib and pembrolizumab combination therapy (NCT04209660), and 177Lu-PNT2002 (NCT06322576) in metastatic ACC.

Our study has several limitations that should be acknowledged. First, its retrospective design is subject to inherent biases, including selection bias and missing data, which may have influenced the outcomes. Second, the small sample size limited our ability to conduct additional analyses for prognostic factors and multivariate analysis to eliminate potential confounding factors. Third, despite including only two centers, treatment approaches were heterogeneous, which prevents us from providing consistent survival outcomes and assessing radiologic response rates specific to particular therapies, due to variability in imaging follow-up intervals and treatment protocols. Lastly, due to the retrospective nature of our study and the inclusion of patients treated over an extended time span, we were unable to report toxicity data.

In conclusion, there is no consensus on the treatment of metastatic ACC, and therapeutic approaches remain heterogeneous, largely depending on the physician's preference. Disease prognosis can be estimated based on metastatic sites, with patients having lung metastases showing better survival outcomes. There is a need for more clearly defined criteria for initiating treatment and more standardized therapeutic approaches. To achieve this, further studies are required to develop biomarkers that can identify patients who may benefit from treatment and to determine prognostic factors that can guide clinical decision-making.

Supplementary Information

The online version contains supplementary material available at https://doi.org/10.1186/s12885-025-14884-5.

Supplementary Material 1: Supplementary Figure 1: Kaplan-Meier curves for overall survival according to lung metastasis status

Acknowledgements
None.

Authors' contributions
Hatice Bolek: Writing – original draft, Methodology, Investigation, Data curation, Formal analysis, Visualization. Mehmet Kayaalp: Data curation, Writing – review & editing. Taha Koray Şahin: Data curation, Writing – review & editing. Osman Talha Doğan: Data curation, Writing – review & editing. Seher Yüksel: Supervision, Writing – review & editing. Sumerya Duru Birgi: Supervision, Writing – review & editing. Ibrahim Halil Güllü: Supervision, Writing – review & editing. Mustafa Kürsat Gökcan: Supervision, Writing – review & editing. Sercan Aksoy: Supervision, Writing – review & editing. Hatime Arzu Yaşar: Writing – review & editing, Supervision, Project administration, Methodology, Conceptualization.

Funding
None.

Data availability
The data that support the findings of this study are available from the corresponding author upon reasonable request.

Declarations

Ethics approval and consent to participate
This study was approved by Ankara University Faculty of Medicine Ethics Committee (date:10/02/2025, decision number: I01-44–25) and it was carried out in accordance with the Code of Ethics of the World Medical Association also known as a declaration of Helsinki. Due to the retrospective nature of the study the use of anonymized data, no informed consent was required as per the (Ankara University Faculty of Medicine Ethics Committee) approval.

Consent for publication
Not applicable.

Competing interests
The authors declare no competing interests.

Received: 6 May 2025 / Accepted: 18 August 2025
Published online: 30 September 2025

References

1. Ouyang D-Q, Liang L-Z, Zheng G-S, Ke Z-F, Weng D-S, Yang W-F, et al. Risk factors and prognosis for salivary gland adenoid cystic carcinoma in southern China: a 25-year retrospective study. Medicine (Baltimore). 2017;96(5):e5964.
2. Matsuba HM, Spector GJ, Thawley SE, Simpson JR, Mauney M, Pikul FJ. Adenoid cystic salivary gland carcinoma: a histopathologic review of treatment failure patterns. Cancer. 1986;57(3):519–24.
3. Ellington CL, Goodman M, Kono SA, Grist W, Wadsworth T, Chen AY, et al. Adenoid cystic carcinoma of the head and neck: incidence and survival trends based on 1973–2007 surveillance, epidemiology, and end results data. Cancer. 2012;118(18):4444–51.
4. Gao M, Hao Y, Huang M, Ma D, Luo H, Gao Y, et al. Clinicopathological study of distant metastases of salivary adenoid cystic carcinoma. Int J Oral Maxillofac Surg. 2013;42(8):923–8.
5. van Weert S, Bloemena E, van der Waal I, de Bree R, Rietveld DH, Kuik JD, et al. Adenoid cystic carcinoma of the head and neck: a single-center analysis of 105 consecutive cases over a 30-year period. Oral Oncol. 2013;49(8):824–9.
6. Girelli L, Locati L, Galeone C, Scanagatta P, Duranti L, Licitra L, et al. Lung metastasectomy in adenoid cystic cancer: is it worth it? Oral Oncol. 2017;65:114–8.
7. Tchekmedyian V, Sherman EJ, Dunn L, Tran C, Baxi S, Katabi N, et al. Phase II study of lenvatinib in patients with progressive, recurrent or metastatic adenoid cystic carcinoma. J Clin Oncol. 2019;37(18):1529–37.
8. Ho AL, Dunn L, Sherman E, Fury M, Baxi S, Chandramohan R, et al. A phase II study of axitinib (AG-013736) in patients with incurable adenoid cystic carcinoma. Ann Oncol. 2016;27(10):1902–8.
9. Thomson DJ, Silva P, Denton K, Bonington S, Mak SK, Swindell R, et al. Phase II trial of sorafenib in advanced salivary adenoid cystic carcinoma of the head and neck. Head Neck. 2015;37(2):182–7.
10. Chau N, Hotte S, Chen E, Chin S, Turner S, Wang L, et al. A phase II study of sunitinib in recurrent and/or metastatic adenoid cystic carcinoma (ACC) of the salivary glands: current progress and challenges in evaluating molecularly targeted agents in ACC. Ann Oncol. 2012;23(6):1562–70.
11. Keam B, Kim SB, Shin SH, Cho BC, Lee KW, Kim MK, et al. Phase 2 study of dovitinib in patients with metastatic or unresectable adenoid cystic carcinoma. Cancer. 2015;121(15):2612–7.
12. Ferrarotto R, Sousa LG, Feng L, Mott F, Blumenschein G, Altan M, et al. Phase II clinical trial of axitinib and avelumab in patients with recurrent/metastatic adenoid cystic carcinoma. J Clin Oncol. 2023;41(15):2843–51.

13. Dreyfuss AI, Clark JR, Fallon BG, Posner MR, Norris CM Jr, Miller D. Cyclophosphamide, doxorubicin, and cisplatin combination chemotherapy for advanced carcinomas of salivary gland origin. Cancer. 1987;60(12):2869–72.
14. Ha H, Keam B, Ock C-Y, Heo DS. Efficacy of cyclophosphamide, doxorubicin, and cisplatin for adenoid cystic carcinoma, and their relationship with the pre-chemotherapy tumor growth rate. Chin Clin Oncol. 2020;9(2):15.
15. Licitra L, Cavina R, Grandi C, Di Palma S, Guzzo M, Demicheli R, et al. Cisplatin, doxorubicin and cyclophosphamide in advanced salivary gland carcinoma. Ann Oncol. 1996;7(6):640–2.
16. Hong MH, Kim CG, Koh YW, Choi EC, Kim J, Yoon SO, et al. Efficacy and safety of vinorelbine plus cisplatin chemotherapy for patients with recurrent and/or metastatic salivary gland cancer of the head and neck. Head Neck. 2018;40(1):55–62.
17. Kaplan MJ, Johns ME, Cantrell RW. Chemotherapy for salivary gland cancer. Otolaryngol Head Neck Surg. 1986;95(2):165–70.
18. Hill M, Constenla D, A'hern R, Henk J, Rhys-Evans P, Breach N, et al. Cisplatin and 5-fluorouracil for symptom control in advanced salivary adenoid cystic carcinoma. Oral Oncol. 1997;33(4):275–8.
19 Laurie SA, Siu LL, Winquist E, Maksymiuk A, Harnett EL, Walsh W, et al. A phase 2 study of platinum and gemcitabine in patients with advanced salivary gland cancer: a trial of the NCIC Clinical Trials Group. Cancer. 2010;116(2):362–8.
20. Kang EJ, Ahn M-J, Ock C-Y, Lee K-W, Kwon JH, Yang Y, et al. Randomized phase II study of axitinib versus observation in patients with recurred or metastatic adenoid cystic carcinoma. Clin Cancer Res. 2021;27(19):5272–9.
21. Sung M-W, Kim KH, Kim J-W, Min Y-G, Seong W-J, Roh J-L, et al. Clinicopathologic predictors and impact of distant metastasis from adenoid cystic carcinoma of the head and neck. Arch Otolaryngol Head Neck Surg. 2003;129(11):1193–7.
22. Cavalieri S, Mariani L, Vander Poorten V, Van Breda L, Cau MC, Vullo SL, et al. Prognostic nomogram in patients with metastatic adenoid cystic carcinoma of the salivary glands. Eur J Cancer. 2020;136:35–42.
23. Roussel-Simonin C, Riet F, Hervé G, Bertolus C, Maingon P, Spano J-P, et al. Efficacy and prognostic factors of systemic therapies for metastatic adenoid cystic carcinoma. Am Soc Clin Oncol; 2019

Publisher's Note

Springer Nature remains neutral with regard to jurisdictional claims in published maps and institutional affiliations.